



The journal *Cardiovascular and Metabolic Science* and the material contained therein are under the Creative Commons Attribution-NonCommercial-NoDerivatives (CC BY-NC-ND) license.



Keywords:

chronic extrinsic compression, circumflex artery stenosis, mitral valve plasty, annuloplasty ring, intravascular ultrasound.

Palabras clave:

compresión extrínseca crónica, estenosis de la arteria circunfleja, valvuloplastia mitral, anillo de anuloplastia, ecografía intravascular.

* Tecnológico de Monterrey. Escuela de Medicina y Ciencias de la Salud, Instituto de Cardiología y Medicina Vascular, TecSalud. Mexico.

‡ Cardiology fellow.
ORCID: 0000-0002-8458-5653

§ Cardiology fellow.
ORCID: 0000-0003-4271-7512

¶ Cardiology professor.
ORCID: 0009-0005-7804-6652

|| Cardiology professor.
ORCID: 0000-0003-3123-9594

Multimodal approach to assess a circumflex artery extrinsic stenosis after five years of mitral plasty

Evaluación multimodal de la compresión extrínseca de la arteria circunfleja cinco años post-valvuloplastia mitral

José A Salinas-Casanova,^{*,‡} Juan Carlos Ibarrola-Peña,^{*,§} Cecilio Enríquez-Cervantes,^{*,||} Erasmo De la Peña-Almaguer,^{*,||} Carlos Jerjes-Sánchez^{*,**}

ABSTRACT

Introduction: acute complications are common after a Mitral Valve (MV) replacement or annuloplasty. Ischemia induced by stenosis of the Circumflex Artery (CxA) caused by sutures of the MV annuloplasty is the most frequent acute complication. **Presentation of case:** a 69-year-old woman with a successful MV annuloplasty performed five years previously presented with a four-month history of chest tightness on exertion. An exercise stress echocardiogram displayed ischemia and inferolateral wall hypokinesia. A coronary computed tomography angiography revealed extrinsic stenosis at the middle third of the CxA, close to the annuloplasty ring, consistent with coronary angiography findings. The cardiac magnetic resonance demonstrated inferolateral wall hypokinesia and basal inferolateral wall transmural necrosis. We performed a percutaneous coronary intervention with Intravascular Ultrasound (IVUS), showing the stenosis. We performed an angioplasty and stent placement with post-stent IVUS, which showed adequate angiographic apposition. The patient was discharged home two days later with optimal medical therapy. **Conclusion:** chronic stenosis of the CxA after MV annuloplasty is extremely rare, with only four cases reported in the literature. A multimodal approach, including IVUS, can help identify the ischemia mechanism of a CxA chronic occlusion, supporting clinical decision-making to manage this complication.

RESUMEN

Introducción: las complicaciones agudas son frecuentes tras una sustitución o anuloplastia de la Válvula Mitral (VM). La isquemia inducida por la estenosis de la Arteria Circunfleja (ACx) causada por las suturas de la anuloplastia de la VM es la complicación aguda más frecuente. **Presentación del caso:** una mujer de 69 años con anuloplastia de la VM realizada con éxito cinco años previos se presentó con una historia de cuatro meses de dolor precordial opresivo al esfuerzo. Un ecocardiograma de esfuerzo mostró isquemia e hipocinesia de la pared inferolateral. La angiografía coronaria por tomografía computarizada reveló estenosis extrínseca en el tercio medio de la ACx, cerca del anillo de anuloplastia, en consonancia con los hallazgos de la angiografía coronaria. La resonancia magnética cardíaca demostró hipocinesia de la pared inferolateral y necrosis transmural de la pared inferolateral basal. Se realizó intervención coronaria percutánea con Ultrasonido Intravascular (IVUS) que mostró la estenosis. Realizamos angioplastia y colocación de stent con IVUS post-stent que mostró una adecuada aposición. El paciente fue dado de alta dos días después con tratamiento médico óptimo. La estenosis crónica de la ACx tras anuloplastia de la VM es extremadamente rara, con sólo cuatro casos descritos en la literatura. **Conclusión:** un enfoque multimodal, que incluye el uso de IVUS, puede ayudar a identificar el mecanismo de isquemia de una oclusión crónica de la ACx y en la toma de decisiones clínicas para un abordaje apropiado.

Abbreviations:

MV = Mitral Valve

CxA = Circumflex Artery

CARE = Case Reports

CMR = Cardiac Magnetic Resonance

IVUS = Intravascular Ultrasound

INTRODUCTION

The prevalence of mitral regurgitation is continuously increasing, becoming the most common valvular disease in patients over 75 years in the United States. Worldwide,

How to cite: Salinas-Casanova JA, Ibarrola-Peña JC, Enríquez-Cervantes C, De la Peña-Almaguer E, Jerjes-Sánchez C. Multimodal approach to assess a circumflex artery extrinsic stenosis after five years of mitral plasty. *Cardiovasc Metab Sci.* 2025; 36 (3): 161-165. <https://dx.doi.org/10.35366/121370>



** Director of Clinical Research. Academic Director of the Specialty of Cardiology. ORCID: 0000-0003-3222-7405

Received:
12/18/2024
Accepted:
06/10/2025

Mitral Valve (MV) annuloplasty is used to repair mitral regurgitation. Valvular heart disease guidelines recommend annuloplasty with prosthetic rings as the preferable management.¹ Acute complications are a common occurrence after an MV replacement or annuloplasty. Most complications associated with annuloplasty occur during the surgery or 30 days after.² Ischemia induced by stenosis of the Circumflex Artery (CxA) caused by sutures of the MV annuloplasty is the most frequent acute complication. Following the Case Reports (CARE) guidelines,³ we report a

case with myocardial ischemia secondary to a coronary CxA extrinsic stenosis five years after mitral annuloplasty.

We systematically reviewed studies, including at least one case report of chronic CxA extrinsic compression after any MV interventional procedure. The assessment was made through Google Scholar, PubMed, Scopus, Embase, and Medline. We analyzed studies published between 1980 and March 2023, finding few cases of chronic complication after mitral annuloplasty.⁴⁻⁶

CASE PRESENTATION

We evaluated a 69-year-old woman with a four-month history of chest tightness with exertion. The past medical history included hypertension, hypothyroidism, and paroxysmal atrial fibrillation. She also had a successful MV annuloplasty with a 30 mm ring secondary to severe mitral regurgitation five years prior to the current evaluation. The medications included rosuvastatin, losartan, and levothyroxine. Before admission, a 24-hour Holter electrocardiogram showed single monomorphic ventricular extrasystoles, and an exercise stress echocardiogram displayed ischemia and inferolateral wall hypokinesia with normal left ventricular function. The physical examination and laboratory tests were normal.

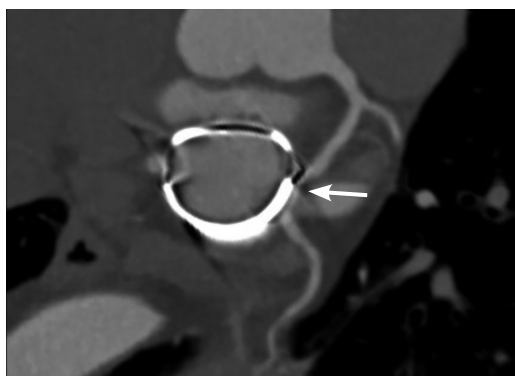


Figure 1: Coronary computed tomography angiography of the Circumflex Artery (CxA). Extrinsic stenosis of 90% at the middle third of the CxA, close to the annuloplasty ring (white arrow).

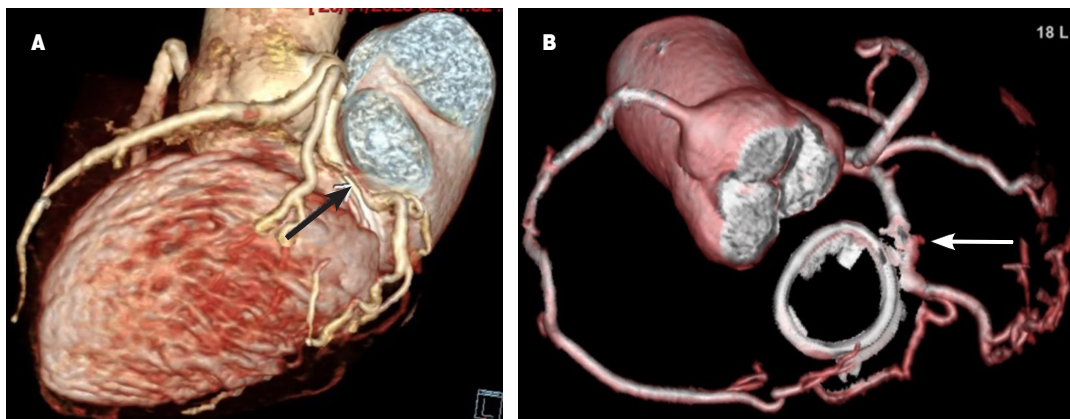


Figure 2: Coronary computed tomography angiography three-dimensional reconstruction. **A)** Stenosis at the middle third of the Circumflex Artery (CxA) with close relation to the annuloplasty ring (white arrow shows the annuloplasty ring). **B)** Three-dimensional reconstruction of the CxA and the annuloplasty ring that shows how the annuloplasty ring compresses the CxA with a significant stenosis (white arrow).

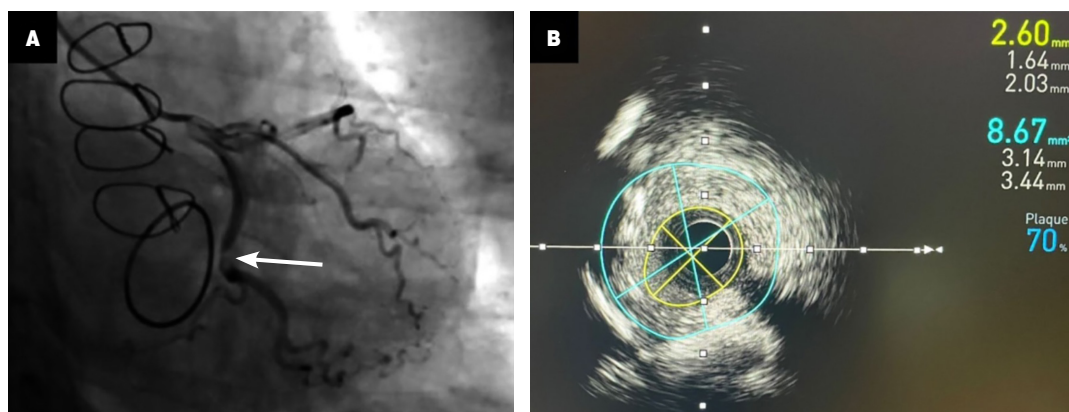


Figure 3: Coronary angiography and intravascular ultrasound. **A)** Coronary angiography with 90% stenosis of the circumflex artery related to the annuloplasty ring (white arrow). **B)** Intravascular ultrasound with a luminal area of the stenosis of 2.6 mm² without plaques.

The electrocardiogram showed a previous left bundle branch block.

Given the results, we performed a coronary computed tomography angiography, revealing a 90% extrinsic stenosis at the middle third of the CxA, close to the annuloplasty ring without coronary atherosclerosis (Figures 1 and 2). Coronary angiography revealed a 90% stenosis of the middle third of the CxA related to the mitral annuloplasty ring (Figure 3) without coronary artery disease. Therefore, we performed an adenosine stress Cardiac Magnetic Resonance (CMR) with late gadolinium enhancement for ischemia and necrosis/fibrosis evaluation to establish revascularization (Figure 4). The CMR demonstrated inferolateral wall hypokinesia and basal inferolateral wall transmural necrosis with reversible ischemia and without fibrosis. Additionally, there was no mitral regurgitation. Consequently, we performed a percutaneous coronary intervention with Intravascular Ultrasound (IVUS) that showed a luminal area at the site of the stenosis of 2.6 mm² without calcified or fibrous plaques (Figure 3 and Video 1 https://www.medigraphic.com/videos/cms/cms253v_1); we decided to use a drug-eluting stent of 3.5 × 16 mm and post-stent IVUS showed adequate apposition and expansion of the stent, with a luminal area of 6.45 mm² (Figure 5 and Video 2 https://www.medigraphic.com/videos/cms/cms253v_2). We performed a complication-free procedure, and the patient was discharged home two days

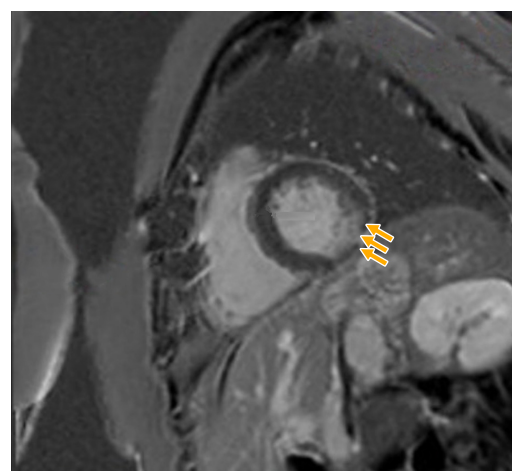


Figure 4: Cardiac magnetic resonance imaging with late gadolinium enhancement. Basal inferior and inferolateral subendocardial late gadolinium enhancement (yellow arrows).

later with optimal medical therapy based on a statin, aspirin, and P2Y2 inhibitor. In addition, we observed normal left ventricular function and no motion abnormalities in a follow-up transthoracic echocardiogram.

DISCUSSION

Chronic stenosis of the CxA after MV annuloplasty is exceptionally uncommon, with only four cases reported in the literature, and according to our understanding, our case

represents the longest-time complication after the initial procedure. Based on the literature review, there is just one case with a greater temporality that differs to our patient because it had an anomalous origin of CxA;⁵ the rest of the cases occurred within the first two years.^{2,4,6}

In this case, the key findings are as follows: first, the case highlights an extrinsic CxA stenosis as an exceptional long-term complication after an MV procedure; CxA occlusion with a suture surrounding or partially occluding the artery remains the primary mechanism in acute cases; several mechanisms, such as retraction of the CxA, distortion of the vasculature in proximity to the suture, compression of the tissue near the mitral annulus in a CxA with anomalous origin, and CxA retraction has been described in chronic cases. Non-invasive imaging technologies, most notably computed tomography angiography, are of critical importance in the diagnosis of external compression, given their ability to reveal the extent of compression and assist in differentiating it from other etiologies of chest pain, such as atherosclerosis or acute coronary syndrome.⁷ Secondly, contrasting with the rest of the literature, where the evaluation before catheterization was limited to an echocardiogram, to establish the decision for revascularization, we performed an ischemia and fibrosis evaluation with a CMR using adenosine and late gadolinium

enhancement. Additionally, we performed a contractile functional assessment with a stress echocardiogram. This case demonstrates the multimodal approach's usefulness in demonstrating ischemia and establishing the diagnosis and clinical decision-making.

All reported cases in the literature were evaluated at the catheterization laboratory, and percutaneous coronary intervention resolved (angioplasty and stent) the chronic extrinsic CxA occlusion.^{2,4,6} Intravascular imaging has proven to be a tool for guiding procedures in complicated and unconventional scenarios, providing information on coronary anatomy and its structural integrity in real-time.^{8,9} In three reported cases, intravascular imaging guided the procedure,⁴⁻⁶ with optical coherence tomography used in only one case.⁴ Intravascular imaging offers significant advantages in the assessment of extrinsic coronary artery compression by providing visualization of the relationship between the coronary artery and adjacent structures. This capability is essential for assessing the severity and extent of the compression, which may otherwise be difficult to identify using traditional angiography alone. It facilitates the selection of the appropriate stent size and optimizes its placement. Furthermore, intravascular imaging is invaluable in the post-intervention assessment phase, as it allows clinicians to evaluate the stent expansion and detect potential complications, such as restenosis or malposition.¹⁰ In our case, the

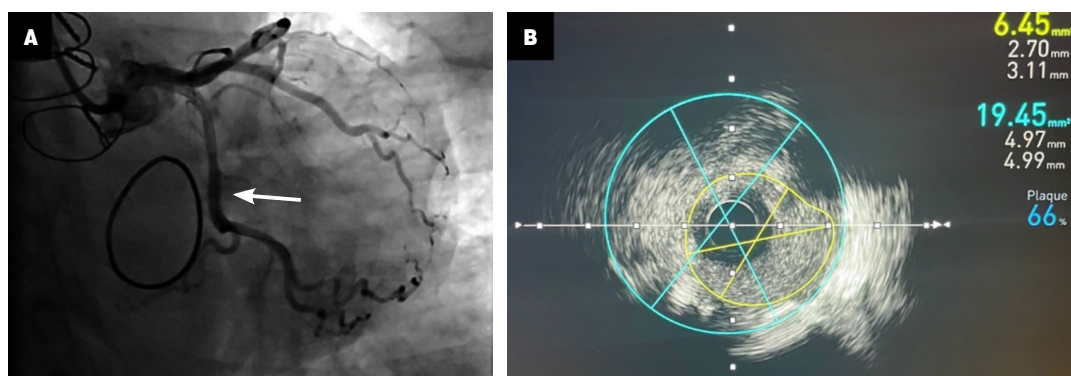


Figure 5: Post-stent implantation imaging. **A)** Coronary angiography showing correct angiographic stent placement with adequate antegrade flow of the circumflex artery (white arrow). **B)** Post-stent intravascular ultrasound with good apposition with a luminal area of 6.45 mm².

IVUS identified an extrinsic vessel compression excluding coronary artery disease and proved effective for endovascular treatment, making it an unusual case among the previous evidence. In our case, we ruled out atherosclerotic disease through IVUS; therefore, distortion and fibrosis near the vasculature secondary to the suture of the mitral annuloplasty was the most probable occlusion mechanism and likely the explanation of why the symptoms and ischemia occurred after five years rather than immediately after surgery.

There is a lack of international valvular disease¹ and myocardial revascularization¹¹ recommendations for interventional decision-making in extrinsic coronary occlusions. Our case highlights an unusual chronic CxA occlusion in which the multimodal imaging approach identified the ischemia mechanism excluding coronary disease and demonstrated a practical endovascular approach. As a take-home message, chronic CxA stenosis after MV replacement or annuloplasty is an entity that needs to be more frequently addressed, and early identification through a multimodal approach is possible through close follow-up after an MV procedure with ischemia detection tests.

CONCLUSIONS

Chronic stenosis of the CxA after MV annuloplasty is extremely rare, and the most common acute complication that induces ischemia is usually secondary to surgical sutures. However, chronic CxA stenosis after MV annuloplasty may be caused by distortion of the vasculature in proximity to the suture, compression of the tissue near the mitral annulus, and CxA retraction due to fibrosis near the coronary artery. A multimodal approach, including intravascular imaging, could identify the ischemia mechanism of a chronic occlusion and help in the clinical decision-making to manage this complication.

REFERENCES

1. Vahanian A, Beyersdorf F, Praz F, Milojevic M, Baldus S, Bauersachs J et al. 2021 ESC/EACTS Guidelines for the management of valvular heart disease. *Eur Heart J*. 2022; 43 (7): 561-632.
2. Hiltrop N, Bennett J, Desmet W. Circumflex coronary artery injury after mitral valve surgery: A report of four cases and comprehensive review of the literature. *Catheter Cardiovasc Interv*. 2017; 89 (1): 78-92.
3. Gagnier JJ, Kienle G, Altman DG, Moher D, Sox H, Riley D; CARE Group. The CARE guidelines: consensus-based clinical case reporting guideline development. *Headache*. 2013; 53 (10): 1541-1547.
4. Busu T, Alqahtani F, Kawsara A, Hijazi M, Alkhouli M. Iatrogenic circumflex artery stenosis following mitral valve repair. *Cureus* 2017; 9 (9): e1680.
5. Dai Q, Song J, He J, Xu B. A rare case of anomalous original left circumflex artery stenosis after artificial mitral valve replacement. *JACC Cardiovasc Interv*. 2017; 10 (7): e71-e73.
6. Wykrzykowska J, Cohen D, Zimetabum P. Mitral annuloplasty causing left circumflex injury and infarction: novel use of intravascular ultrasound to diagnose suture injury. *J Invasive Cardiol*. 2006; 18 (10): 505-508.
7. Batra K, Saboo SS, Kandathil A, Canan A, Hedgire SS, Chamarthy MR et al. Extrinsic compression of coronary and pulmonary vasculature. *Cardiovasc Diagn Ther*. 2021; 11 (5): 1125-1139.
8. Wali E, Nathan S. What is the clinical utility of intravascular ultrasound? *Curr Cardiol Rep*. 2018; 20 (11): 122.
9. Mintz GS, Matsumura M, Ali Z, Maehara A. Clinical utility of intravascular imaging: past, present, and future. *JACC Cardiovasc Imaging*. 2022; 15 (10): 1799-1820.
10. Truesdell AC, Alasnag MA, Kaul P, Rab ST, Riley RF, Young MN et al. Intravascular imaging during percutaneous coronary intervention: JACC state-of-the-art review. *J Am Coll Cardiol*. 2023; 81 (6): 590-605.
11. Neumann FJ, Sousa-Uva M, Ahlsson A, Alfonso F, Banning AP, Benedetto U et al. 2018 ESC/EACTS Guidelines on myocardial revascularization. *Eur Heart J*. 2019; 40 (2): 87-165.

Declaration of patient consent: we obtained the patient's signed informed consent form.

Funding: no financial support was received for this study.

Conflict of interests: the authors declare no conflict of interests.

Correspondence:

Carlos Jerjes-Sánchez

E-mail: carlosjerjes@tec.mx