

ANNALS OF HEPATOLOGY

Volume **1**

Number **2**




April-June **2002**

Article:

Amebic liver abscess open to the inferior vena cava

Copyright © 2002:
Mexican Association of Hepatology

**Otras secciones de
este sitio:**

-  [Índice de este número](#)
-  [Más revistas](#)
-  [Búsqueda](#)

***Others sections in
this web site:***

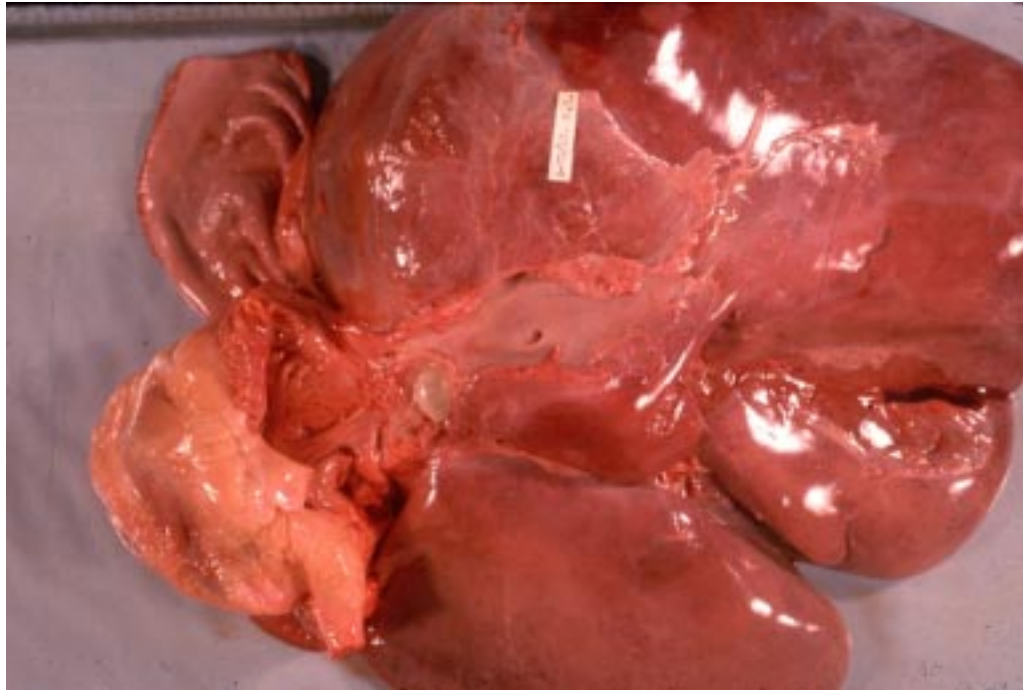
-  [Contents of this number](#)
-  [More journals](#)
-  [Search](#)



medigraphic.com

Images in Hepatology

Amebic liver abscess open to the inferior vena cava



A 56-year-old man. He was fine until one month before admission when he suddenly presented weakness, complaining of right upper quadrant abdominal pain, chills, fever, and jaundice. On admission, the temperature was 35.1°C, the pulse was 42, and the respirations were 12. The blood pressure was 50/20 mmHg. He had a white cell count of $23.5 \times 10^9/L$ with 92% neutrophils. His haematocrit was 36.4%, with a mean corpuscular volume of $86.9 \mu m^3$ and a platelet count of $122/mm^3$, and abnormal liver-function test: protein 4.9 g/dL, albumin 1.7 g/dL, total bilirubin 11.5 mg/dL, conjugated 7.5 mg/dL, Alkaline phosphatase 1,408 U/L, Aspartate aminotransferase 246 U/L, Alanine aminotransferase 339 U/L. The patient died and the emergency room, and the pathological diagnostic was performed.

Luis Guevara-González, M.D. and Nahum Méndez-Sánchez, M.D., Ph.D.
Medica Sur Clinic & Foundation Mexico City 14050 Mexico