



# Coccidioidomycosis and aspergillosis in a patient with pulmonary tuberculosis sequelae

## Coccidioidomicosis y aspergilosis en un paciente con secuelas por tuberculosis pulmonar

Rogelio Flores-Acosta,\* Miroslava Félix-Ponce,\* Alejandra Isabel Jiménez-Gracia,\* Rafael Laniado-Laborín\*<sup>‡</sup>

\*School of Medicine, Autonomous University of Baja California, Mexico, Tuberculosis Clinic, Tijuana General Hospital, Mexico.

<sup>‡</sup>School of Medicine, Autonomous University of Baja California, Mexico, Tuberculosis Clinic, Tijuana General Hospital, Mexico, SNI II, CONACYT.

**ABSTRACT. Introduction:** coccidioidomycosis is exclusive to the American continent, being endemic in the southwestern United States and northwestern Mexico. Aspergillosis is an opportunistic mycosis caused by the saprophytic soil fungus *Aspergillus spp.* The main risk factors that favor the presence of these mycoses are structural lung damage and immunocompromise. **Clinical case:** we present a case of coinfection by *Aspergillus spp.* and *Coccidioides spp.* in a patient with a history of pulmonary tuberculosis and diabetes mellitus. Sputum examination reported the simultaneous isolation of *Coccidioides spp.* and *Aspergillus spp.* **Conclusions:** in patients with respiratory symptoms and a history of tuberculosis and fibrocavitary sequelae, it is essential to rule out initially a tuberculosis relapse, but at the same time, investigate the presence of endemic and opportunistic fungi.

**Keywords:** coccidioidomycosis, aspergillosis, tuberculosis, sequelae.

**RESUMEN. Introducción:** la coccidioidomicosis es una micosis exclusiva del continente americano, siendo endémica en el suroeste de Estados Unidos y noroeste de México. La aspergilosis es una micosis oportunista causada por el hongo saprófito del suelo *Aspergillus spp.* Los principales factores de riesgo que favorecen la presencia de estas micosis son el daño pulmonar estructural y el compromiso inmunológico. **Caso clínico:** se presenta un caso de coinfección por *Aspergillus spp.* y *Coccidioides spp.* en un paciente con antecedentes de tuberculosis pulmonar y diabetes mellitus. El examen de esputo informó el aislamiento simultáneo de *Coccidioides spp.* y *Aspergillus spp.* **Conclusiones:** en pacientes con síntomas respiratorios y antecedente de tuberculosis y secuelas fibrocavitarias es fundamental descartar inicialmente una recidiva tuberculosa, pero al mismo tiempo investigar la presencia de hongos endémicos y oportunistas.

**Palabras clave:** coccidioidomicosis, aspergilosis, tuberculosis, secuela.

## INTRODUCTION

Pulmonary tuberculosis is the most frequent cause of pulmonary cavities<sup>1</sup> and is recognized as a predisposing factor for colonization by *Aspergillus spp.*, a severe and life-threatening complication.<sup>2</sup> However, pulmonary coccidioidomycosis can present similar clinical and radiographic patterns, especially in immunocompromised patients.<sup>3</sup>

This report describes a case of coexistence of *Coccidioides spp.* and *Aspergillus spp.* in a patient with a history of diabetes mellitus and fibrocavitary sequelae from pulmonary tuberculosis, highlighting the relevance of comorbidity due to endemic or opportunistic mycoses in immunocompromised patients.

## CLINICAL CASE

48-year-old Mexican woman, diabetic with poor metabolic control (central glycemia 265 mg/dL); two years earlier, she was diagnosed with pulmonary tuberculosis receiving treatment and discharged as cured.

She developed night sweats, cough, hemoptysis, and weight loss one year later. Her sputum smear microscopies are reported negative for acid-fast bacilli, so she is referred to the Tuberculosis Clinic at the Tijuana General Hospital for tuberculosis molecular and phenotypic diagnostic tests. Smear microscopy, Xpert® MTB/RIF test (Cepheid, Sunnyvale, CA), and cultures (MGIT® BD, Franklin Lakes,

Correspondence:

MSP Rafael Laniado-Laborín

E-mail: rlaniado@uabc.edu.mx

Received: 11-04-2022; accepted: 15-04-2022.

**How to cite:** Flores-Acosta R, Félix-Ponce M, Jiménez-Gracia AI, Laniado-Laborín R. Coccidioidomycosis and aspergillosis in a patient with pulmonary tuberculosis sequelae. Neumol Cir Torax. 2022; 81 (2): 138-140. <https://dx.doi.org/10.35366/108502>

NJ, and Lowenstein Jensen) are reported negative for tuberculosis.

The chest radiograph showed multiple bilateral thin-walled cavities, with an intracavitary mass in several of them. Chest computed tomography (Figure 1A and 1B) confirmed the findings and allowed the identification of a greater number of cavities with an intracavitary mass.

Sputum fungal culture showed the simultaneous isolation of *Coccidioides spp.* and *Aspergillus spp.* (Figure 1C). The hospital unit does not have access to serology tests for these mycoses. She was started with itraconazole 300 mg every 12 hours, showing clinical improvement after a month of treatment.

## DISCUSSION

The search in PubMed, Google Scholar, EMBASE, and the Cochrane Library did not yield reports on the simultaneous presence of *Coccidioides spp.* and *Aspergillus spp.* in patients with fibrocavitary sequelae of tuberculosis.

Residual lung damage even after successful treatment of pulmonary tuberculosis includes fibrocavitary lesions, bronchovascular distortion, emphysema, and bronchiectasis.<sup>4</sup>

The main risk factors that favor disease by these mycoses are a history of structural lung damage and immunocompromise. In our patient, residing in an endemic area of tuberculosis and coccidioidomycosis and being immunocompromised due to diabetes with poor metabolic control,<sup>5</sup> were the predisposing factors that favored the concomitant development of these mycoses.<sup>6-8</sup>

The patient was referred to the tuberculosis clinic, suspecting a tuberculosis relapse. However, based on the negative results of the phenotypic and genotypic tests

for tuberculosis and the presence of multiple cavitations with an intracavitary mass, fungal sputum cultures were requested, suspecting colonization by *Aspergillus spp.*, which was indeed detected, reporting in addition, the unsuspected presence of *Coccidioides spp.*

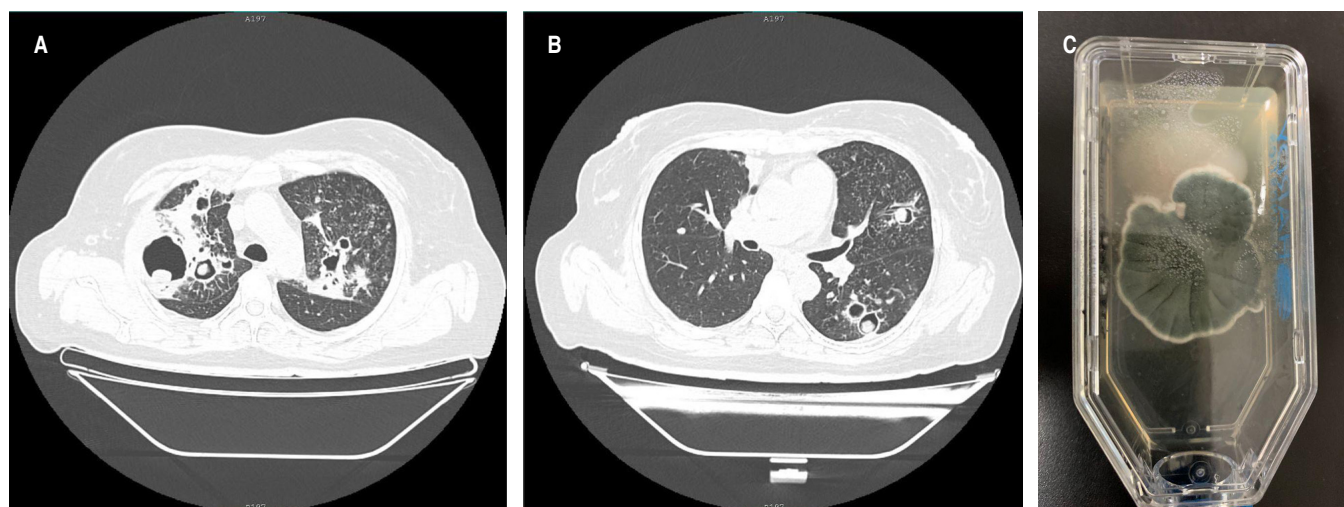
Coccidioidomycosis is exclusive to the American continent, being endemic in the southwestern United States and northwestern Mexico,<sup>9,10</sup> where our patient lives. Aspergillosis is an opportunistic mycosis caused by the saprophytic soil fungus *Aspergillus spp.*, with *Aspergillus fumigatus* the most frequently identified species.<sup>11</sup>

The culture of respiratory samples is the study of choice for the diagnosis of coccidioidomycosis.<sup>9</sup>

Serologic tests identifying anticoccidial humoral antibodies (IgM and IgG) are an alternative method (and the most frequently used) for the diagnosis and prognosis of coccidioidomycosis.<sup>10</sup>

Aspergillosis has different clinical presentations, which frequently overlap. Chronic cavitary aspergillosis (CPA) usually shows multiple cavities that may or may not contain an aspergilloma, in association with pulmonary and systemic symptoms, as well as elevated inflammatory markers. Without treatment, these cavities increase in diameter and coalesce, developing pericavitary infiltrates, which a bronchopleural fistula can complicate.<sup>12</sup>

The diagnosis of CPA requires a combination of different criteria: a consistent appearance on radiological images, direct evidence of *Aspergillus* infection, an immune response to the fungus, and the exclusion of an alternative diagnosis. Patients with CPA are not usually immunosuppressed by HIV infection, chemotherapy, or immunosuppressive therapy.<sup>12</sup> Proven diagnosis of aspergillosis requires histopathological documentation of the infection, or a positive culture result



**Figure 1:** Chest axial tomography and culture. **A)** Multiple cavitations in both upper lobes with intracavitary mass in the right upper lobe lesions. **B)** Left lower lobe cavitation with intracavitary mass. **C)** Culture in Sabouraud medium showing simultaneous growth of *Coccidioides spp.* and *Aspergillus spp.*

from a sample taken from a sterile site.<sup>11</sup> Additionally, the detection of galactomannan (GM) in plasma should support the diagnosis of aspergillosis.<sup>13</sup> In our case, isolation of *Aspergillus* was from a non-sterile sample, and it must be classified as probable aspergillosis infection based on the predisposing factors, suggestive clinical and tomographic data, and mycological evidence.<sup>7,8</sup>

The presence of *Coccidioides* spherules in respiratory samples always represents disease, while the presence of *Aspergillus* can be associated with disease or colonization.<sup>12,14</sup>

## CONCLUSIONS

In patients with tuberculosis sequelae with respiratory symptoms, tuberculosis relapse should be initially ruled out, and opportunistic and endemic fungi such as *Aspergillus spp.* and *Coccidioides spp.* should be considered in the differential diagnosis algorithm.

## REFERENCES

- Nicolás-Sánchez FJ, Merino-Laborda MT, Espinel ML, Canela-Cardona M. De tuberculosis a aspergiloma pulmonar. A propósito de un caso. *An Med Interna*. 2004;21:53-54.
- Bongomin F. Post-tuberculosis chronic pulmonary aspergillosis: an emerging public health concern. *PLoS Pathog*. 2020;16:1-6. doi: 10.1371/journal.ppat.1008742.
- Allwood BW, Byrne A, Meghji J, Rachow A, van der Zalm MM, Schoch OD. Post-tuberculosis lung disease: clinical review of an under-recognised global challenge. *Respiration*. 2021;100(8):751-763. doi: 10.1159/000512531.
- De la Mora IL, Martínez-Oceguera D, Laniado-Laborín R. Chronic airway obstruction after successful treatment of tuberculosis and its impact on quality of life. *Int J Tuberc Lung Dis*. 2015;19(7):808-810. doi: 10.5588/ijtld.14.0983.
- Silva-Hernández A, Barbachano-Rodríguez E, Alanís-Miranda P, González-Martínez M, Portales-Castaneda A. Coexistencia de tuberculosis y coccidioidomicosis en dos pacientes sin síndrome de inmunodeficiencia adquirida. *Rev Med Inst Mex Seguro Soc*. 2010;48:447-452.
- Hernández-Solís A, Camerino-Guerrero A, Colín-Muñoz Y, Bazán-Cuervo S, Cícero-Sabido R, Reding-Bernal A. Micosis pulmonares en pacientes con diabetes mellitus. Características clínicas y factores de riesgo. *Rev Iberoam Micol*. 2020;37:53-57. Available in: <https://doi.org/10.1016/j.riam.2020.04.002>
- Méndez-Tovar LJ, Mejía-Mercado JA, Manzano Gayoso P, Hernández-Hernández F, López-Martínez R, Silva-González I. Frecuencia de micosis invasivas en un hospital mexicano de alta especialidad. Experiencia de 21 años. *Rev Med Inst Mex Seguro Soc*. 2016;54:581-587.
- Fortún J, Meije Y, Fresco G, Moreno S. Aspergillosis. Formas clínicas y tratamiento. *Enferm Infecc Microbio Clin*. 2012;30:201-208. doi: 10.1016/j.eimc.2011.12.005.
- Negroni R, Arechavala A, Maiolo E. Coccidioidomicosis. *Med Cutan Iber Lat Am*. 2010;38:179-188.
- Ampel NM. The diagnosis of coccidioidomycosis. *F1000 Med Rep*. 2010;2:2. doi: 10.3410/M2-2.
- Avilés Robles MJ, Mendoza Camargo FO, Romero Baizabal BL, Serrano Bello CA, Ortega Riosvelasco F. Aspergilosis diseminada por *Aspergillus flavus* en un paciente pediátrico con leucemia linfoblástica aguda de reciente diagnóstico. *Bol Med Hosp Infant Mex*. 2017;74(5):370-381. Available in: <https://doi.org/10.1016/j.bmhmx.2017.05.003>
- Denning DW, Cadranel J, Beigelman-Aubry C, Ader F, Chakrabarti A, Blot S, et al. Chronic pulmonary aspergillosis: rationale and clinical guidelines for diagnosis and management. *Eur Respir J*. 2016;47(1):45-68. doi: 10.1183/13993003.00583-2015.
- Donnelly JP, Chen SC, Kauffman CA, Steinbach WJ, Baddley JW, Verweij PE, et al. Revision and update of the consensus definitions of invasive fungal disease from the European Organization for research and treatment of cancer and the mycoses study group education and research consortium. *Clin Infect Dis*. 2020;71(6):1367-1376. doi: 10.1093/cid/ciz1008.
- Hernandez H, Erives VH, Martinez LR. Coccidioidomycosis: epidemiology, fungal pathogenesis, and therapeutic development. *Curr Trop Med Rep*. 2019;6(3):132-144. doi: 10.1007/s40475-019-00184-z.

**Conflict of interests:** the authors declare that they have no conflict of interests regarding this publication.