



Descending necrotizing mediastinitis. A 16-year experience in a referral center

Mediastinitis necrosante descendente. Experiencia de un centro de referencia durante 16 años

Luis Iván Waldo-Hernández,* José Pablo Rueda-Villalpando,*
Marco Antonio Cruz-López,* Juan Carlos Vázquez-Minero*

*Instituto Nacional de Enfermedades Respiratorias Ismael Cosío Villegas. Mexico City, Mexico.

ABSTRACT. Introduction: descending necrotizing mediastinitis (DNM) refers to mediastinal infections originating in the oropharyngeal and cervicofacial region that spread through the deep planes of the cervical fascia into the mediastinum. Multiple organ failure and high mortality are related to the delay in diagnosis and medical-surgical treatment. Surgical treatment remains controversial, with supports ranging from isolated cervical drainage to cervical drainage and thoracotomy and/or median sternotomy. **Objective:** to know the morbidity and mortality related to the surgical management of NDM as well as the main etiology prevalent in our environment. **Material and methods:** it is a retrospective study in a period between 2006 and 2022 of patients with MND who were hospitalized and surgically treated in the Thoracic Surgery Service of the National Institute of Respiratory Diseases Ismael Cosío Villegas. **Results:** 51 patients were included, 38 men, age 39.19 ± 14.06 years. 41 patients were classified ENDO IIB, 9 ENDO I, the main cause was odontogenic in 28 patients. Days of hospital stay of 22.65 ± 15.61 days. 12 patients operated by cervicotomy and 39 patients combined approach. 22 patients required reintervention. 14 deaths, the most prevalent cause of septic shock. **Conclusions:** the approaches used according to the availability of resources over time and hospital stay and mortality do not differ from what is reported in the literature.

RESUMEN. Introducción: la mediastinitis necrosante descendente se refiere a las infecciones mediastínicas que se originan en la región orofaríngea y cervicofacial que se diseminan a través de los planos profundos de las fascias cervicales hacia el mediastino. La falla orgánica múltiple y la alta mortalidad están relacionadas con el retraso en el diagnóstico y tratamiento médico-quirúrgico. El tratamiento quirúrgico sigue siendo controvertido, con soportes que van desde el drenaje cervical aislado hasta el drenaje cervical y la toracotomía y/o esternotomía media. **Objetivo:** conocer la morbilidad relacionada con el manejo quirúrgico de la mediastinitis necrosante descendente, así como la principal etiología prevalente en nuestro medio. **Material y métodos:** es un estudio retrospectivo en un período comprendido entre 2006 y 2022 de pacientes con mediastinitis necrosante descendente que fueron hospitalizados y tratados quirúrgicamente en el Servicio de Cirugía Torácica del Instituto Nacional de Enfermedades Respiratorias Ismael Cosío Villegas. **Resultados:** se incluyeron 51 pacientes, 38 hombres, edad de 39.19 ± 14.06 años; 41 pacientes se clasificaron como ENDO IIB, nueve ENDO I, la causa principal fue odontogénica en 28 pacientes. Días de estancia hospitalaria de 22.65 ± 15.61 días. Operados por cervicotomía 12 pacientes y abordaje combinado 39 pacientes. 22 pacientes requirieron reintervención quirúrgica. Hubo 14 defunciones, la causa más prevalente fue choque séptico. **Conclusiones:** los resultados no difieren de los reportados en la literatura, en cuanto al tipo de abordaje de acuerdo con la disponibilidad de los recursos con el paso del tiempo, la estancia hospitalaria y mortalidad.

Keywords: mediastinitis, abscess, sternotomy, cervicotomy, thoracoscopy.

Palabras clave: mediastinitis, absceso, esternotomía, cervicotomía, toracosopia.

Correspondence:

Luis Iván Waldo-Hernández, M.D.

Instituto Nacional de Enfermedades Respiratorias Ismael Cosío Villegas.
Mexico City, Mexico.

E-mail: ivanwaldo2303@hotmail.com

Received: XII-02-2022; accepted: I-19-2023.

How to cite: Waldo-Hernández LI, Rueda-Villalpando JP, Cruz-López MA, Vázquez-Minero JC. Descending necrotizing mediastinitis. A 16-year experience in a referral center. Neumol Cir Torax. 2022; 81 (3): 171-176. <https://dx.doi.org/10.35366/111087>

INTRODUCTION

Mediastinitis is a severe infection that affects the connective tissue that fills the mediastinum and surrounds the median thoracic organs;¹ it is a harsh medical condition of infectious origin. Descending necrotizing mediastinitis (DNM) refers to mediastinal infections originating in the oropharyngeal and cervicofacial regions that spread through the deep planes of the cervical fascia into the mediastinum, causing cellulitis, necrosis, abscesses, and sepsis.^{2,3} DNM refers to an infection

that begins in the oropharyngeal or cervical region, then spreads through the fascial planes in the mediastinum and may or may not spread to the pleural cavity.³⁻⁶ Its evolution is rapidly progressive towards tissue necrosis, with high mortality levels (40%) due to sepsis and multiple organ failure without timely and appropriate treatment.⁴ Surgical treatment plays an essential part in this disease's clinical evolution and prognosis. This study aims to determine the postoperative morbidity and mortality in treatment for DNM, as well as the most prevalent approaches and etiologies in our environment.

MATERIAL AND METHODS

This is a retrospective analytical study, conducted in a period from 2006 to 2022, that included all patients diagnosed with DNM treated surgically at the Ismael Cosío Villegas National Institute of Respiratory Diseases (INER) in Mexico City, registered in the database of such procedures of the sub-directorate of surgery. Clinical records were reviewed, including epidemiological data, imaging studies, and available cultures. All patients included were diagnosed based on the criteria of Estrera et al.⁷ The diagnoses were corroborated by computed tomography and were evaluated based on the classification of Endo et al.⁸ Patients were excluded when they presented with mediastinitis due to other causes, such as those secondary to esophageal or tracheal perforation secondary to trauma, post-surgical mediastinitis, or those with a diagnosis other than DNM such as superficial or deep neck abscess. Likewise, patients were excluded when retrieving their complete physical or electronic files was impossible.

RESULTS

A total of 51 patients were included, 13 women (25.49%) and 38 men (74.51%); the mean age was 39.19 ± 14.06 years; 13 of them (25.49%) had some comorbidity, the most prevalent being diabetes mellitus and systemic arterial hypertension; 41 patients (80.39%) were classified by tomography as ENDO IIB, nine (17.64%) as ENDO I and one (1.97%) as ENDO IIA. The leading cause and origin of DNM was odontogenic in 28 patients (54.9%), followed by a peritonsillar abscess in 22 patients (43.13%). The average number of days of hospital stay was 22.65 ± 15.61 days. A total of 12 patients (23.52%) underwent surgery by cervicotomy and 39 those (76.48%) with a combined approach, with cervicotomy + median sternotomy being the most common approach in 21 patients (41.17%), followed by cervicotomy + thoracotomy in 16 patients (31.37%). A total of 22 patients (43.13%) needed some surgical reintervention, the most frequent cause being negative pressure therapy replacement in the 11 patients (21.56%) in which it was

used, with a mean of 10.78 ± 10.01 days of negative pressure therapy. There were 14 deaths (27.45%); the most common cause was septic shock. The isolated pathogens were multimicrobial, the most common being *Klebsiella pneumoniae*, streptococcus, *E. coli*, *Serratia marcescens*, and *Candida*. Post-surgical complications occurred in nine patients (17.64%), pulmonary thromboembolism in two patients (3.92%), acute myocardial infarction, acute renal failure, upper gastrointestinal bleeding, supraventricular tachycardia, sternal osteomyelitis, and right cord palsy in one patient, each (1.96%).

DISCUSSION

DNM is a condition originating in a dental or oropharyngeal infection with a rapidly progressive course that can lead to sepsis and often to death. The cause of DNM is distributed as odontogenic (36-47%), pharyngeal or tonsillar (33-45%), cervical (15%), and other head and neck infections (5%).^{1,4} In our series, the odontogenic origin was the most frequent, with 54.9% of the cases, followed by a peritonsillar abscess.

The most common bacterial flora is an aerobic and anaerobic mix, with β -hemolytic streptococcus being the most commonly isolated.² Cultures in our series were negative in most cases; however, it was possible to isolate *Klebsiella pneumoniae*, *Streptococcus*, *E. coli*, *Serratia marcescens*, and *Candida*, in some cases.

Pearse described the anatomical routes of DNM dissemination in 1983; he was the first to identify this group of patients, which he called «secondary to cervical suppuration».⁵ The dissemination routes from the neck to the mediastinum are through the pretracheal, paraesophageal, prevertebral, and retropharyngeal spaces, and along the carotid sheath. The main space considered «dangerous» is the retropharyngeal space extending from the skull's base to the mediastinum. This entity's infectious, multimicrobial, predominantly anaerobic nature, association with other comorbidities, and negative intrathoracic pressure ease its spread.⁹⁻¹¹

Imaging studies' role is vital in diagnosis, without neglecting a thorough clinical history and physical examination. The main findings in the plain chest x-ray raise the suspicion of DNM and the clinical signs and symptoms of severe infection associated with a history of cervical, dental, or oropharyngeal infection. Said radiological findings can be widening of the mediastinum, pneumomediastinum, mediastinal hydro-aerial levels, anterior displacement of the tracheal air column due to a prevertebral opacity of the soft tissues, enlargement of the cardiac silhouette and loss of the normal lordosis of the cervical spine, as well as unilateral or bilateral pleural effusion.^{9,10,12} Cervicothoracic computed tomography (CT) should be performed immediately, as

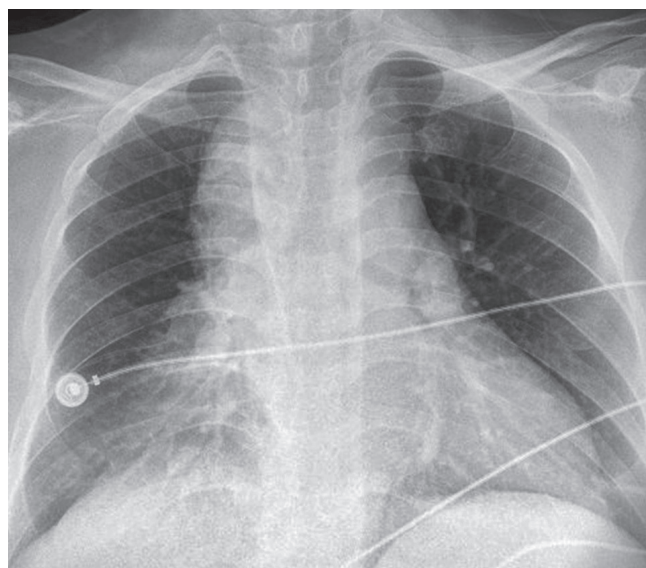


Figure 1: Representative initial chest radiography with mediastinal widening.

CT of the chest and neck can reveal detailed information regarding the extent of the necrosis process and suggests, within the framework of the surgical treatment approach, the best tactic for effective drainage to optimize the best post-surgical outcome for the patient and with it the need for fewer reinterventions.^{9,10,13-17}

In our series, chest radiography continues to be the initial study in all patients with respiratory problems due to its accessibility and quick results (Figure 1); however, chest tomography continues to be the gold standard at our institution for the diagnosis and planning of surgical management in those with mediastinitis (Figure 2).

Management via surgery, and particularly a superior form of mediastinal drainage, is still controversial and ranges from cervical drainage by cervicotomy to a combination of cervical drainage and a thoracic approach using mediastinoscopy, thoracoscopy, thoracotomy, median sternotomy, or a Clamshell incision.^{1,12} At present, mediastinal and cervical drainage have been particularly benefited with the emergence of negative pressure therapy since the need for aggressive reinterventions and the number of days of hospital stay may be reduced. Our series used negative pressure therapy in 11 patients, with a mean of 10.78 ± 10.01 days of use of the treatment with an average of between one and three changes per patient, with a mean hospital stay of 30.50 ± 19.86 days in the patients with the use of negative pressure therapy versus 20.07 ± 13.66 in whom it was not used. In the pairwise analysis, no statistically significant difference was found in hospital stay days with or without negative pressure therapy with $p = 0.132$. It should be noted

that the historical bias must be considered since, prior to 2016, negative pressure therapy was not employed in our institute, as we did not have it. In the same way and added to the limitation of being a retrospective study, an analysis of a larger sample will be necessary, for which it is unnecessary to resort to the paired analysis of the sample. At the same time, it was recorded that the most significant number of reinterventions was in these patients. However, the procedure to be performed was replacing negative pressure therapy, which is not a major surgical procedure. Although it is performed in the operating room at INER, it is a procedure that can be performed safely in the patient's bed. It will be necessary to expand the sample with future cases to decide if a difference is observed in the days of hospital stay in the patients upon whom it is used versus those cases where it is determined not to use it.

Unquestionably, aggressive surgical drainage is essential for successfully managing DNM,³ since broad-spectrum intravenous antimicrobial therapy is fruitless without effective drainage of the cervical region and mediastinal collections.¹ Failure to achieve complete and adequate mediastinal drainage is associated with an increased risk of death.¹⁰

Most authors decline the sole use of cervical drainage. Most agree that this approach does not allow complete visualization of the mediastinum and, therefore, adequate

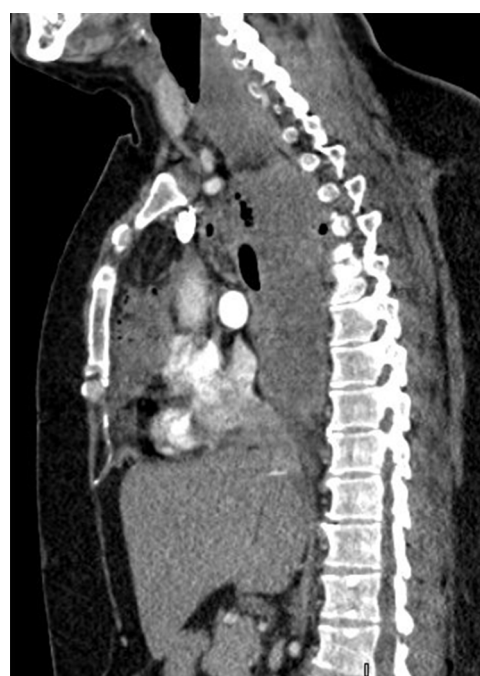


Figure 2: Computed tomography of the chest with intravenous contrast in sagittal section, with data of ENDO IIB mediastinitis, with fluid and gas collections at the cervical level, anterior and posterior mediastinum.

excision of necrotic tissue.³ In 1983, Estrera *et al.* recommended transthoracic drainage for mediastinitis that extends below the fourth thoracic vertebra in the posterior plane since it has been associated with more complications, such as increased pleural empyema.^{1-4,17,18} Wheatley *et al.* recommend the combination of cervical and mediastinal drainage before drainage through the subxiphoid approach, along with tracheostomy to secure the airway, since cervical drainage alone has a 70 to 80% failure rate leading to multiple reoperations, prolonged hospital stays and a mortality of almost 40%.^{1,2,19} Other authors recommend aggressive mediastinal drainage through a standard thoracotomy as the optimal treatment for DNM, regardless of the mediastinal level.^{16,20-22}

In our group of patients, the combined approach was the most used in a total of 39 (76.49%), with cervicotomy combined with median sternotomy being the most used in a total of 21 of them (41.17%), followed by cervicotomy combined with right thoracotomy in 16 patients (31.37%). Median sternotomy also appears to be feasible in DNM type I and IIA but inappropriate in type IIB because access to the posterior and basal compartments of the thoracic cavity is difficult, in addition to being associated with osteomyelitis and sternal dehiscence.^{3,23,24} In our series, one patient (1.97% of the total and 4.76% of the patients who underwent sternotomy) presented osteomyelitis and sternal dehiscence, requiring chest wall reconstruction with pectoral muscle flaps.

Since the beginning of video-assisted surgery in the 1990s and the extension of its use in thoracic surgery, it has been considered a choice in the treatment of DNM. Roberts *et al.* reported a case of thoracoscopic drainage as an alternative for the first time in a patient with mediastinal abscesses secondary to esophageal perforation.²⁵ In 2004, Isowa *et al.* reported successfully managing a patient with DNM via Video Assisted Thoracoscopic Surgery (VATS). In addition, two other groups of authors reported the successful use of VATS in four and nine patients with DNM. Although thoracoscopic drainage has not been wholly described for managing DNM, thoracoscopic exposure allows adequate visualization of the posterior mediastinum with adequate drainage of the collections; likewise, mediastinal collections can be visualized and drained.²⁶⁻²⁹ Mediastinoscopy-assisted drainage can also be helpful in selected cases.²⁹ In our group of patients, only 3.92% underwent minimally invasive surgery, with adequate postoperative results in both groups. It should be noted that each case must be individualized and consider the degree of mediastinitis and the mediastinal compartments involved to select the surgical approach of choice adequately.

After said management, the hospital's average number of postoperative days was 22.65 ± 15.6 . As previously mentioned, there was no statistical difference between

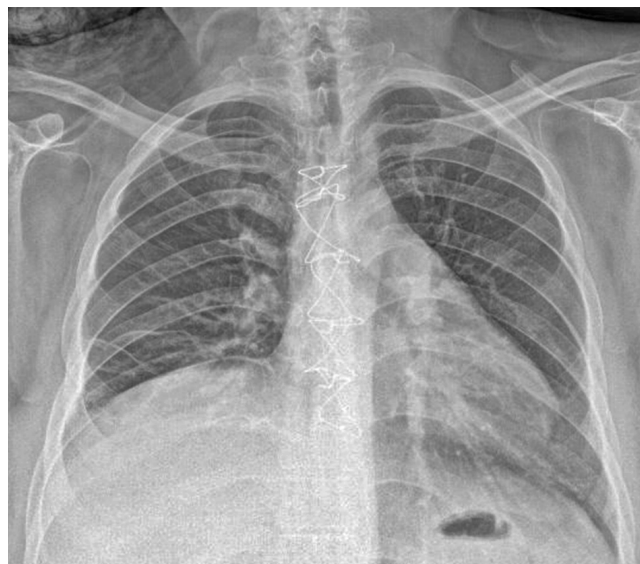

Figure 3: Control X-ray upon discharge of the patient without evidence of pleural effusion, without data of mediastinal widening, with sternal fixation.

the minimally invasive versus open groups and the groups in which negative pressure therapy was or was not used (Figure 3).

Mortality rates remain high, ranging from 12.5 to 37.5% in most recently published series. The leading cause of death is multiple organ failure, for which intensive care unit (ICU) participation is essential. In most published series, long ICU and hospital stays are the rule for patients treated for DNM. The need for a second or even more surgical intervention is also high (33-100%) in most published series, especially after a first attempt to drain the mediastinum through the neck.¹⁰

In our series, postoperative complications occurred in nine patients (17.64%), with pulmonary thromboembolism in two of those (3.92%), acute myocardial infarction, acute renal failure, upper gastrointestinal bleeding, supraventricular tachycardia, sternal osteomyelitis, and right cord palsy in one patient, each (1.96%). In addition, there were 14 deaths (27.45%), the most common cause being a septic shock, coinciding with what has been previously reported in the literature. All deaths were recorded in patients who underwent cervicotomy + open approach (sternotomy or thoracotomy), and no deaths were recorded in patients who underwent thoracoscopy and negative pressure therapy; however, a strict relationship between the medical approach and mortality cannot be considered since we have a historical bias. In agreement with what has already been reported in the literature, mortality is associated with the clinical severity of the patient diagnosed with septic shock.

Since there is no standardized algorithm for the surgical management of DNM, the stage and clinical status of the

patients should be considered to carefully choose the type of surgery to be performed, as well as the surgical approach that allows the best drainage of the mediastinum and pleural cavities considering the possibilities of each hospital center. Thus, taking into account the data from our review and the current management of patients with DNM at INER, we recommend the following points: 1) a multidisciplinary approach in conjunction with pneumology, intensive care, anesthesiology, infectious diseases, and thoracic surgery; 2) timely diagnosis with CT, early introduction of broad-spectrum antibiotics, and early surgical programming; 3) aggressive surgical drainage, cervicotomy in patients with ENDO I mediastinitis and combined approach (cervicotomy + sternotomy or cervicotomy + VATS versus thoracotomy) in those with ENDO IIA and IIB mediastinitis; 4) the type of thoracic approach (sternotomy, thoracotomy, or VATS) should be decided based on the hospital infrastructure and equipment, as well as the surgeon's experience, as long as complete drainage and debridement of all involved mediastinal spaces are guaranteed.

CONCLUSIONS

DNM continues to have impressive morbidity and mortality rates of 30 to 40% or more, almost always attributed to delayed diagnosis and inadequate surgical drainage of the mediastinum. For this reason, DNM needs a multidisciplinary approach based on intensive care unit support, aggressive antibiotic therapy, and said drainage and debridement of the initial infection site and mediastinum, as the prognosis for the disease is poor if proper treatment is not received. The role of surgery is crucial. For a successful result, it is necessary to have extensive knowledge of the cervical and mediastinal anatomy and the routes of the spread of the infection.

The results of our series are similar to those reported in the literature, the approaches described were used according to the availability of resources over time, and both the hospital stay and mortality did not differ from what was reported in the literature.

REFERENCES

- Papalia E, Rena O, Oliaro A, Cavallo A, Giobbe R, Casadio C, *et al.* Descending necrotizing mediastinitis: surgical management. *Eur J Cardiothorac Surg.* 2001;20(4):739-742.
- Kiernan PD, Hernández A, Byrne WD, Bloom R, Diccio B, Hetrick V, *et al.* Descending cervical mediastinitis. *Ann Thorac Surg.* 1998;65(5):1483-1488.
- Chen KC, Chen JS, Kuo SW, Huang PM, Hsu HH, Lee JM, *et al.* Descending necrotizing mediastinitis: a 10-year surgical experience in a single institution. *J Thorac Cardiovasc Surg.* 2008;136(1):191-198.
- Prado-Calleros HM, Jiménez-Fuentes E, Jiménez-Escobar I. Descending necrotizing mediastinitis: Systematic review on its treatment in the last 6 years, 75 years after its description. *Head Neck.* 2016;38 Suppl 1:E2275-E2283.
- Janilionis R, Jagelavicius Z, Petrik P, Kiskis G, Jovaisas V, Kybartas A, *et al.* Diffuse descending necrotizing mediastinitis: surgical treatment and outcomes in a single-centre series. *Acta Médica Lituánica.* 2013;20(3):117-128.
- Akman C, Kantarci F, Cetinkaya S. Imaging in mediastinitis: a systematic review based on aetiology. *Clin Radiol.* 2004;59(7):573-585.
- Estrera AS, Lanay MJ, Grisham JM, Sinn DP, Platt MR. Descending necrotizing mediastinitis. *Surg Gynecol Obstet.* 1983;157(6):545-552.
- Endo S, Murayama F, Hasegawa T, Yamamoto S, Yamaguchi T, Sahara Y, *et al.* Guideline of surgical management based on diffusion of descending necrotizing mediastinitis. *Jpn J Thorac Cardiovasc Surg.* 1999;47(1):14-19.
- Biasotto M, Chiandussi S, Constantinides F, Di Lenarda R. Descending necrotizing mediastinitis of odontogenic origin. *Recent Pat Antiinfect Drug Discov.* 2009;4(2):143-150.
- Foroulis CN, Sileli MN. Descending necrotizing mediastinitis: Review of the literature and controversies in management. *Int J Surg Open.* 2011;5:12-18.
- Ridder GJ, Maier W, Kinzer S, Teszler CB, Boedeker CC, Pfeiffer J. Descending necrotizing mediastinitis: contemporary trends in etiology, diagnosis, management, and outcome. *Ann Surg.* 2010;251(3): 528-534.
- Exarhos DN, Malagari K, Tsatalou EG, Benakis SV, Peppas C, Kotanidou A, *et al.* Acute mediastinitis: spectrum of computed tomography findings. *Eur Radiol.* 2005;15(8):1569-1574.
- Deu-Martín M, Saez-Barba M, López IS, Alcaraz PR, Romero VL, Solé MJ. Mortality risk factors in descending necrotizing mediastinitis. *Arch Bronconeumol.* 2010;46(4):182-187.
- Reynolds SC, Chow WA. Life-threatening infections of the peripharyngeal and deep fascial spaces of the head and neck. *Infect Dis Clin North Am.* 2007;21(2):557-576, viii.
- Kocher GJ, Hokschi B, Caversaccio M, Wiegand J, Schmid RA. Diffuse descending necrotizing mediastinitis: surgical therapy and outcome in a single-centre series. *Eur J Cardiothorac Surg.* 2012;42(4):e66-e72.
- Freeman RK, Vallieres E, Verrier ED, Karmy-Jones R, Wood DE. Descending necrotizing mediastinitis: an analysis of the effects of serial surgical debridement on patient mortality. *J Thorac Cardiovasc Surg.* 2000;119(2):260-267.
- Arza MP, Romolo H, Bunga AS, Ariyanto AS, Wuryantoro, Wardoyo S, *et al.* Descending necrotizing mediastinitis: management and controversies. *Cardiovascular and Thoracic Open.* 2016;2:1-5.
- Wheatley MJ, Stirling MC, Kirsh MM, Gago O, Orringer MB. Descending necrotizing mediastinitis: transcervical drainage is not enough. *Ann Thorac Surg.* 1990;49(5):780-784.
- Marty-Ané CH, Berthet JP, Alric P, Pegis JD, Rouviere P, Mary H. Management of descending necrotizing mediastinitis: an aggressive treatment for an aggressive disease. *Ann Thorac Surg.* 1999;68(1):212-217.
- Corsten MJ, Shamji FM, Odell PF, Frederico JA, Laframboise GG, Reid KR, *et al.* Optimal treatment of descending necrotising mediastinitis. *Thorax.* 1997;52(8):702-708.
- Singhal P, Kejriwal N, Lin Z, Tsutsui R, Ullal R. Optimal surgical management of descending necrotising mediastinitis: our experience and review of literature. *Heart Lung Circ.* 2008;17(2):124-128.

22. Ris HB, Banic A, Furrer M, Caversaccio M, Cerny A, Zbaren P. Descending necrotizing mediastinitis: surgical treatment via clamshell approach. *Ann Thorac Surg.* 1996;62(6):1650-1654.
23. Casanova J, Bastos P, Barreiros F, Gomes MR. Descending necrotizing mediastinitis—successful treatment using a radical approach. *Eur J Cardiothorac Surg.* 1997;12(3):494-496.
24. Karkas A, Chahine K, Schmerber S, Brichon PY, Righino CA. Optimal treatment of cervical necrotizing fasciitis associated with descending necrotizing mediastinitis. *Br J Surg.* 2010;97(4):609-615.
25. Roberts JR, Smythe WR, Weber RW, Lanutti M, Rosengard BR, Kaiser LR. Thoracoscopic management of descending necrotizing mediastinitis. *Chest.* 1997;112(3):850-854.
26. Isowa N, Yamada T, Kijima T, Hasegawa K, Chihara K. Successful thoracoscopic debridement of descending necrotizing mediastinitis. *Ann Thorac Surg.* 2004;77(5):1834-1837.
27. Min HK, Choi YS, Shim YM, Sohn YI, Kim J. Descending necrotizing mediastinitis: a minimally invasive approach using video-assisted thoracoscopic surgery. *Ann Thorac Surg.* 2004;77(1):306-310.
28. Son HS, Cho JH, Park SM, Sun K, Kim KT, Lee SH. Management of descending necrotizing mediastinitis using minimally invasive videoassisted thoracoscopic surgery. *Surg Laparosc Endosc Percutan Tech.* 2006;16(6):379-382.
29. Shimizu K, Otani Y, Nakano T, Takayasu Y, Yasuoka Y, Morishita Y. Successful video-assisted mediastinoscopic drainage of descending necrotizing mediastinitis. *Ann Thorac Surg.* 2006;81(6):2279-2281. <https://doi.org/10.1016/j.athoracsur.2005.07.096>

Conflict of interests: The authors declare that they have no conflict of interests.