

# RETINAL THICKNESS AFTER FOCAL PHOTOCOAGULATION FOR DIABETIC MACULAR EDEMA WITH AND WITHOUT TEMPORAL PERIFOVEAL THICKENING

VIRGILIO LIMA GÓMEZ<sup>1</sup>, DULCE MILAGROS RAZO BLANCO-HERNÁNDEZ<sup>2\*</sup>, YATZUL ZUHAILA GARCÍA RUBIO<sup>3</sup>  
AND PAULINA ANAID SÁNCHEZ MONTOYA<sup>3</sup>

<sup>1</sup>Service of Ophthalmology; <sup>2</sup>Research Division, Hospital Juárez de México, México D.F., Mexico; <sup>3</sup> Universidad Justo Sierra, México D.F., Mexico

## ABSTRACT

**Background:** Visual improvement after focal photocoagulation in diabetic macular edema is more common in eyes without temporal perifoveal thickening. This feature is related to a lower macular volume before treatment; the higher proportion of visual improvement could be associated with a shorter need of volume reduction. **Objective:** To compare macular volume before and after focal photocoagulation in eyes with diabetic macular edema, with and without temporal perifoveal thickening. **Methods:** Non-experimental, retrospective, longitudinal, comparative study in diabetics with macular edema treated with focal photocoagulation. Macular volume measured with optical coherence tomography, and best corrected visual acuity were compared between eyes with (group 1) and without temporal perifoveal thickening (group 2, independent samples Student's *t* test). The comparison was also performed after stratifying the groups by baseline visual acuity. **Results:** One hundred and twenty eyes, 65 eyes from group 1 (54.2%) and 55 from group 2 (45.8%). Mean volume before and after treatment and mean absolute and percentage changes were lower in group 2 ( $p < 0.001$ ) regardless of visual acuity. Macular volume decreased significantly in eyes of group 1; only eyes in group 2 with visual acuity  $< 0.5$  before treatment increased their visual function ( $p < 0.001$ ). **Conclusions:** Eyes without temporal perifoveal thickening had visual improvement, although their volume did not change statistically. The significant volume reduction in eyes with temporal perifoveal thickening was not associated to visual improvement. The anatomical change was not enough to explain the functional improvement. (REV INVEST CLIN. 2015;67:25-32)

Corresponding author: Dulce Milagros Razo Blanco-Hernández, [razoblanco.dulce@gmail.com](mailto:razoblanco.dulce@gmail.com)

**Key words:** Diabetic macular edema. Diabetic retinopathy. Macular volume. Perifoveal temporal sector.

### Corresponding author:

\*Dulce Milagros Razo Blanco-Hernández  
Research Division  
Hospital Juárez de México  
Av. IPN 5160 Col. Magdalena de las Salinas  
Delegación Gustavo A. Madero  
C.P. 07760, México, D.F.  
E-mail: [razoblanco.dulce@gmail.com](mailto:razoblanco.dulce@gmail.com)

Received for publication: 13-12-2013  
Accepted for publication: 09-10-2014

## INTRODUCTION

Diabetic retinopathy is the most common microvascular complication<sup>1</sup>, in which hyperglycemia causes structural and functional changes that damage the retinal capillaries<sup>2</sup>. Proliferative retinopathy and clinically significant macular edema are vision-threatening types of diabetic retinopathy<sup>3</sup>.

Clinically significant macular edema (CSME) is the leading cause of visual impairment in patients who have any degree of diabetic retinopathy. It affects up to 7.1% of the diabetic Latino population, predominantly of Mexican descent, in the United States<sup>4</sup>. In Mexico, the largest study reported a prevalence of 5.8% among diabetic patients<sup>5</sup>.

Clinically significant macular edema is characterized by a thickening of the macula, which disjoin the photoreceptors and may lead to loss of three lines of vision<sup>6</sup>. Thickening is due to vascular leakage, which may stem from a localized lesion in the capillaries (focal edema) or from abnormally permeable capillaries adjacent to an area of occluded capillaries (diffuse edema). Retinal fluorescein angiography is used to determine the origin and the extent of the leakage<sup>7</sup>.

The standard treatment for CSME with focal leakage is photocoagulation, which is applied to the thickened areas, where vascular leaks occur, in order to stabilize visual acuity<sup>6</sup>. Recent studies have shown that a high percentage of patients have experienced improvement in functional vision following the procedure<sup>8,9</sup>.

Optical coherence tomography (OCT) is an imaging tool used to quantify retinal thickness. Its 6 mm fast macular thickness map scan uses six radial lines that pass through the center of the macula to measure retinal thickness at 768 points and determine center point thickness (CPT, in microns) and macular volume (in mm<sup>3</sup>). The map divides the macula into nine fields: one at the center measuring 1 mm in diameter and four within each of two concentric circles with diameters of 3 and 6 mm<sup>10</sup>.

One of the features associated with visual improvement after photocoagulation is the absence of thickening in the temporal perifoveal region of the macula before treatment<sup>11</sup>. It has been reported that macular volume before photocoagulation is lower in eyes without any

thickening in the temporal perifovea than in eyes with thickening<sup>12</sup>. The higher rate of visual improvement in eyes without thickening in the temporal perifoveal region may be because they require less reduction in volume. This feature may improve prognosis, but it has not been evaluated.

A study was conducted to compare changes in macular volume after focal photocoagulation in patients with and without thickening in the temporal perifoveal region of the macula before initiation of treatment.

## MATERIAL AND METHODS

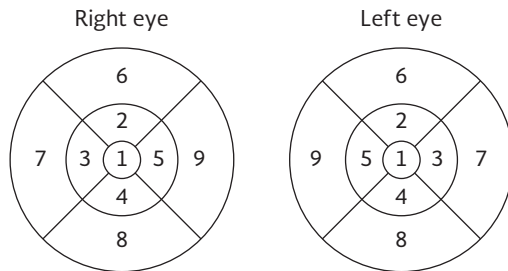
An observational, comparative, retrospective, longitudinal open study was conducted in type 2 diabetes patients with CSME from Mexico City and its metropolitan area. The sample was made up of patients treated at the Hospital Juárez in Mexico between January 1, 2005 and October 31, 2012. The study was approved by the Research and Research Ethics Committees of the hospital where it was conducted; all patients authorized their participation in the study by signing the informed consent form.

Patients of both genders with ages between 40 and 80 years who were enrolled had type 2 diabetes, some degree of diabetic retinopathy, and focal CSME treated with photocoagulation. Patients underwent fast macular thickness map scans and visual acuity (VA) measurement on the day of treatment and three weeks later.

Eyes with opaque media that limited VA (cataract, pre-retinal hemorrhage), thickened posterior vitreous cortex, ischemia on fluorescein angiography, conditions in which vision is reduced after treatment (subretinal neovascularization, retinal detachment, optic neuritis, vascular occlusions), errors in the fast macular thickness map measurements or insufficient information in the medical history were excluded.

Clinically significant macular edema was diagnosed by a single investigator, on the basis of criteria defined by the Early Treatment Diabetic Retinopathy Study (ETDRS): (i) thickening of the retina at or within 500  $\mu$ m of the center of the macula, (ii) hard exudates at or within 500  $\mu$ m of the center of the macula, if associated with thickening of the adjacent retina, and (iii) a zone or zones of retinal thickening 1 disc area or larger, any part of which is within 1 disc diameter

Figure 1. Location of fields 7 on fast macular thickness map (temporal perifoveal region).



of the center of the macula<sup>6</sup>. In accordance with ET-DRS guidelines, a single investigator performed focal photocoagulation.

Fast macular mapping was performed after mydriasis by a single investigator on a Stratus OCT device (Version 4.01, Carl Zeiss Meditec, Inc., Dublin, CA, USA) using the following procedure: evaluation of spherical equivalent, identification of the retinal area with an acoustic signal, Z-offset and polarization were optimized and a strategy for dark eye was used tracking used. All maps were made using the flash setting between 9:00 and 11:00 a.m. in order to reduce variability due to time-of-day effects<sup>13</sup>. To confirm that they were properly centered, it was ensured that the thinnest area was within the central circle and that the center thickness standard deviation to center thickness ratio was less than 10%<sup>14</sup>.

Any deviations from the OCT scan line with respect to the actual boundaries of the retina<sup>14</sup> and a signal strength  $< 4$  were considered to be measurement errors.

The sample was divided into two groups: Group 1, eyes with thickening in the temporal perifovea before photocoagulation and Group 2, eyes without. Thickening in the temporal perifovea was defined as retinal thickness in field 7 of the fast macular thickness map (Fig. 1) that exceeded the mean thickness in eyes without retinopathy ( $259.4 \mu\text{m}$ ) for that quadrant by more than two standard deviations<sup>15</sup>.

The variables studied were changes in macular volume and VA after photocoagulation. The former was defined as the difference in volume before and after three weeks of treatment measured in terms of  $\text{mm}^3$  (absolute change), as a percentage of baseline volume (percent change) and as a percentage of the potential change expected after the procedure. Potential change

was defined as the difference between pre-treatment volume and the mean volume in diabetics without retinopathy in the reference population<sup>16</sup> ( $6.29 \text{ mm}^3$ )<sup>15</sup>.

Change in VA was defined as the arithmetic difference in refraction and best corrected VA measurements made before and after photocoagulation, in decimal notation; a positive value was considered to be an indicator of visual improvement. The CPT was considered as a secondary variable.

Student's *t* test for independent samples was used to compare mean macular volume before and after treatment, potential mean, absolute and percent changes, mean percentage of potential change, and mean change in VA between the groups. Student's paired *t*-test was used to compare mean macular volume and mean VA before and after treatment in each group.

A second evaluation was made after the groups were stratified according to baseline VA ( $< 0.5$  [ $< 20/40$ ] or  $\geq 0.5$  [ $\geq 20/40$ ]). Changes in the macular volume of eyes with and without visual improvement were compared (Student's *t* test for independent samples) and the correlation between absolute changes in macular volume and VA was determined.  $P < 0.05$  was considered significant; the data were captured and analyzed using Minitab® v16 software.

## RESULTS

A total of 120 eyes from 89 patients were evaluated. Their ages ranged from 41 to 83 years (mean 59.5 years; standard deviation [SD]  $\pm 8.9$ ); 68 patients (56.7%) were female. Duration of diabetes ranged from one to 35 years, (mean 16.6 years; SD  $\pm 7.0$ ); 63 eyes belonged to patients with systemic arterial hypertension (52.5%).

Pre-treatment VA ranged from 0.02 to 1.00 (mean 0.52, SD  $\pm 0.27$ ); in 57 eyes VA was  $< 0.5$  (47.5%). The grade of diabetic retinopathy was non-proliferative mild in 12 eyes (10%), non-proliferative moderate in 65 (54.2%), non-proliferative severe in 11 (9.2%); proliferative in 32 (26.6%). In 65 eyes (54.2%) the type of edema present was focal.

Prior to treatment, the mean CPT was  $181.4 \pm 35.9 \mu\text{m}$  and mean macular volume was  $7.82 \pm 0.58 \text{ mm}^3$ .

Table 1. Comparison of changes in macular volume between eyes with and eyes without visual improvement

Variable	Eyes with visual improvement n = 49	Eyes without visual improvement n = 71	p*
Absolute change (mm <sup>3</sup> )	-0.18 ± 0.34	-0.09 ± 0.32	0.1
Percentage change (%)	-2.14 ± 4.16	-1.07 ± 3.86	0.1
Potential change (mm <sup>3</sup> )	0.98 ± 0.54	0.91 ± 0.61	0.4

\*Student's t test for independent samples.

After treatment, mean CPT was  $184.1 \pm 40.9 \mu\text{m}$  ( $p = 0.2$ ), mean macular volume was  $7.70 \pm 0.52 \text{ mm}^3$  ( $p < 0.001$ ) and VA was  $0.54 \pm 0.28$  ( $p = 0.2$ ).

Thickness in field 7 ranged from 214 to 416  $\mu\text{m}$  (mean  $274.1$ ;  $\text{SD} \pm 40.8$ ); 65 eyes (54.2%) were assigned to group 1 and 55 (45.8%) were assigned to group 2.

Forty-nine eyes showed improvement in vision (40.8%; 95% CI: 32.0-49.6). This proportion did not differ significantly between group 1 (35.4%) and group 2 (47.3%;  $p = 0.1$ ).

No significant difference was found in the means of the potential, absolute, and percentage changes in volume between eyes with and those without visual improvement (Table 1).

In eyes with VA  $< 0.5$  before the procedure, the mean change in this variable ( $0.09 \pm 0.17$ ;  $p > 0.05$ ) was higher than in the eyes with better vision ( $-0.04$ ;  $\text{SD} \pm 0.18$ ;  $p = 0.0001$ ).

## Group 1

Thirty-four eyes presented with VA  $< 0.5$  (52.3%); 23 eyes (35.4%) had proliferative diabetic retinopathy. Prior to treatment, mean VA was  $0.49 \pm 0.25$ , mean CPT was  $193.3 \pm 37.9 \mu\text{m}$ , and mean macular volume was  $8.17 \pm 0.47 \text{ mm}^3$ . Mean potential change in the macular volume was  $1.28 \pm 0.47 \text{ mm}^3$ .

After treatment, mean VA was  $0.49 \pm 0.27$  ( $p = 0.9$ ), mean CPT was  $193.7 \pm 45.6 \mu\text{m}$  ( $p = 0.9$ ), and mean macular volume was  $7.95 \pm 0.45 \text{ mm}^3$  ( $p < 0.001$ ). The mean absolute change in volume was  $-0.22 \pm 0.36 \text{ mm}^3$ , mean percentage change in volume was  $-2.6 \pm 4.3\%$ , and mean percentage of potential change was  $-15.2 \pm 28.2\%$ .

## Group 2

Twenty-three eyes presented with VA  $< 0.5$  (41.8%); nine eyes (16.4%) had proliferative diabetic retinopathy. Prior to treatment, mean VA was  $0.456 \pm 0.28$ , mean CPT was  $167.4 \pm 27.8 \mu\text{m}$ , and mean macular volume was  $7.43 \pm 0.42 \text{ mm}^3$ . Mean potential change in the macular volume was  $0.53 \pm 0.42 \text{ mm}^3$ .

After treatment, mean VA was  $0.61 \pm 0.28$  ( $p = 0.1$ ), mean CPT was  $172.6 \pm 31.5 \mu\text{m}$  ( $p = 0.6$ ), and mean macular volume was  $7.41 \pm 0.44 \text{ mm}^3$  ( $p = 0.6$ ). The mean absolute change in volume was  $-0.014 \pm 0.23 \text{ mm}^3$ , mean percentage change in volume was  $-0.16 \pm 3.12\%$ , and mean percentage of potential change was  $-2.9 \pm 134.6\%$ .

Mean volumes before and after treatment, as well as the means of the potential, absolute, and percentage changes, were significantly greater in group 1 than in those of group 2. The percentage of potential change was greater in group 1, but the difference was not significant (Table 2).

Among eyes with VA  $< 0.5$  ( $< 20/40$ ) before photocoagulation ( $n = 57$ ), 18 in group 2 showed visual improvement ( $n = 23$ , 78.3%) as did 15 in group 1 ( $n = 34$ , 44.1%;  $p = 0.01$ ; relative risk: 1.77; 95% CI: 1.15-2.74). Among eyes with VA  $\geq 0.5$  ( $\geq 20/40$ ) before photocoagulation ( $n = 65$ ), eight eyes in group 1 ( $n = 31$ , 25.8%) and eight in group 2 ( $n = 32$ , 25.0%) showed visual improvement ( $p = 0.5$ ).

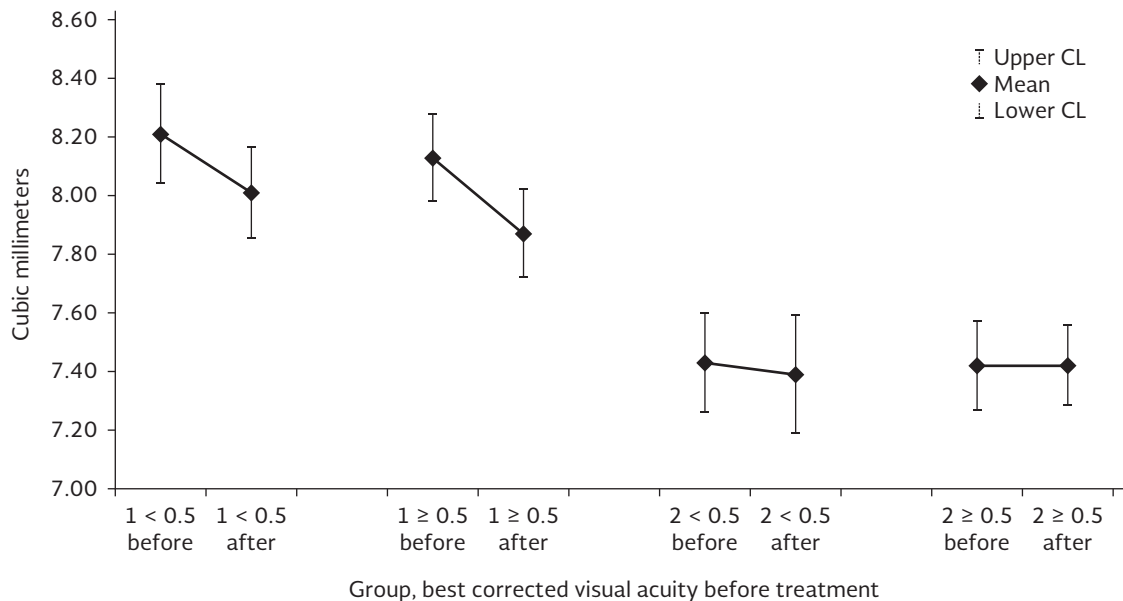
As the groups were stratified on the basis of VA prior to treatment, a significant decrease in macular volume was found in the eyes in group 1, but not in those in group 2 (Fig. 2). In group 2, only eyes with VA  $< 0.5$  ( $< 20/40$ ) before treatment showed significant visual improvement while the rest showed no significant

Table 2. Comparison of visual acuity and macular volume, and changes in them between the groups

Variable	Group 1 (With thickening in field 7) n = 65	Group 2 (Without thickening in field 7) n = 55	p*
Volume before treatment	8.17 ± 0.47 mm <sup>3</sup>	7.43 ± 0.42 mm <sup>3</sup>	< 0.001
Volume after treatment	7.95 ± 0.45 mm <sup>3</sup>	7.41 ± 0.44 mm <sup>3</sup>	< 0.001
Absolute change in volume	-0.22 ± 0.36 mm <sup>3</sup>	-0.01 ± 0.23 mm <sup>3</sup>	0.001
Percentage change in volume	-2.6 ± 4.3%	-0.16 ± 3.12%	0.001
Potential change in volume	1.28 ± 0.47 mm <sup>3</sup>	0.54 ± 0.42 mm <sup>3</sup>	< 0.001
Percentage of change in potential volume observed	-15.2 ± 28.2%	-2.9 ± 134.7%	0.5
Absolute change in visual acuity	-0.002 ± 0.17	0.04 ± 0.21	0.2

\*Student's t test for independent samples.

Figure 2. Change in macular volume by group. Stratification according to visual acuity prior to treatment.



change (Fig. 3). Eyes in group 2 with VA < 0.5 (< 20/40) showed a significant increase in CPT (Table 3).

The correlation between change in volume and change in VA was low in every group (Fig. 4, Table 4).

## DISCUSSION

The decrease in macular volume following photocoagulation was lower in eyes without thickening in the temporal perifovea than in those with thickening. The percentage of potential change in volume that was attained and the mean change in VA did not vary between the groups.

Razo Blanco-Hernández, et al. reported that macular volume was greater in eyes with thickening in the temporal perifovea<sup>12</sup>, and the lower rate of improvement in vision in them may be because they require a greater reduction in volume in order to attain normal retinal thickness. As the probability of an improvement in vision is greater in eyes with VA < 0.5 (< 20/40) has already been documented<sup>6</sup>, the sample was stratified in order to minimize the impact of this factor on the response to treatment.

The mean change in volume did not vary between eyes that showed visual improvement and eyes that did not. Changes in volume did not vary as the groups were stratified on the basis of VA: it was decreased

Figure 3. Change in visual acuity by group. Stratification according to visual acuity prior to treatment.

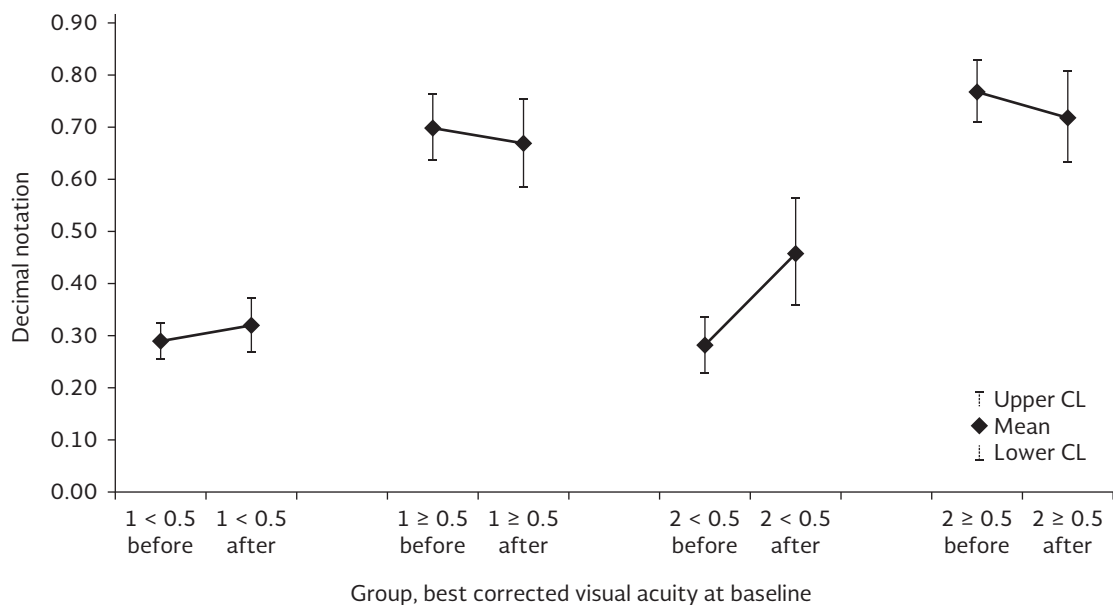


Table 3. Comparison of macular volume, best corrected visual acuity, and center point thickness prior to and after treatment; groups were stratified according to baseline visual acuity

Group	Variable	Before	After	p*
1, VA < 0.5 (n = 34)	Volume	8.21 ± 0.50	8.01 ± 0.46	0.005
	VA	0.29 ± 0.10	0.32 ± 0.15	0.3
	CPT	193.9 ± 37.7	197.2 ± 48.2	0.5
1, VA ≥ 0.5 (n = 31)	Volume	8.13 ± 0.44	7.87 ± 0.44	< 0.001
	VA	0.70 ± 0.18	0.67 ± 0.25	0.4
	CPT	192.6 ± 38.7	188.9 ± 43.1	0.4
2, VA < 0.5 (n = 23)	Volume	7.43 ± 0.41	7.39 ± 0.49	0.4
	VA	0.28 ± 0.13	0.46 ± 0.25	< 0.001
	CPT	161.3 ± 30.6	170.1 ± 38.3	0.04
2, VA ≥ 0.5 (n = 32)	Volume	7.42 ± 0.44	7.42 ± 0.39	0.9
	VA	0.77 ± 0.17	0.72 ± 0.25	0.1
	CPT	171.7 ± 25.2	174.5 ± 25.9	0.4

\*Student's paired t test.

VA: visual acuity; CPT: center point thickness.

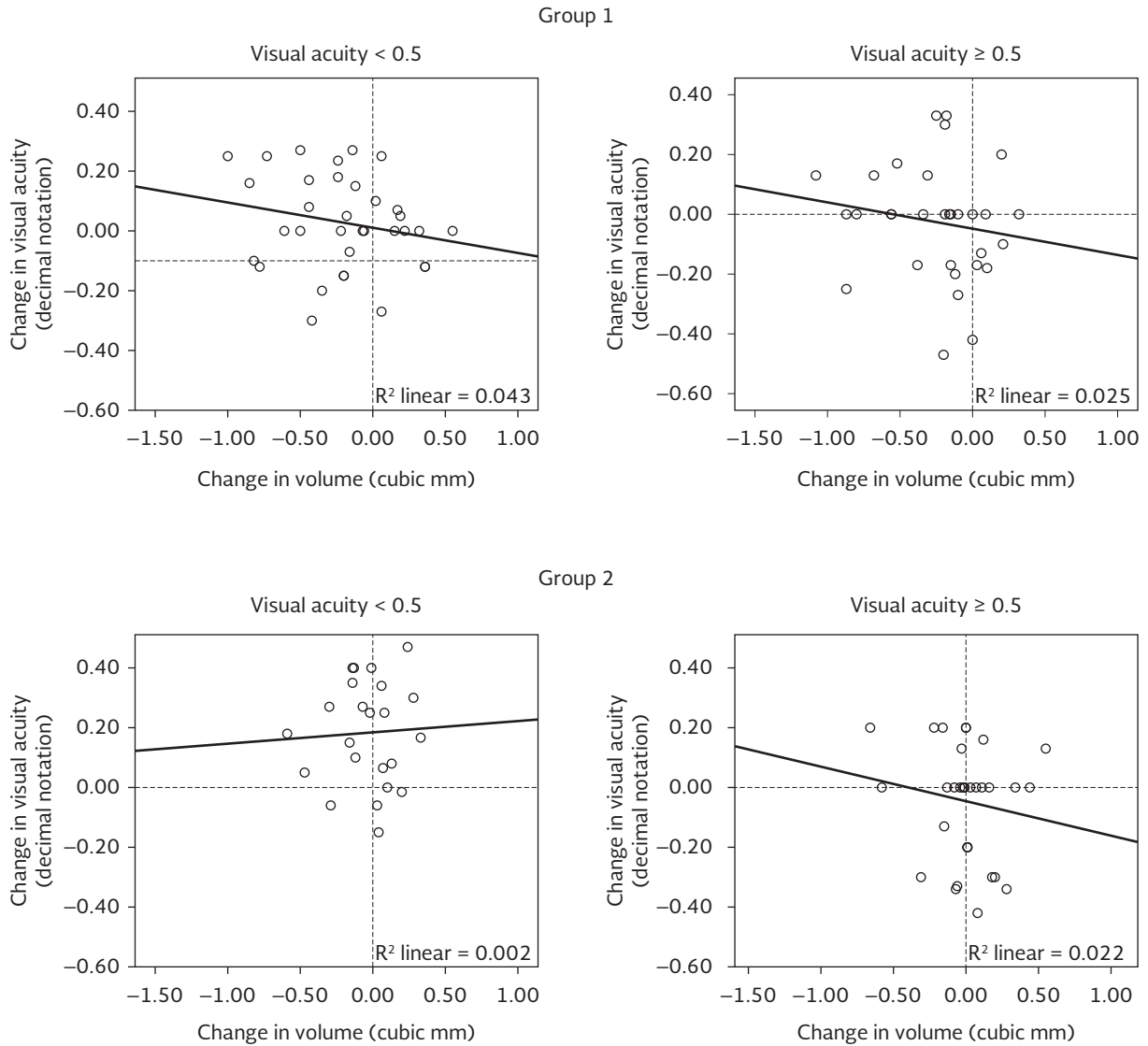
significantly in group 1, but not did not change in group 2. Stratification showed an increase in mean VA when it was < 0.5 (< 20/40) before treatment, which was only significant in eyes in group 2.

Studies in CSME have evaluated the correlation between change in CPT and change in VA, which DRCR.net has used to report “paradoxical” responses after photocoagulation, such as an increase in VA in eyes with an increase in CPT and *vice versa*<sup>17</sup>. Center point thickness is the area that allows the highest resolution,

but it has been determined that macular volume shows lower interobserver variability, which makes its measurement more reproducible<sup>18</sup>. It also been reported that change in macular volume is more useful to assess thickening that does not involve the center, such as the temporal perifovea this study has evaluated.

The correlation between change in macular volume and change in VA was low in both groups and their subgroups. In group 1, this outcome did not mean

Figure 4. Scatter plots of changes in macular volume and visual acuity stratified according to visual acuity at baseline.



treatment failure since the mean reduction in volume ( $-0.22 \pm 0.36 \text{ mm}^3$ ) was not far from the median values of eyes with adequate response to photocoagulation ( $0.13 \text{ mm}^3$ ) reported by Browning<sup>20</sup>.

Table 4. Correlation between changes in macular volume and best corrected visual acuity by group, with stratification of baseline visual acuity

Group	Pearson	p	r <sup>2</sup>
1, < 0.5 (n = 34)	-0.21	0.23	0.043
1, ≥ 0.5 (n = 31)	-0.16	0.39	0.025
2, < 0.5 (n = 23)	0.05	0.82	0.002
2, ≥ 0.5 (n = 32)	-0.15	0.42	0.022

In group 2, CPT and VA increased significantly and macular volume did not change. It is striking that in neither group did the mean percentage change of macular volume reach 3%, a difference that Krzystolik, et al. attributed to real changes and not to variability in the measurements<sup>21</sup>. The difference in reduction in macular volume between the groups was not enough to explain the change in VA, especially in eyes with VA  $\geq 0.5$  ( $\geq 20/20$ ) before photocoagulation.

In a study on diffuse macular edema, Vemala, et al. identified the superior and nasal parafovea and temporal periphery as the retinal regions with the least reduction in retinal thickness after photocoagulation<sup>19</sup>. Although

in this study eyes with focal edema were treated, the response to treatment was lower when there was thickening in the temporal perifoveal region, even after stratifying by VA before treatment.

The lower response to treatment in eyes with thickening in the temporal perifoveal may indicate retinal neuronal dysfunction in addition to the misalignment of photoreceptors that reduces the resolution in eyes with CSME. Two capillary plexuses converge in that region and thickening may be indicative of a more severe microvascular disease, even in the absence of capillary closure on fluorescein angiography.

Hudson, et al. observed reduced capillary blood flow in the temporal region of the macula in patients with diabetic macular edema, which was associated with areas of angiographic leakage<sup>22</sup>. Furthermore, research using electroretinography has found that electrical activity in the nasal area of the macula is lower than in the temporal region. Although it was suggested that the nasal area is more vulnerable, in eyes where there is thickening only in that region, it may indicate that there is residual function of the temporal sector, which is significantly greater<sup>23</sup>. The increased electrical activity may be associated with visual improvement in eyes without thickening in the temporal perifovea, which this study found in eyes with VA < 0.5 (< 20/40) before treatment.

Anatomical changes alone were not sufficient to explain the amount of visual improvement in the two groups, so it would be necessary to measure the sensitivity or electrical activity of the macula (through perimetry or electroretinography testing) in order to identify whether the absence of thickening in the temporal perifovea is indicative of a better functional status that may be associated with a better response to photocoagulation in eyes with diabetic macular edema.

## REFERENCES

1. Kollias AN, Ulbig MW. Diabetic retinopathy: Early diagnosis and effective treatment. *Dtsch Arztebl Int.* 2010;107:75-83.
2. Josifova T, Schneider U, Henrich PB, Schrader W. Eye disorders in diabetes: potential drug targets. *Infect Disord Drug Targets.* 2008;8:70-5.
3. Yau JW, Rogers SL, Kawasaki R, et al. Global prevalence and major risk factors of diabetic retinopathy. *Diabetes Care.* 2012; 35:556-64.
4. Varma R, Choudhury F, Klein R, Chung J, Torres M, Azen SP. Four-year incidence and progression of diabetic retinopathy and macular edema: the Los Angeles Latino Eye Study. *Am J Ophthalmol.* 2010;149:752-61.
5. Asociación Mexicana de Retina, Sociedad Mexicana de Oftalmología, Asociación Panamericana de Oftalmología. Resultados del día Panamericano de detección de retinopatía diabética (3 de julio de 1999, día "D"). *Rev Mex Oftalmol.* 2005;79:88-92.
6. American Academy of Ophthalmology Retinal Panel. Preferred Practice Patterns Guidelines. Diabetic retinopathy. San Francisco, CA: American Academy of Ophthalmology; 2008 (4th printing 2012).
7. Danis RP, Scott IU, Qin H, et al. Association of fluorescein angiographic features with visual acuity and with optical coherence tomographic and stereoscopic color fundus photographic features of diabetic macular edema in a randomized clinical trial. *Retina.* 2010;30:1627-37.
8. Shrestha A, Khadka D, Karmacharya A, et al. Is laser photocoagulation still effective in diabetic macular edema? Assessment with optical coherence tomography in Nepal. *Int J Ophthalmol.* 2012;5:217-21.
9. Zaidi ZA, Jacob MK. Effect of macular photocoagulation on visual acuity of Omani patients with clinically significant macular edema. *Oman J Ophthalmol.* 2009;2:62-6.
10. Polito A, Del Borrello M, Isola M, Zemella N, Bandello F. Repeatability and reproducibility of fast macular thickness mapping with Stratus optical coherence tomography. *Arch Ophthalmol.* 2005;123:1330-7.
11. Lima-Gómez V, Razo Blanco-Hernández DM. Características asociadas con la mejoría visual después de la fotocoagulación en edema macular diabético. *Cir Cir.* 2012;80:311-9.
12. Razo Blanco-Hernández DM, Romero-Vargas DM, Bermúdez-Zapata DA, Lima-Gómez V. Modificación del volumen macular por engrosamiento del área temporal, en edema macular diabético focal. *Rev Hosp Jua Mex.* 2011;78:146-51.
13. Polito A, Del Borrello M, Polini G, Furlan F, Isola M, Bandello F. Diurnal variation in clinically significant diabetic macular edema measured by the Stratus OCT. *Retina.* 2006;26:14-20.
14. Sada SR, Wu Z, Walsh AC, et al. Errors in retinal thickness measurements obtained by optical coherence tomography. *Ophthalmology.* 2006;113:285-93.
15. Lima-Gómez V, Osornio-Castro NA. Comparación del grosor retiniano en diabéticos sin retinopatía, con y sin fondo coroideo. *Rev Mex Oftalmol.* 2006;80:301-5.
16. Browning DJ, Glassman AR, Aiello LP, et al. Optical coherence tomography measurements and analysis methods in optical coherence tomography studies of diabetic macular edema. *Ophthalmology.* 2008;115:1366-71.
17. Browning DJ, Glassman AR, Aiello LP, et al. Relationship between optical coherence tomography-measured central retinal thickness and visual acuity in diabetic macular edema. *Ophthalmology.* 2007;114:525-36.
18. Browning DJ. Interobserver variability in optical coherence tomography for macular edema. *Am J Ophthalmol.* 2004;137: 1116-17.
19. Vemala R, Koshy S, Sivaprasad S. Qualitative and quantitative OCT response of diffuse diabetic macular oedema to macular laser photocoagulation. *Eye.* 2011;25:901-8.
20. Browning DJ. Interpreting thickness changes in the diabetic macula: the problem of short-term variation in optical coherence tomography-measured macular thickening (an american ophthalmological society thesis). *Trans Am Ophthalmol Soc.* 2010;108:62-76.
21. Krzystolik MG, Strauber SF, Aiello LP, Beck RW, Berger BB, Bressler NM. Reproducibility of macular thickness and volume using Zeiss optical coherence tomography in patients with diabetic macular edema. *Ophthalmology.* 2007;114:1520-5.
22. Hudson C, Flanagan JG, Turner GS, Chen HC, Rawji MH, McLeod D. Exaggerated relative nasal-temporal asymmetry of macular capillary blood flow in patients with clinically significant diabetic macular oedema. *Br J Ophthalmol.* 2005;89:142-6.
23. Holm K, Lövestam AM. In diabetic eyes, multifocal ERG reflects differences in function between the nasal part and the temporal part of the macula. *Graefes Arch Clin Exp Ophthalmol.* 2012; 250:1143-8.