

Update on lung separation techniques: Double-lumen tubes and bronchial blockers

Javier H. Campos, MD*

* Professor of Anesthesia. Vice Chair for Clinical Affairs. Director of Cardiothoracic Anesthesia. Executive Medical Director, Operating Rooms, Department of Anesthesia University of Iowa Health Care Roy and Lucille Carver College of Medicine, Iowa City, Iowa
javier-campos@uiowa.edu

INTRODUCTION

Recent advances in surgical techniques for thoracic, cardiac, or esophageal surgery have led to an increased use of lung separation techniques^(1,2). Currently a double-lumen endotracheal tube (DLT) or bronchial blockers⁽³⁻⁵⁾ are used to achieve one-lung ventilation (OLV). The independent blockers are used in general, in combination with a single-lumen endotracheal tube as with the wire-guided endobronchial blocker Arndt® blocker⁽⁶⁾, the Cohen® tip-deflecting endobronchial blocker⁽⁷⁾ or the Fuji Uniblocker®⁽⁸⁾.

There are a number of recognized indications for OLV. In practice, the most common indications for lung separation are: 1) for surgical exposure (lung separation), 2) for prevention of contamination to the contralateral lung from bleeding, pus or saline lavage (lung isolation), and 3) during differential lung ventilation for continuity of airway gas exchange such as with bronchopleural fistula. Table I describes the common indications for lung isolation with a DLT or an independent bronchial blocker.

CONTROVERSIES ON THE SELECTION OF THE PROPER SIZE OF DOUBLE-LUMEN ENDOTRACHEAL TUBES

A common problem with the selection of the proper size for a DLT is the lack of objective guidelines to properly choose the correct or approximate size of DLT. A left-sided DLT that is too small requires a large endobronchial cuff volumen, which might increase the incidence of malposition. In addition, a small DLT does not readily allow fiberoptic bronchoscope placement and can make suction difficult. A properly sized

Table I.

A. Indications for lung isolation with the use of a double-lumen endotracheal tube	
• Protection of one lung from contralateral contamination	
• Lung abscess	
• Lung cyst	
• Pulmonary hemorrhage	
• Bronchopulmonary lavage	
• Pulmonary alveolar proteinosis	
• Control and continuity of the airway for gas exchange	
• Bronchopleural fistula	
• Bronchial disruption	
• Pneumonectomy	
B. Indication for lung isolation with the use of a double-lumen endotracheal tube or a bronchial blocker	
• Any operation that requires surgical exposure through the chest cavity with lung collapse	
• Video-assisted thorascopic surgery	
• Lobectomy, bilobectomy, pneumonectomy	
• Mediastinal mass resection through the chest	
• Esophageal surgery	
• Orthopedic procedures (spine surgery involving the chest)	
• Minimally invasive cardiac surgery	
C. Specific indications for bronchial blockers	
• Difficult airways	
• Limited mouth opening	
• Nasotracheal intubation	
• Awake orotracheal intubation	
• Already intubated patient requiring lung isolation	
• Tracheostomy patient requiring lung isolation	
• Selective lobar blockade	
• Potential for mechanical ventilation in the postoperative period	

Este artículo puede ser consultado en versión completa en <http://www.medigraphic.com/rma>

DLT is one in which the main body of the tube passes without resistance through the glottis and advances easily within the trachea, and in which the bronchial component passes into the intended bronchus without difficulty. In a study performed in adult cadavers, it was shown that the cricoid ring diameter never exceeds the diameter of the glottis. If a DLT encounters resistance when passing the glottis, it is likely that the DLT would encounter resistance while passing the cricoid ring⁽⁹⁾.

Brodsky, et al⁽¹⁰⁾ reported that measurement of tracheal diameter at the level of the clavicle on the preoperative postero-anterior chest radiograph can be used to determine proper left-sided DLT size. These methods lead to 90% increase in the use of a larger left-sided DLT (i.e. 41 F DLT in men and 39 and 41 F DLT in women). A recent study involving thoracic anesthesiologists, Amar et al⁽¹¹⁾, has shown that the use of a smaller DLT (i.e. 35 F or 37 F leftsided DLT) rather than a conventionally larger sized DLT (i.e. 39 or 41 F) was not associated with any difference in clinical intraoperative outcome, regardless of patient size or gender in 300 patients undergoing thoracic surgery requiring OLV. However, in this study only 51 (35%) of the patients who received a 35F DLT were males, and 92 (65%) were females. In practice, women usually receive a 35 F DLT; therefore the question of whether or not a 35 F for all patients is favorable remains unclear.

When choosing a DLT for OLV, radiological studies must be reviewed in the preoperative evaluation. A posterior-anterior chest radiograph must be reviewed to assess the shadow of tracheobronchial anatomy along with bronchial bifurcation. It is estimated that in 75% of the films, the left mainstem bronchus shadow is seen. The trachea is located in the midline position, but often can be deviated to the right at the level of the aortic arch, with a greater degree of displacement in the setting of an arteriosclerotic aorta; advanced age or in the presence of chronic obstructive pulmonary disease (COPD). With COPD or aging, the lateral diameter of the trachea may decrease with an increase in the anterior-posterior diameter. Figure 1 shows the changes that occur in a 60 year-old man with severe COPD; a multidetector computed tomography scan of the chest and a 3D rendering of the trachea and bronchi which shows a deviated trachea and narrow bronchus. Points of importance include the recognition of any distorted anatomy identified in the films prior to placement of DLTs⁽¹²⁾.

USE OF FIBEROPTIC BRONCHOSCOPY FOR LEFT-SIDED DOUBLE-LUMEN ENDOTRACHEAL TUBES

The recommended technique for placement and positioning of a left-sided DLT is the bronchoscopy-guidance technique. The DLT is placed into the trachea utilizing standard techniques of direct laryngoscopy and is advanced only to the point where the trachea cuff is just beyond the vocal cords. A fiberoptic

bronchoscope of appropriate caliber is then advanced through the endobronchial lumen until main or tracheal carina is identified. The landmarks for identification of the main carina and the left mainstem bronchus include the posterior membranous portion of the trachea, sharpness of the carina, the lack of any visible secondary carina in the left mainstem (when viewed from above the main carina), and the right upper lobe orifice in the right mainstem. To verify the right mainstem bronchus, the fiberscope is advanced below the tracheal carina to the right side. The orifice to the right upper lobe is generally 1-2 cm below the tracheal carina but may occur at or proximal to the carina. Advancing the fiberscope inside this orifice should provide a clear view of the apical, anterior and posterior segments.

This is the only structure in the tracheobronchial tree that has 3 orifices. The fiberscope is then withdrawn back to the tracheal carina and advanced into the left mainstem bronchus until the left upper and left lower lobe bronchi are identified. The DLT tube is advanced into the left bronchus over the fiberscope until the tip of the tube becomes visible. The fiberscope is then withdrawn and advanced through the tracheal lumen until the tracheal carina is in view with the endobronchial lumen entering the left mainstem bronchus. The correct location is confirmed via the posterior position of the membranous portion of the trachea and the identification of the right upper lobe. Prior to turning the patient lateral, the optimal position is with the upper edge of the endobronchial cuff slightly below the carina inside the left mainstem bronchus. It is often found that turning the patient lateral results in an apparent movement of the tube more proximal into the trachea. This may rather be the result of a caudal movement of the diaphragm and carina because of the lessening of abdominal pressure with the lateral position.

After the patient is properly positioned, the correct position of the left DLT is re-confirmed by advancing the fiberscope through the tracheal lumen. It is recommended to proceed to

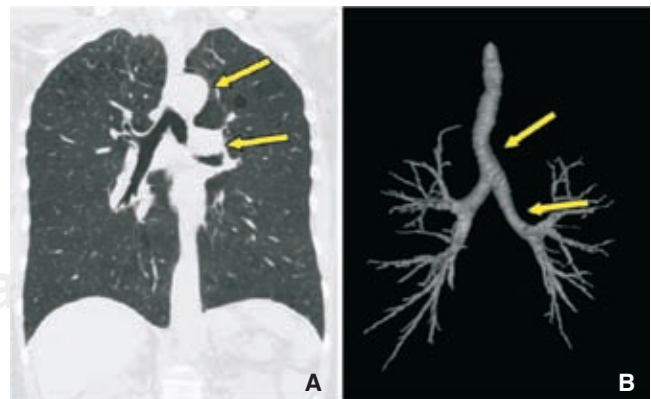
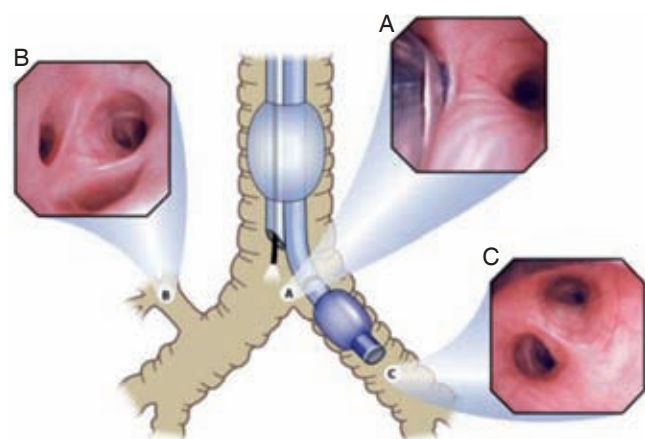


Figure 1. A: 60 years-old man with severe COPD, B: tomography scan of the chest and a 3D rendering of the trachea and bronchi which shows a deviated trachea and narrow bronchus.

inflate the endobronchial cuff with no more than 3 mL of air under direct vision with the fiberscope. The proper location of the endobronchial balloon is confirmed by observing a view of the blue edge of the cuff just below the tracheal carina in the left mainstem bronchus. However, particularly in short patients, it is possible that this may result in the endobronchial lumen entering the left lower lobe. Thus a second view must be obtained through the endobronchial lumen. Two observations are relevant: first, the fiberoptic bronchoscope is advanced inside the endobronchial lumen, and the patency of the lumen is observed before advancing the bronchoscope through the blue portion of the tube, the second observation is at the distal end of the endobronchial tip of the tube where a clear and unobstructed view of the left upper and left lower lobe bronchus entrance orifices are visualized distally. This view is the one that provides confirmation of the margin of safety for a left-sided DLT⁽¹³⁾. Figure 2 shows a fiberoptic bronchoscopy exam for left-sided DLT.

POSITIONING A LEFT-SIDED DOUBLE-LUMEN ENDOTRACHEAL TUBE USING AUSCULTATION

Although not currently recommended as the sole technique, DLT placement can be accomplished using a blind technique



With Permission: Campos JH: Curr Opin Anaesthesiol 2009; 22: 4-10(ref #12)

Figure 2. Shows the optimal position of a left-sided DLT. (A) Shows an unobstructed view of the entrance of the right mainstem bronchus when the fiberscope is passed through the tracheal lumen and the edge of the fully inflated endobronchial cuff is below the tracheal carina in the left bronchus. (B) Shows the take-off of the right-upper bronchus with the three segments (apical, anterior and posterior); this is a landmark to reconfirm a right bronchus (C) Shows an unobstructed view of the left-upper and left-lower bronchus when the fiberoptic bronchoscope is advanced through the endobronchial lumen.

and direct laryngoscopy in which a left-side DLT is passed beyond the vocal cords with a stylette in place (endobronchial cuff) then the stylette is withdrawn and the tube is rotated 90° counterclockwise and advanced until the tip of the tube enters the left mainstem bronchus. Evidence suggests that auscultation alone is unreliable for confirmation of proper DLT placement. A study involving 200 patients who were intubated by the blind technique in whom confirmation of placement of DLT was done first with auscultation and clamping one of the ports of the y-connector of the DLT, with a second anesthesiologist with expertise in fiberoptic bronchoscopy re-confirming the placement of the DLT showed that 35% of the right or left DLT's placed were malpositioned when auscultation was used alone. All detected malpositions were eventually corrected with the use of flexible fiberoptic bronchoscopy⁽¹⁴⁾. However another study⁽¹⁵⁾, reported the clinical experience with use of left-sided DLTs in 1,164 patients. Using auscultation and clinical signs, these investigators reported 98% efficacy in lung collapse. DLT placement without bronchoscopy is thus possible in highly skilled hands, but this does not excuse the need for bronchoscopic confirmation of tube location when the equipment is available.

As shown by a study involving non-thoracic anesthesiologists with very limited experience in lung separation techniques (DLTs or bronchial blockers), use of fiberoptic bronchoscopy does not guarantee success as there may be up to a 38% incidence of unrecognized tube malpositions⁽¹⁶⁾. The possible reported causes were lack of skill with fiberoptic bronchoscopy and lack of recognition of the tracheobronchial anatomy. It is my opinion that positioning a DLT with bronchoscopic guidance is an essential adjunct to correct lung isolation. However, I recognize that anesthesiologists without sufficient experience to recognize variant tracheobronchial anatomy, and who may not be fully skilled with flexible fiberoptic bronchoscopy, may wish to also utilize auscultation and blind placement techniques to increase their DLT placement success rate.

USE OF A RIGHT-SIDED DOUBLE-LUMEN ENDOTRACHEAL TUBE

The use of the right-sided DLT has become controversial in clinical practice^(17,18). This is in part because the limited scientific evidence to support the routine use of this device⁽¹⁹⁻²¹⁾. However, there are specific clinical situations in which a right-sided DLT is recommended (Table II).

The anatomic differences between the right and left mainstem bronchus are reflected in fundamentally different designs of the right-sided and left-sided DLTs. Because the right mainstem bronchus is shorter than the left bronchus, and because the right upper lobe bronchus originates at a distance of 1.5 to 2 cm from the carina, techniques using right

endobronchial intubation must take into account the location and potential obstruction of the orifice of the right upper lobe bronchus. The right-sided DLT incorporates a modified cuff, or slot, on the endobronchial side that allows ventilation of the right upper lobe. Refer to figure 3.

An early study showed that because of bronchial anatomy, the left-sided DLT is simpler to use and has a greater margin of safety than the right-sided DLT⁽¹³⁾. Another study⁽²³⁾ has shown failure to ventilate the right upper lobe bronchus in 11% of patients and obstruction of the right upper bronchus in 89% of patients. After right-sided DLT placement, however, recent studies relying on fiberoptic bronchoscopy guidance techniques have shown no increased risk of obstruction of the right upper lobe orifice^(19,21). The only absolute contraindication for a right-sided DLT use is the presence of an anomalous right upper lobe take-off from the trachea, which has been estimated to be present in 1 of 250 otherwise normal subjects⁽²⁴⁾.

USE OF FIBEROPTIC BRONCHOSCOPY FOR RIGHT-SIDED DOUBLE-LUMEN ENDOTRACHEAL TUBES

The preferred technique for placement of a right-sided DLT is with the fiberoptic bronchoscopy guidance technique. After the right-sided DLT is passed beyond the vocal cords under direct laryngoscopy, the fiberoptic bronchoscope is advanced through the endobronchial lumen.

Before advancing the DLT, the tracheal carina, the entrance of the right mainstem bronchus, and the take-off of the right-upper lobe bronchus are identified. Then the DLT is rotated 90° to the right and advanced with the aid of the fiberoptic bronchoscope. The optimal position of a rightsided DLT is one that provides good alignment between the opening slot of the endobronchial lumen in relationship to the entrance of the right-upper lobe bronchus and distally a clear view of the bronchus intermedius and the right lower lobe bronchus seen from the endobronchial lumen. In order to align the slot of the tube with the right upper lobe bronchus a rotational movement of the DLT might be necessary. This recommendation is based upon the Mallinckrodt® right-sided DLT⁽²⁾. From the tracheal

view, the optimal position for a right-sided DLT provides a view of the edge of the blue cuff of the endobronchial balloon when inflated just below tracheal carina and a view of the entrance of the right mainstem bronchus. Also a clear view of the left mainstem bronchus must be seen. Figure 4 shows the optimal position of a right-sided DLT seen from the endobronchial or endotracheal view with a fiberoptic bronchoscope. All these recommendations for fiberoptic bronchoscopy must be applied during supine position, and then after the patient is turned into the lateral decubitus position and the most optimal surgical position is achieved, and whenever a malposition of the DLT occurs during surgery.

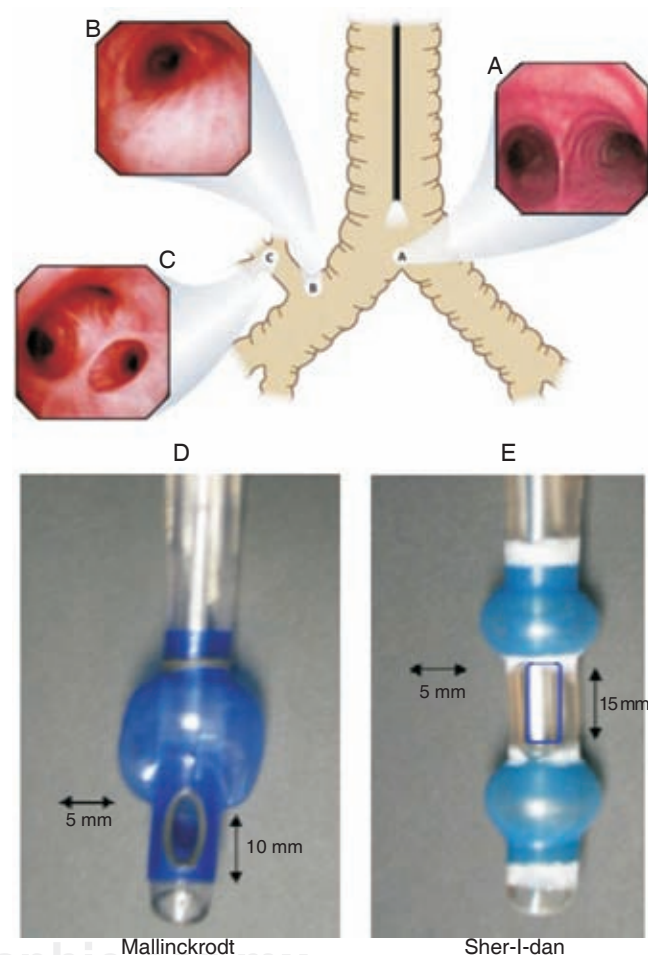
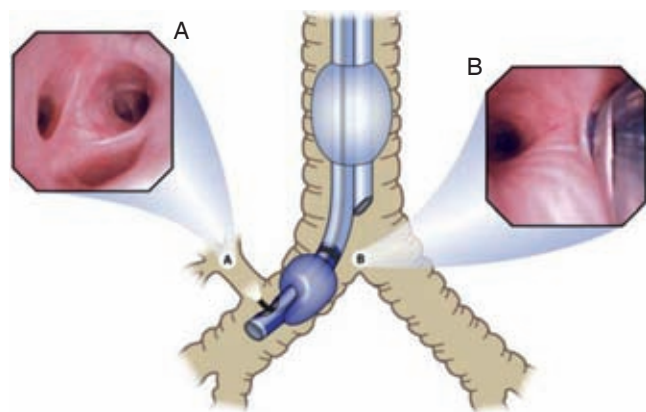


Figure 3. (A) displays a fiberoptic bronchoscopy view of the tracheal carina (B) displays fiberoptic bronchoscopy view of the take-off of the right upper bronchus to the right and bronchus intermedius to the left (C) shows a fiberoptic bronchoscopy view of the apical, anterior and posterior segments of the right upper bronchus (a landmark to identify right bronchus) (D) displays the Mallinckrodt® right-sided DLT and (E) displays the Sher-I-dan® rightsided DLT with two endobronchial cuffs.

Table II. Recommendations for a Right-Sided DLT

- Distorted anatomy at the entrance of left mainstem bronchus by an intrabronchial or external compression
- Compression at the entrance of the left mainstem bronchus due to a descending thoracic aortic aneurysm⁽²²⁾
- Left-sided pneumonectomy
- Left-sided single-lung transplantation
- Left-sided sleeve resection
- Any contraindication to place a left-sided DLT



With Permission: **Campos JH**: Curr Opin Anaesthesiol 2009; 22: 4-10(ref #12)

Figure 4. Shows the optimal position of a right-sided double-lumen endotracheal tube. (A) Shows the take-off of the right-upper bronchus with three segments (apical, anterior and posterior) when the fiberoptic bronchoscope emerges from the opening slot located in the endobronchial lumen. (B) Shows an unobstructed view of the entrance of the left mainstem bronchus when the fiberscope is passed through the tracheal lumen and the edge of the fully inflated endobronchial cuff is below the tracheal carina in the right bronchus.

NEW TECHNOLOGY WITH DOUBLE-LUMEN ENDOTRACHEAL TUBES

Fuji systems have introduced the Silbroncho DLT, which is made of silicone. The unique characteristic of this device relies on the wire-reinforced endobronchial tip. Also, the short bronchial tip and reduced bronchial cuff should increase the margin of safety when compared with a Broncho-cath left-sided DLT. At the present time, only a left-sided Silbroncho DLT is available on the market ⁽²⁵⁾. Also, there is a newly designed right-sided DLT, the Cliny[®](26). This device has a long oblique bronchial cuff and two ventilation slots for the right upper lobe. The proximal part of the bronchial cuff is located immediately opposite the tracheal orifice. This device can be useful in patients with a very short right mainstem bronchus. Figure 5, panel A displays the Silbroncho left-sided DLT and panel B displays the Cliny[®] right-sided DLT.

USE OF INDEPENDENT BRONCHIAL BLOCKERS DURING ONE-LUNG VENTILATION

Another alternative to achieve lung separation is by using an independent bronchial blocker passed through a single-lumen endotracheal tube. The various devices considered to be independent blockers include the wire-guided endobronchial

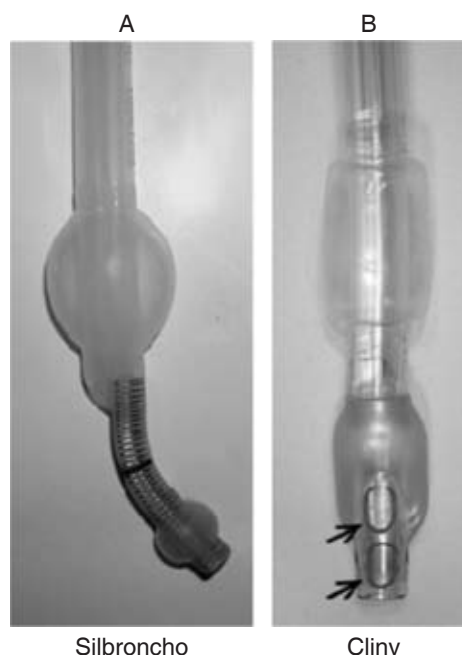


Figure 5. Double lumen tube-types.

blocker (Arndt[®] blocker), the Cohen[®] tip deflecting endobronchial blocker, and the Fuji Uniblocker[®] (6-8).

PLACEMENT AND POSITIONING OF THE ARNDT[®] BLOCKER

The Arndt[®] blocker is an independent endobronchial blocker that is passed through an existing single-lumen endotracheal tube. To facilitate insertion through the endotracheal tube, the blocker and the fiberoptic bronchoscope are lubricated. For a right-sided mainstem bronchus intubation, the spherically shaped blocker is recommended; for the left mainstem bronchus intubation, the elliptical or the spherical blocker is used⁽⁶⁾.

The placement of the Arndt[®] blocker involves placing the endobronchial blocker through the endotracheal tube and using the fiberoptic bronchoscope and wire-guided loop to direct the blocker into a mainstem bronchus. The fiberoptic bronchoscope has to be advanced distally enough so that the Arndt[®] blocker enters the bronchus while it is being advanced. When the deflated cuff is beyond the entrance of the bronchus, the fiberoptic bronchoscope is withdrawn, and the cuff is fully inflated with fiberoptic visualization with 4 to 8 mL of air to obtain total bronchial blockade.

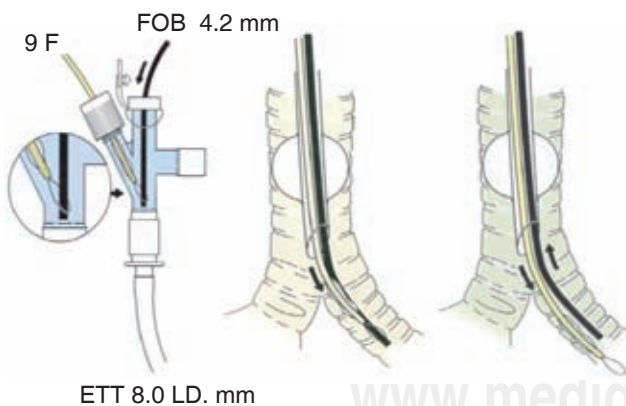
For right mainstem bronchus blockade, the Arndt[®] blocker can be advanced independently of the wire loop by observing its entrance into the right mainstem bronchus under fiberoptic visualization. Before turning the patient into a lateral decubitus position, the cuff of the blocker should be deflated, then advanced 1 cm deeper to avoid proximal dislodgement while

changing the patient's position; the placement again is confirmed in the lateral decubitus position. The wire loop can be withdrawn to convert the 1.4-mm channel into a suction port to expedite lung collapse. The newest version of the Arndt® blocker has a cone-shaped device that is attached to the center channel to connect and facilitate suction. It is important to remove the wire loop to avoid inclusion in the stapling line of the bronchus. The optimal position of the Arndt® blocker in the left or in the right bronchus is achieved when the blocker balloon's outer surface is seen with the fiberoptic bronchoscope at least 5 mm below the tracheal carina on the targeted bronchus and the proper seal is obtained. Figure 6 shows a guidance of the Arndt® blocker with the fiberoptic bronchoscope. Figure 7 shows the optimal placement of a bronchial blocker.

PLACEMENT AND POSITIONING OF THE COHEN® ENDOBRONCHIAL BLOCKER

The Cohen® blocker is advanced through an 8.0-mm ID single-lumen endotracheal tube; before insertion, the blocker balloon is tested and then fully deflated. This blocker needs to be lubricated to facilitate insertion and passage through the single-lumen endotracheal tube.

The placement of the Cohen® blocker involves placing the endobronchial blocker through the endotracheal tube and using the fiberoptic bronchoscope to observe the direction of the blocker into a mainstem bronchus. For blocking the right mainstem bronchus, the optimal position is the one that provides a view of the outer surface of the fully inflated balloon (4-8 mL of air) with the fiberoptic bronchoscope at least 5 mm below the tracheal carina on the right mainstem bronchus.



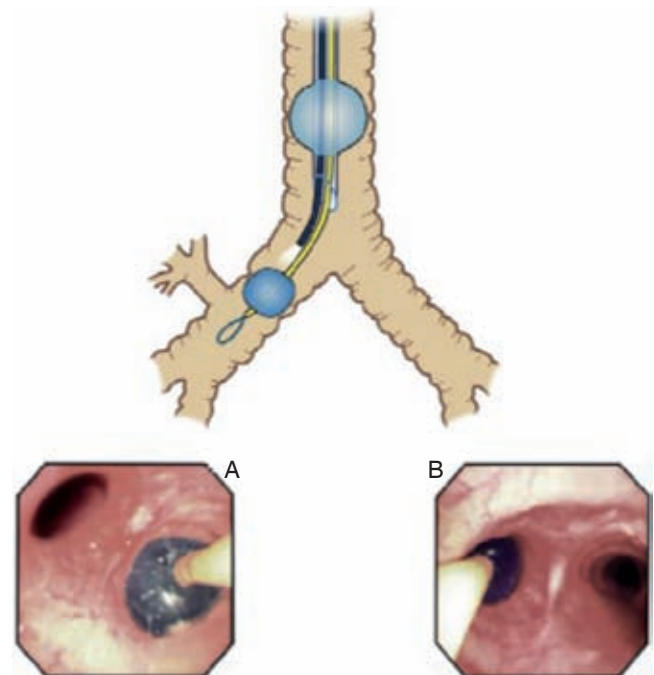
Abbreviations: FOB = fiberoptic bronchoscopy, ETT = single-lumen endotracheal tube.

Figure 6. Displays the placement of an Arndt® blocker through a single-lumen endotracheal tube with the fiberoptic bronchoscope advanced through the guidewire loop into the left mainstem bronchus.

Intubation of the left mainstem bronchus can be facilitated by allowing the tip of the single-lumen endotracheal tube to be near the entrance of the left bronchus, then twisting the Cohen® blocker to the left side. After the blocker is seen inside the left bronchus, the single-lumen endotracheal tube is withdrawn a few centimeters. A different alternative is to turn the head towards the right allowing the left main bronchus to displace to the midline. This maneuver will facilitate the placement of a Cohen® blocker into the left mainstem bronchus. The optimal position in the left mainstem bronchus is achieved when the blocker balloon's outer surface is seen with the fiberoptic bronchoscope at least 5 mm below the trachea carina inside the left mainstem bronchus.

PLACEMENT AND POSITIONING OF THE FUJI UNIBLOCKER®

The Fuji Uniblocker® size 9 F is advanced through an 8.0-mm ID single-lumen endotracheal tube; before insertion the blocker balloon is tested, and then fully deflated. This blocker



With Permission: Campos JH: Curr Opin Anaesthesiol_2009; 22: 4-10 (ref #12)

Figure 7. Shows the optimal position of a bronchial blocker in the right and left mainstem bronchus. The proximal edge of the fully inflated cuff is approximately 5-10 mm below the trachea carina. (A) Shows a bronchial blocker in the right mainstem bronchus and (B) shows a bronchial blocker in the left mainstem bronchus.

needs to be lubricated to facilitate insertion and passage through the single-lumen endotracheal tube.

The placement of the Fuji Uniblocker® involves placing the endobronchial blocker through the endotracheal tube and using the fiberoptic bronchoscope to observe the direction of the blocker into a mainstem bronchus. The torque control shaft with the blocker allows guidance into the desired target bronchus. For blocking the right mainstem bronchus, the optimal position is the one that provides a view of the outer surface of the fully inflated balloon (4-8 mL of air) with the fiberoptic bronchoscope at least 5 mm below the tracheal carina on the right mainstem bronchus. The optimal position in the left mainstem bronchus is achieved when the blocker balloon's outer surface is seen with the fiberoptic bronchoscope at least 5-10 mm below the trachea carina inside the left mainstem bronchus.

LUNG COLLAPSE DURING ONE-LUNG VENTILATION

A challenge for every anesthesiologist is to properly position a lung isolation device and make it work by allowing the lung to collapse. In a study⁽⁶⁾ comparing the Broncho-Cath left-sided DLT with the Univent® blocker and the Arndt® blocker, it was shown that the average time for lung collapse is 17 min for a DLT (spontaneous lung collapse without suction) versus 19-26 min for the Univent® or Arndt® blocker (assisted with suction). Once lung isolation was achieved, however, the overall clinical performance was similar for the three devices studied. Another study⁽⁸⁾ involving a left-sided DLT and comparing it with the Arndt®, the Cohen®, or the Fuji® blocker, showed that the surgical exposure was equivalent among the devices studied. However, the

bronchial blockers required longer time to position and were more prone to intraoperative reposition.

A recent study⁽²⁷⁾ has shown that de-nitrogenation of the lung which is to be collapsed with a FiO₂ 1.0 is a useful strategy to improve surgical conditions during OLV; in contrast, the use of air in the inspired mixture during two-lung ventilation and prior to OLV delays lung collapse.

FUTURE TRENDS IN LUNG ISOLATION

Anesthesia simulators have been used to enhance learning and to improve performance^(31,32), usually under the personal direction of an experienced clinician. Therefore, one educational approach to lung isolation techniques might involve training on an airway simulator monitored by an experienced thoracic anesthesiologist. An alternative is to train in fiberoptic bronchoscopy simulator⁽³³⁾ on lung isolation techniques particularly for the occasional anesthesiologist who does not perform thoracic cases on a regular basis^(34,35). It is the author's personal opinion that every surgical center that performs lung isolation techniques must consider the development of a pulmonary workstation along with simulator training facility to enhance teaching to residents, fellows and staff anesthesiologists.

SUMMARY

The basic principle of successful lung separation requires 1) recognition of tracheobronchial anatomy with posterior-anterior chest radiograph in the preoperative evaluation and with flexible fiberoptic bronchoscopy in the perioperative period, 2) familiarity and skills with flexible fiberoptic bronchoscopy, and 3) familiarity and expertise with DLTs and independent bronchial blockers.

Table III. Displays the advantages and disadvantages of DLTs and bronchial blockers.

Double-Lumen Endotracheal Tubes	Bronchial Blockers (Arndt®, Cohen®, Fuji®)
Advantages	Advantages
<ul style="list-style-type: none"> • Large lumen facilitates suctioning • Best device for absolute lung separation • Conversion from 2- to 1-lung ventilation easy and reliable 	<ul style="list-style-type: none"> • Easy recognition of anatomy if the tip of a single tube is above carina • Best device for patients with difficult airways • No cuff damage during intubation • No need to replace a tube if mechanical ventilation is needed
Disadvantages	Disadvantages
<ul style="list-style-type: none"> • Difficulties in selecting proper size • Difficult to place during laryngoscopy • Damage to tracheal cuff • Major tracheo-bronchial injuries⁽²⁸⁻³⁰⁾ 	<ul style="list-style-type: none"> • Small channel for suctioning • Conversion from 1- to 2- then to 1-lung ventilation (problematic for the novice) • High maintenance device (dislodgement or loss seal during surgery)^(6,8)

Campos JH. Curr Opin Anaesthesiol. 2007; 20: 27-31 (ref. #5)

REFERENCES

- Campos JH. Progress in lung separation. *Thorac Surg Clin* 2008;15:71-83.
- Campos JH. Current techniques for perioperative lung isolation in adults. *Anesthesiology* 2002;97:1295-1301.
- Campos JH. An update on bronchial blockers during lung separation techniques in adults. *Anesth Analg* 2003;97:1266-1274.
- Neustein SW. The use of bronchial blockers for providing one-lung ventilation. *J Cardiothorac Vasc Anesth* 2009;23:860-869.
- Campos JH. Which device should be considered the best for lung isolation: double-lumen endotracheal tube *versus* bronchial blockers. *Curr Opin Anaesthesiol* 2007;20:27-31.
- Campos JH, Kernstine KH. A comparison of a left-sided Broncho-Cath with the torque control blocker univent and the wire-guided blocker. *Anesth Analg* 2003;96:283-289.
- Cohen E. The Cohen flexitip endobronchial blocker: an alternative to a double lumen tube. *Anesth Analg* 2005;101:1877-1879.
- Narayanaswamy M, McRae K, Slinger P, et al. Choosing a lung isolation device for thoracic surgery: a randomized trial of three bronchial blockers *versus* double-lumen tubes. *Anesth Analg* 2009;108:1097-1101.
- Seymour AH, Prakash N. A cadaver study to measure the adult glottis and subglottis: Defining a problem associated with the use of a double-lumen tubes. *J Cardiothorac Vasc Anesth* 2002;16:196-198.
- Brodsky JB, Macario A, Mark JB. Tracheal diameter predicts double-lumen tube size: a method for selecting left double-lumen tubes. *Anesth Analg* 1996;82:861-864.
- Amar D, Desiderio DP, Heerd PM, et al. Practice patterns in choice of left double-lumen tube size for thoracic surgery. *Anesth Analg* 2008;106:379-383.
- Campos JH. Update on tracheobronchial anatomy and flexible fiberoptic bronchoscopy in thoracic anesthesia. *Curr Opin Anaesthesiol* 2009;22:4-10.
- Benumof JL, Partridge BL, Salvatierra C, Keating J. Margin of safety in positioning modern double-lumen endotracheal tubes. *Anesthesiology* 1987;67:729-738.
- Klein U, Karzai W, Bloos F, et al. Role of fiberoptic bronchoscopy in conjunction with the use of double-lumen tubes for thoracic anesthesia: a prospective study. *Anesthesiology* 1998;88:346-350.
- Brodsky JB, Lemmens HJ. Left double-lumen tubes: clinical experience with 1,170 patients. *J Cardiothorac Vasc Anesth* 2003;17:289-298.
- Campos JH, Hallam EA, Van Natta T, Kernstine KH. Devices for lung isolation used by anaesthesiologists with limited thoracic experience: comparison of double-lumen endotracheal tube, Univent torque control blocker, and Arndt wire-guided endobronchial blocker. *Anesthesiology* 2006;104:261-266.
- Campos JH, Gomez MN. Pro: Right-sided double-lumen endotracheal tubes should be routinely used in thoracic surgery. *J Cardiothorac Vasc Anesth* 2002;16:246-248.
- Cohen E. Con: right-sided double-lumen endotracheal tubes should not be routinely used in thoracic surgery. *J Cardiothorac Vasc Anesth* 2002;16:249-252.
- Campos JH, Massa FC, Kernstine KH. The incidence of right upper-lobe collapse when comparing a right-sided double-lumen tube *versus* a modified left double-lumen tube for leftsided thoracic surgery. *Anesth Analg* 2000;90:535-540.
- Bussi res JS, Lacasse Y, C  t   D, et al. Modified right-sided Broncho-Cath double lumen tube improves endobronchial positioning: a randomized study. *Can J Anaesth* 2007;54:276-282.
- Ehrenfeld JM, Walsh JL, Sandberg WS. Right -and left-sided Mallinckrodt double-lumen tubes have identical clinical performance. *Anesth Analg* 2008;106:1847-1852.
- Campos JH, Ajax TJ, Knutson R, et al. Case conference 5-1990. A 76-year-old man undergoing an emergency descending thoracic aortic aneurysm repair has multiple intraoperative and postoperative complications. *J Cardiothorac Anesth* 1990;4:631-645.
- McKenna MJ, Wilson RS, Botelho RJ. Right upper lobe obstruction with right-sided doublelumen endobronchial tubes: a comparison of two tube types. *J Cardiothorac Anesth* 1988;2:734-740.
- Stene R, Rose M, Weinger MB, Benumof JL, et al. Bronchial trifurcation at the carina complicating use of a double-lumen tracheal tube. *Anesthesiology* 1994;80:1162-1164.
- Lohser J, Brodsky JB. Silbronco double-lumen tube. *J Cardiothorac Vasc Anesth* 2006;20:129-131.
- Hagihira S, Takashina M, Mashimo T. Application of a newly designed right-sided, doublelumen endobronchial tube in patients with a very short right mainstem bronchus. *Anesthesiology* 2008;109:565-568.
- Ko R, McRae K, Darling G, et al. The use of air in the inspired gas mixture during two-lung ventilation delays lung collapse during one-lung ventilation. *Anesth Analg* 2009;108:1092-1096.
- Fitzmaurice BG, Brodsky JB. Airway rupture from double-lumen tubes. *J Cardiothorac Vasc Anesth* 1999;13:322-9.
- Liu H, Jahr JS, Sullivan E, Waters PF. Tracheobronchial rupture after double-lumen endotracheal intubation. *J Cardiothorac Vasc Anesth* 2004;18:228-33.
- Benumof JL, Wu D. Tracheal tear caused by extubation of a double-lumen tube. *Anesthesiology* 2002;97:1007-8.
- Wong AK. Full scale computer simulators in anesthesia training and evaluation. *Can J Anesth* 2004;51:455-464.
- Nyssen AS, Larbuisson R, Janssens M, et al. A comparison of the training value of two types of anesthesia simulators: computer screen-based and mannequin-based simulators. *Anesth Analg* 2002;94:1560-1565.
- Duffy CH, Myles PS. Review: thoracic-anesthesia.com. *J Cardiothorac Vasc Anesth* 2008;22:644.
- Campos JH, Hallam EA, Ueda K. Training in the placement of the left-sided double-lumen tube among non-thoracic anaesthesiologists: intubation model simulator *versus* computer based digital video disc, a randomized controlled trial. *Eur J Anaesthesiol* 2011;28:169-174.
- Hasan ZU, Dorfling J, McLarney JT, et al. The patient simulator for training of anesthesia residents in the management of one lung ventilation. *Sim Healthcare* 2008;33:37-52.