



Acta de Otorrinolaringología & Cirugía de Cabeza y Cuello

www.revista.acorl.org.co



Reporte de caso

Rabdomiosarcoma del ala nasal en un paciente pediátrico. Un reporte de caso

Nasal ala Alveolar Rhabdomyosarcoma in a pediatric patient. A rare case report

María Paula Olivera-Arenas*, Luis Felipe Romero-Moreno**, Gilberto Eduardo Marrugo-Pardo***, Julián Tavera-Cordero****.

* Universidad Nacional de Colombia, Otolaryngology Service. Bogotá, Colombia. ORCID: 0000-0002-5618-6823

** Universidad Nacional de Colombia, Otolaryngology Service; Instituto Nacional de Pediatría. Ciudad de México, México. ORCID: 0000-0003-1331-8723

*** Instituto Nacional de Pediatría. Ciudad de México; Pediatric Otolaryngology Unit, Fundación Hospital de la Misericordia, Bogotá, Colombia. ORCID: 0000-0001-8616-5583

**** Hospital Central de la Policía. Bogotá, Colombia. ORCID: 0000-0003-0862-3758

Forma de citar: Olivera-Arenas MP, Romero-Moreno LF, Marrugo-Pardo GE, Tavera-Cordero J. Rabdomiosarcoma del ala nasal en un paciente pediátrico. Un reporte de caso. Acta otorrinolaringol. cir. cabeza cuello. 2022;50(4): 300-303. DOI.10.37076/acorl.v50i4.605

INFORMACIÓN DEL ARTÍCULO

Historia del artículo:

Recibido: 7 de marzo de 2021

Evaluado: 8 de noviembre de 2022

Aceptado: 11 de noviembre de 2022

Palabras clave (DeCS):

rabdomiosarcoma, senos paranasales, rabdomiosarcoma alveolar.

RESUMEN

Dada la respiración nasal preferencial que tiene la población pediátrica en los primeros meses de vida, la obstrucción nasal tiene más repercusiones a nivel clínico a diferencia de un adulto, lo cual hace más prioritario su diagnóstico y manejo. Una de las principales causas de obstrucción nasal en niños son las masas nasales, las cuales debido a sus múltiples etiologías causan bastante incertidumbre diagnóstica en el equipo médico. En este artículo se presenta el caso de una paciente de 10 meses con una masa en el ala nasal de crecimiento rápido; se realiza un rápido diagnóstico de rabdomiosarcoma que requiere un adecuado manejo. El rabdomiosarcoma con patrón alveolar se presenta de forma inusual en esta ubicación, es por esto por lo que se considera importante presentar este caso para mantenerlo en el algoritmo diagnóstico como una posibilidad y que, así como en el caso presentado, se pueda tener un diagnóstico temprano, un tratamiento adecuado y un resultado estético y funcional favorable.

Correspondencia:

Maria Paula Olivera-Arenas, MD

E-mail: mariapaulaolivera@gmail.com

Dirección: Departamento de Otorrinolaringología, Universidad Nacional de Colombia. Carrera 45 No. 26, Bogotá Colombia

Teléfono celular: 3134952747

ABSTRACT

Key words (MeSH):

Rhabdomyosarcoma, Paranasal Sinuses, Rhabdomyosarcoma, Alveolar.

Given preferential nasal breathing in the first months of life in the pediatric population, nasal obstruction has more clinical repercussions than it would have in adults, hence the need to give higher priority to its diagnosis and management. One of the main causes of nasal obstruction in children is the presence of nasal masses, which cause considerable diagnostic uncertainty in the medical team, because of their multiple etiologies. In this article, the case of a 10-month-old patient with a rapidly growing mass in the nasal ala is presented. A rhabdomyosarcoma was promptly diagnosed and adequately managed. Rhabdomyosarcoma with an alveolar pattern occurs in an unusual way in this location; for this reason, this case is important in order to include this possibility in the diagnostic algorithm and, as was the case in this patient, reach an early diagnosis and institute adequate treatment resulting in favorable aesthetic and functional results.

Introduction

Round and blue cell tumors account for close to 20% of solid organ tumors in the pediatric population. These tumors are very challenging, as they share several overlapping histologic findings. Immunohistochemistry is used to arrive at a specific diagnosis, considering that treatment changes considerably. In fact, the MRS LEEP mnemonics is used as a means to remember the diagnostic options as follows: melanoma, chondrosarcoma rhabdomyosarcoma, undifferentiated sinonasal carcinoma, squamous cell carcinoma, small cell osteosarcoma, lymphoma, esthesioneuroblastoma, Ewing, pituitary adenoma and plasmacytoma (1, 2).

In the pediatric population, malignant tumors in the nose and paranasal sinuses are a frequent cause of morbidity and mortality; however, there are some cases where a precise and timely diagnosis can increase the likelihood of favorable outcomes for the patient. The case of a patient with a fast-growing nasal mass properly diagnosed and referred to the relevant specialty is described in detail below.

Clinical case

Ten-month female patient without pathological antecedents, with a one-month history of a mass in the right nostril, showing rapid growth in the past two days and causing nasal ala deformity. No signs of dyspnea, epistaxis, weight loss, fever or any other symptom were found.

During the physical exam, a mass with a rigid and fibrous consistency was observed in the right nasal vestibule, arising from the nasal ala and infiltrating the ipsilateral nasal shed, with no bleeding stigmata and no abnormal findings in the oral cavity. Additionally, there was evidence of an 8 mm diameter lymph node enlargement which was palpable, mobile, painless, and non-adherent to the deep planes. Adenopathy located in the right cervical IIb region, which was mobile, painless and was not adhered to deep planes, was evident. No other abnormalities were found during the physical exam (Figure 1A).

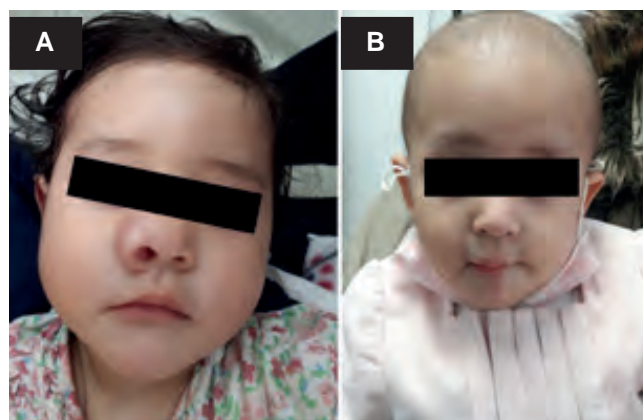

Figure 1. A. Right nasal ala mass, indurated, with partial obstruction of the lumen in the nasal vestibule. B. Total mass disappearance 8 months after chemotherapy with Vincristine and Cyclophosphamide. Image taken by the authors with parental consent.

Nasofibrolaryngoscopy (NFL) passing the lens fiber through the ipsilateral nostril due to 95% obstruction of the right nostril was attempted. No signs of tumor infiltration were found upon visualization of the right lower and middle turbinate. The rest of the nasal structures were within normal limits.

Contrast nasal and paranasal nuclear magnetic resonance (NMR) showed heterogenous uptake and a round-shaped mass with highly defined borders which did not infiltrate adjacent soft tissues (Figures 2A, B and C).

Basic staining study and report of endoscopic tissue biopsy obtained under general anesthesia showed a small, round, blue cell pattern (Figures 3A and B). The immunohistochemistry report showed strong and diffuse nuclear positivity with Mio D1, positivity in the desmin cell population with membrane pattern and CD56 positivity, and negative for CD99, CD45 and NSE tumor cell population.

The diagnosis made by Pathology and Otolaryngology corresponded to a Stage III right nostril rhabdomyosarcoma of alveolar variant (parameningeal location). Intermediate

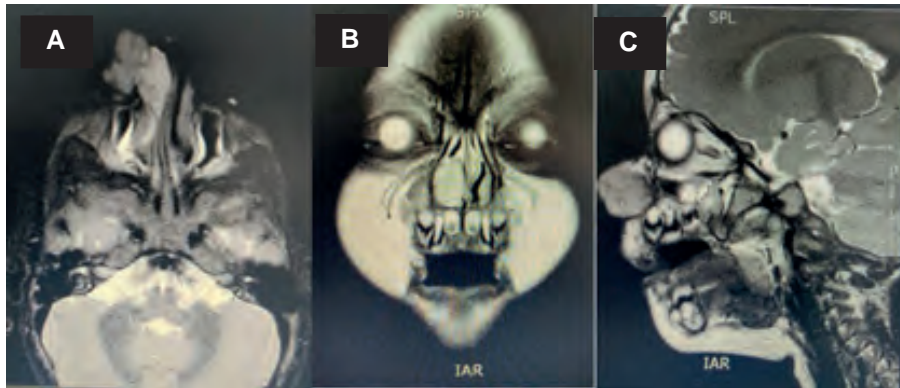


Figure 2. Nuclear magnetic resonance (NMR) of nose and paranasal sinuses A. T2 axial section with contrast. Mass in right nasal ala with heterogeneous density, complete lumen obstruction. B-C. Coronal and sagittal non-contrast T2-weighted image, respectively: well defined circumferential mass, approximately 15 x 9 x 12 mm, which displaces right lower turbinate but does not infiltrate it. Images obtained from the Misericordia Hospital system with parental consent.

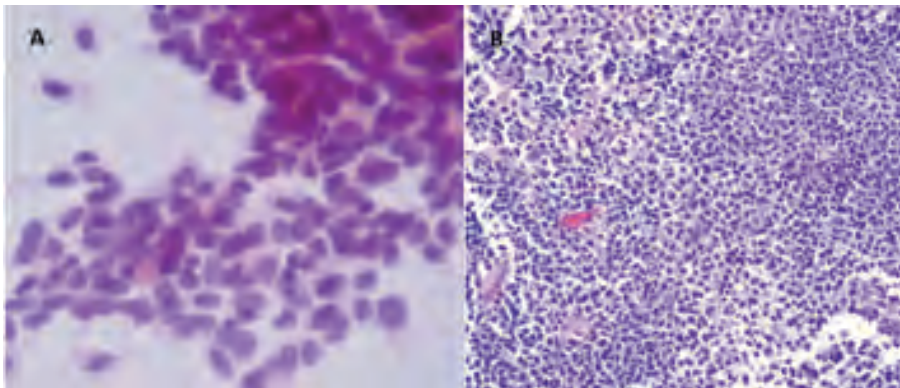


Figure 3. Typical histological pattern of small, round and blue cells. Taken from Surgical Pathology 10 (2017) 103-123.

risk. T1A (less than 5 cm), N1, M0 (bone marrow, CSF and chest CT without tumor compromise).

The patient was referred to the pediatric oncology service, which initiated the VAC chemotherapy protocol (Vincristine, Actinomycin and Cyclophosphamide) for 16 weeks. After eight months of treatment, the patient has shown a favorable course. Follow-up NFL control after six months of treatment showed macroscopic mass disappearance, with no signs of tumor recurrence (Figure 1B).

Discussion

One of the main causes of nasal obstruction in children is related to nasal masses that pose a significant diagnostic challenge to the medical team because of its multiple etiologies (3, 4). The most common benign tumors include teratomas, encephaloceles, gliomas, hemangiomas, chondromas and nasoangiofibromas, while the most common malignant lesion is rhabdomyosarcoma, followed by olfactory neuroblastoma and, lastly, unspecified sarcomas (5, 6).

Rhabdomyosarcomas account for 7% of malignant tumors in the pediatric population, with 40% being head and neck tumors, 50% of which arise in the nasal cavity and

paranasal sinuses (6-8). The nasal ala location is extremely rare and, when it occurs, the embryonic patron is the most common. The positive association of this pathology with Recklinghausen illness (10), Li-Fraumeni syndrome (11), Costello (12), Noonan (13) or Beckwith-Wiedemann suggest a relevant genetic component.

Histologically, the tumor is characterized by visualization of small cells with a hyperchromatic, rounded, dark blue nucleus with hematoxylin-eosin staining. Prognosis and management depend on stage and histological differentiation, with a survival rate for low-risk patients ranging between 85% and 95%; for intermediate risk lesions, the 4-year survival rate ranges between 73% to 68% and, finally, in the high risk group, the 3-year survival rate is 27% (15-17). In these patients, like in all cancer patients, a 5-year follow-up is recommended using contrast CT scan to show any type of tumor recurrence at an early stage.

Although genetic studies are far from being the regular diagnostic approach in our country, cytogenetic evaluation may aid in the diagnosis and subclassification of rhabdomyosarcomas. Embryonic rhabdomyosarcoma consistently demonstrates a loss of heterozygosity in chromosome 11p15.5. In addition, the majority of alveolar rhabdomyo-

sarcomas are associated with t(2;13)(q35;q14). A smaller number of alveolar rhabdomyosarcomas demonstrate t(1;13)(p36;q14) (18).

Conclusions

This case report provides additional tools to pediatricians and otolaryngologists, given the low prevalence of alveolar pattern rhabdomyosarcoma localizing to the nasal ala. Clinical suspicion and prompt diagnosis allowed early chemotherapy treatment initiation with good aesthetic and functional outcomes during the follow-up period. It is essential to know the steps to the diagnostic approach of a sinonasal mass, where the frozen biopsy and cytological imprinting can be useful tools to guide the diagnosis. Cytological analysis and immunohistochemistry are the diagnostic gold standard. Despite the aggressive nature and poor prognosis of this type of tumor, timely diagnosis leads to a better outcome.

Funding

Own resources.

Conflict of interest

The authors declare having no conflict of interest in relation to this article.

Ethical considerations

This article was written pursuant to the Helsinki Declaration adopted by the Eighteenth World Medical Assembly, Finland (1964).

Contribution

Olivera-Arenas MP: Writing and translation.

Romero-Pardo LF: Data collection after treatment, writing and translation.

Marrugo-Pardo GE: Data collection, references and conclusion

REFERENCIAS

- Miettinen M. Small round cell tumor. In: *Soft tissue tumors*. Philadelphia: Churchill-Livingston; 2003. p. 427-62.
- Bridge JA, Bowen JM, Smith RB. The small round blue cell tumors of the sinonasal area. *Head Neck Pathol*. 2010;4(1):84-93. doi: 10.1007/s12105-009-0158-6
- Gnagi SH, Schraff SA. Nasal obstruction in newborns. *Pediatr Clin North Am*. 2013;60(4):903-22. doi: 10.1016/j.pcl.2013.04.007
- Leboulanger N. Nasal obstruction in children. *Eur Ann Otorhinolaryngol Head Neck Dis*. 2016;133(3):183-6. doi: 10.1016/j.anorl.2015.09.011
- Kinshucka AJ, Clark RW. Nasal masses in children. *The Otorhinolaryngologist*. 2012;5(3):133-38.
- Chung SY, Unsal AA, Kılıç S, Baredes S, Liu JK, Eloy JA. Pediatric sinonasal malignancies: A population-based analysis. *Int J Pediatr Otorhinolaryngol*. 2017;98:97-102. doi: 10.1016/j.ijporl.2017.04.032
- Tanyous GH. Rhabdomyosarcoma of the nasal vestibule in a child. *Sultan Qaboos Univ Med J*. 2006;6(2):87-9.
- Hicks J, Flaitz C. Rhabdomyosarcoma of the head and neck in children. *Oral Oncol*. 2002;38(5):450-9. doi: 10.1016/s1368-8375(01)00105-1
- Radzikowska J, Kukwa W, Kukwa A, Czarnecka A, Krzeski A. Rhabdomyosarcoma of the head and neck in children. *Contemp Oncol (Pozn)*. 2015;19(2):98-107. doi: 10.5114/wo.2015.49158
- Sung L, Anderson JR, Arndt C, Raney RB, Meyer WH, Pappo AS. Neurofibromatosis in children with Rhabdomyosarcoma: a report from the Intergroup Rhabdomyosarcoma study IV. *J Pediatr*. 2004;144(5):666-8. doi: 10.1016/j.jpeds.2004.02.026
- Carnevale A, Lieberman E, Cárdenas R. Li-Fraumeni syndrome in pediatric patients with soft tissue sarcoma or osteosarcoma. *Arch Med Res*. 1997 Autumn;28(3):383-6.
- O'Neal JP, Ramdas J, Wood WE, Pellitteri PK. Parameningeal rhabdomyosarcoma in a patient with Costello syndrome. *J Pediatr Hematol Oncol*. 2004;26(6):389-92. doi: 10.1097/00043426-200406000-00012
- Jung A, Bechthold S, Pfluger T, Renner C, Ehrt O. Orbital rhabdomyosarcoma in Noonan syndrome. *J Pediatr Hematol Oncol*. 2003;25(4):330-2. doi: 10.1097/00043426-200304000-00014
- Smith AC, Squire JA, Thorner P, Zielenska M, Shuman C, Grant R, et al. Association of alveolar rhabdomyosarcoma with the Beckwith-Wiedemann syndrome. *Pediatr Dev Pathol*. 2001;4(6):550-8. doi: 10.1007/s10024001-0110-6
- Arndt CA. Risk stratification of rhabdomyosarcoma: a moving target. *Am Soc Clin Oncol Educ Book*. 2013:415-9. doi: 10.14694/EdBook_AM.2013.33.415
- Arndt CA, Stoner JA, Hawkins DS, Rodeberg DA, Hayes-Jordan AA, Paidas CN, et al. Vincristine, actinomycin, and cyclophosphamide compared with vincristine, actinomycin, and cyclophosphamide alternating with vincristine, topotecan, and cyclophosphamide for intermediate-risk rhabdomyosarcoma: children's oncology group study D9803. *J Clin Oncol*. 2009;27(31):5182-8. doi: 10.1200/JCO.2009.22.3768
- Oberlin O, Rey A, Lyden E, Bisogno G, Stevens MC, Meyer WH, et al. Prognostic factors in metastatic rhabdomyosarcomas: results of a pooled analysis from United States and European cooperative groups. *J Clin Oncol*. 2008;26(14):2384-9. doi: 10.1200/JCO.2007.14.7207
- Parham DM, Barr FG. Alveolar rhabdomyosarcoma. In: Fletcher CDM, Unni KK, Mertens F, eds. *Pathology and Genetics of Tumours of Soft Tissue and Bone*. Lyon: IARC Press; 2002. p. 150-52.