

De RSNA News\*

## Radiologists help uncover child abuse

\*Resúmenes enviados y publicados con autorización de la RSNA.

Radiology is very important in the discovery and documentation of child physical abuse. A report in the July-August issue of *RadioGraphics* will help diagnostic radiologists who are in the vanguard of detecting these injuries.

The report, "Child Abuse: Radiologic Pathologic Correlation," says about one percent of American children are subjected to some form of neglect or abuse, and inflicted injury is responsible for approximately 1,200 childhood deaths annually.

"Radiologists are asked to testify in court about whether or not injuries have been inflicted," says lead author Lt. Col. Gael J. Loneragan, M.D., formerly of the Armed Forces Institute of Pathology (AFIP). "I thought this review was something that should be put into the literature in an accessible format for general diagnostic radiologists."

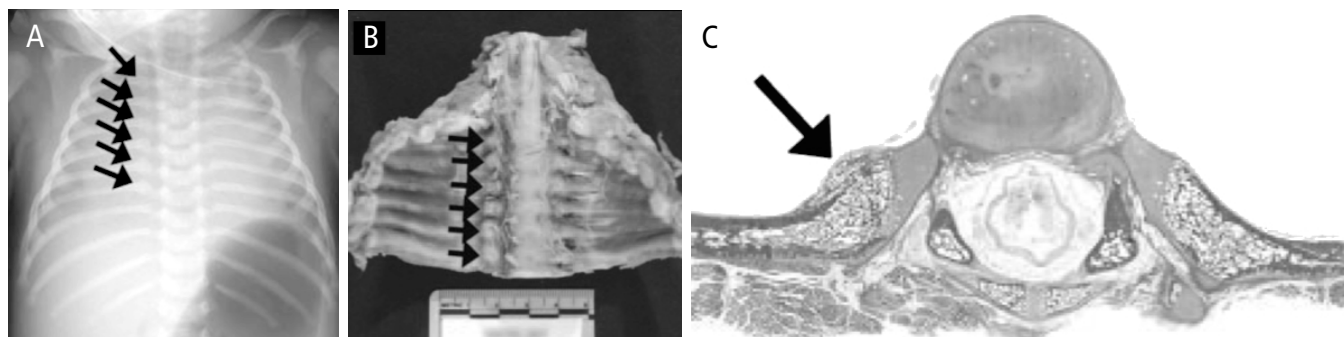
The report reviews the radiologic injury patterns commonly discovered in physically abused children, with special emphasis on the biomechanical forces that produce the injuries, their pathologic and radiologic appearance, and forensic implications of certain features of the injuries. The paper draws extensively on the pioneering work of pediatric radiologist Paul K. Kleinman, M.D., of Boston Children's Hospital.

"This is a complex topic. There's much more involved than just seeing the fracture," says Dr. Loneragan, who is now with the Austin Radiological Association in Texas. "For example, seeing a rib fracture and knowing what it means, what to infer about how it was caused, how forensically significant it is and determining legal ramifications are the important issues."

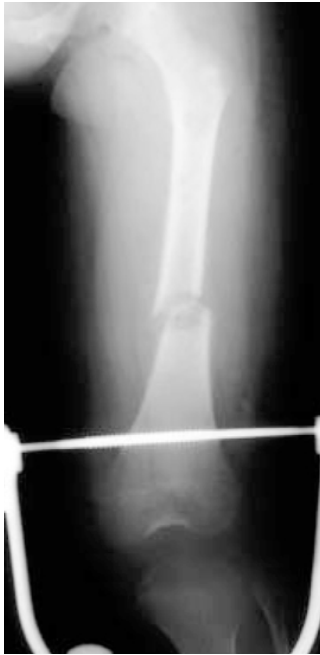In the report, the authors explain that child physical abuse may manifest as virtually any injury pattern known to medicine, "Worrisome injuries include rib fracture, metaphyseal fracture, interhemispheric extraaxial hemorrhage, sheartype brain injury, vertebral compression fracture and small bowel hematoma and laceration, among others." They also note that the vast majority of these injuries are readily detectable at imaging.

Multiple broken bones over a short period of time suggest physical abuse, as do injuries that are out of proportion to the reported trauma, according to Dr. Loneragan.

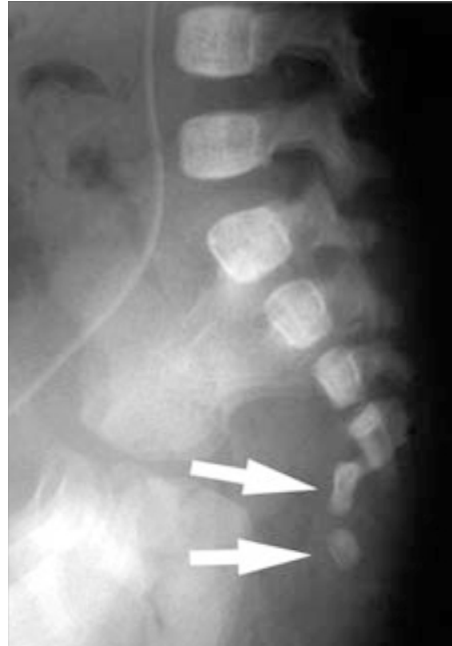"For example, imagine a child presenting with multiple severe abdominal contusions and the history given by care-



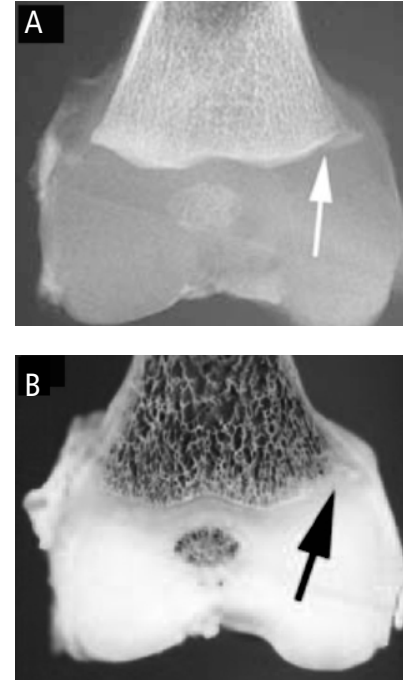
**Figure No. 1.** Acute lateral and healing posterior rib fractures in a fatally smothered seven week old boy. (A) Frontal chest radiograph of the deceased infant reveals widening of the posterior right third through eighth ribs (arrows). (B) Autopsy photograph of the resected chest cage shows healing posterior rib fractures (arrows), which are subtle but distinctly larger and more bulbous than the contralateral normal posterior ribs. (C) Axial photomicrograph (unmagnified, hematoxylineosin stain) of a rib fracture shows mineralized callus (arrow). (*RadioGraphics* 2003; 23:811845) Photographs and drawings ©RSNA. Printed with permission. A BC



**Figure No. 2.** Femoral shaft fracture in an abused five year old boy. Frontal radiography shows a transverse fracture of the diaphysis in femoral pin traction. The mother's boyfriend confessed to pushing a television cabinet on top of the boy.



**Figure No. 3.** Sacral fracture dislocation in an abused two month old girl. Lateral radiograph depicts a fracture between the fourth and fifth vertebrae, through the intervertebral disk space. The fifth sacral vertebra and coccyx (arrows) are anteriorly displaced. The injury was originally explained as resulting from a changing table fall; the mother's boyfriend later confessed to slamming the child down in a sitting position.



**Figure No. 4.** Subacute CML in a fatally abused seven week old boy. (A) Specimen radiograph of the distal femur (overlying soft tissue removed) shows irregular lucency of the medial femoral metaphysis (arrow). (B) Photograph of the fixed, bivalved femur shows physeal cartilage extension into the metaphysis (arrow).

takers is that they were in a minor fenderbender type of auto accident. That raises suspicion," she says. "Classic metaphyseal lesions are discovered in up to half of abused children less Lt. Col. Gael J. Lonergan, M.D. than 18 months of age. In addition to skeletal injuries, the article details the pathologic and radiologic characteristics of visceral and central nervous system injuries. Among these, nonaccidental head injury is the leading cause of morbidity and mortality in battered children."

Dr. Lonergan says some of the most frustrating barriers to injury evaluation become apparent during the evaluations of children who die unexplained or unexpected deaths. As part of the autopsy, radiographs may be obtained, though they usually are images of large areas of the body or even the whole body of a small child. These images are known as babygrams.

"Medical examiners rely on babygrams done in the morgue that are not typically seen by radiologists," says Dr. Lonergan. "While babygrams may be adequate to detect a bullet or major bone fracture, they are inadequate for the detection of subtle injuries of abuse such as classic metaphyseal lesion (CML) and rib fracture."

She says that a skeletal survey—a full set of high-resolution films—should be more widely used in suspicious

cases; however, skeletal surveys may place an economic or logistical hardship on medical examiners who have limited resources and limited or no access to radiologists or radiologic technologists to perform imaging studies and interpret the results.

"If you do get a film in a medical examiner's office it's usually going to be a babygram and it's usually going to be read by the pathologist doing the autopsy," Dr. Lonergan says. "This constitutes a big hole in the system."

In addition, metaphyses are not routinely evaluated at autopsy. "Detection of CML, regarded as the most specific radiographically detectable injury in abuse, depends on high quality, small field-of-view films," she says. "In Dr. Kleinman's landmark study of postmortem imaging, fully 93 percent of infants dying suspicious deaths had evidence of older, highly abusespecific injuries detected radiographically."

The Society for Pediatric Radiology is developing a position paper in conjunction with the National Association of Medical Examiners to outline the optimal radiologic evaluation of suspicious infant deaths and facilitate radiologic assistance as part of the complete autopsy.

The authors of the RadioGraphics article write, "Careful observation of radiologic findings and their correlation with the proposed mechanism of injury and with the developmental ca-

pabilities and clinical status of the child are imperative in the evaluation of any child, lest we overlook an important clue to

the inflicted nature of an injury and return a child to an abusive environment, with potentially disastrous consequences.”

#### **CT or MR Imaging Recommended for Certain Abuse Cases**

A STUDY IN THE JUNE 2003 issue of *Pediatrics* supports a recommendation for universal screening in neurologically asymptomatic abused children with certain highrisk criteria— particularly if that child is under one year of age. Of the 51 patients in the study who met the criteria and who also underwent CT or MR imaging, the researchers found that 19 children (37.3 percent) had an occult head injury. Skeletal survey alone missed five out of those 19 cases. The abstract for this study is available at [pediatrics.aappublications.org/cgi/content/abstract/111/6/1382](http://pediatrics.aappublications.org/cgi/content/abstract/111/6/1382). Classic metaphyseal lesions are discovered in up to half of abused children less than 18 months of age. — Lt. Col. Gael J. Lonergan, M.D.

Editor's Note: The full text of the *RadioGraphics* article is online and free to RSNA members and subscribers at [radiographics.rsna.org/current.shtml](http://radiographics.rsna.org/current.shtml). Click on AFIP articles, then the Full Text link next to the Lonergan article.

## **Education Innovations Drive New Course Series at RSNA 2003**

Radiologists attending RSNA 2003 will be able to participate in an exciting new refresher course series—Case-based Review courses.

Unlike any other courses offered during the annual scientific assembly, these Case-based Review courses will each be held on a single day, in a problem based interactive format.

“The problem for many RSNA registrants is that they can't stay the whole week at the meeting,” says Robert A. Novelline, M.D., vicechairman of the RSNA Refresher Course Committee. “They can only spend a couple of days in Chicago and then they have to return home so that their colleagues can attend for a few days.”

While ease of scheduling is an important consideration for attendees, they also want to be challenged and stimulated. That's exactly what will happen during the Casebased Review courses.

“Interactive teaching is a direction that is considered very popular today and an excellent way to teach. This is RSNA's first major experiment in Refresher Course interactive teaching,” says Dr. Novelline, who is also a professor of radiology at Harvard Medical School and director of emergency radiology and undergraduate radiology at Massachusetts General Hospital in Boston.

“In each session, there will be a preliminary introduction, the instructor will show unknown cases and then the audience will have to solve the cases and answer questions,” explains Dr. Novelline. “Audience members will have electronic controls. After the case is presented and the questions are asked, each person can respond.”

The instructor will know immediately the percentage of people who got the question right and the percentage of people who got the question wrong. The instructor can then alter the remainder of the teaching based on the understanding of the audience for each of the questions being asked.

Case-based Review courses will be offered in three subspecialties during RSNA 2003—neuroradiology on Monday,

vascular/interventional radiology on Tuesday and pediatric radiology on Wednesday. Registration for courses began June 23 and will continue until each course is full.

Dr. Novelline, Refresher Course Committee Chairman Ronald J. Zagoria, M.D., and RSNA staff met with the leadership of the three related subspecialty societies, Society of Interventional Radiology, American Society of Neuroradiology and Society for Pediatric Radiology, to get their suggestions for course directors and curriculum.

“The benefits of attending this course are that a registrant can complete it in one day, it will be in a much more thoughtprovoking format than listening to a lecture, and it will be taught by a superb faculty in a challenging problem based fashion,” says Dr. Novelline.

#### **Essentials of Radiology**

Last year was the first time RSNA offered the Essentials of Radiology refresher course series. The series so popular, it will be offered again this year.

“We anticipated a few hundred people might come to each session, but we soon had to move the courses into rooms accommodating 1,100 people—and we still had to turn people away,” says Dr. Zagoria, a professor and vice-chairman for medical affairs, and section head of abdominal imaging at Wake Forest University Baptist Medical Center in North Carolina. “This year, we are again seeing strong registration for the Essentials courses.”

The Essentials series provides 90 minute courses in eight subspecialties over a two day period. The course block includes sessions on imaging of the breast, chest, liver, shoulder, pediatrics, trauma, ultrasound and uroradiology.

“In a concentrated period, you can be exposed to some of the best speakers in the world who are experts in their topics and get a broad review course on general radiology,” says Dr. Zagoria. “The most popular part of the RSNA meeting is the refresher courses. Having the Case-based Review courses and the Essentials of Radiology courses in a concentrated format makes them even more popular.”

New this year, attendees can sign up for single Essentials courses, rather than the entire block of courses.

If you have already registered for RSNA 2003, you may register for refresher courses at [www.rsna.org/register](http://www.rsna.org/register).

Click on Refresher Course Enrollment, enter your meeting confirmation number and then enter your selections. If you have not yet registered for RSNA 2003.

The benefits of attending this course are that a registrant can complete it in one day, it will be in a much more thought provoking format than listening to a lecture, and it will be taught by a superb faculty in a challenging problem-based fashion

—Robert A. Novelline, M.D.

CME credit at RSNA 2003 will be recognized by the European Accreditation Council for CME (EACCME). This will be on an hour by hour basis. RSNA works closely with the American Medical Association and has met the requirements by which it can award category 1 credits to international attendees that will be accepted by the EACCME. Radiologic Technologists and others requiring technologist continuing education (CE) credit should indicate their need for CE credit at the time of registration.

### CASE-BASED REVIEW COURSES

Monday, December 1  
**Neuroradiology**  
8:30 a.m. – 5:45 p.m.

Tuesday, December 2  
**Interventional Radiology**  
8:30 a.m. – 6:00 p.m.

Wednesday, December 3  
**Pediatric Radiology**  
8:30 a.m. – 5:00 p.m.

**ESSENTIALS OF RADIOLOGY**  
Tuesday, December 2

**Essentials of Ultrasound Imaging**  
8:30 a.m. – 10:00 a.m.

**Essentials of Pediatric Imaging**  
10:30 a.m. – 12:00 p.m.

**Essentials of Chest Radiology**  
1:00 p.m. – 2:30 p.m.

**Essentials of Shoulder Imaging**  
2:45 p.m. – 4:15 p.m.

Wednesday, December 3  
**Essentials of Liver Imaging**  
8:30 a.m. – 10:00 a.m.

**Essentials of Uroradiology**  
10:30 a.m. – 12:00 p.m.

**Essentials of Trauma CT**  
1:00 p.m. – 2:30 p.m.

**Essentials of Breast Imaging**  
2:45 p.m. – 4:15 p.m.

### Did you know?

WHILE RSNA AND MOST RADIOLOGISTS commonly use the term continuing medical education (CME), the professional medical world is now using the term continuing professional development (CPD).

CME programs are actually a subcategory of CPD. The concept is one of continuous self-improvement where physicians are continually assessing what they know and how they are practicing and seeking out new knowledge and training to strengthen themselves in various areas. The AMA officially changed its terminology from CME to CPD a few years ago. Canadians have also been using CPD for a few years.