

Enrique Palacios MD, FACR,<sup>1</sup>  
Giovanni Larusso MD,  
Rafael Rojas MD,  
Irina Gonzalez MD,  
Guadalupe Ramírez MD

## Lymphoma of the parotid gland in Sjögren's syndrome

### RESUMEN

**Introducción:** El síndrome de Sjögren es una enfermedad crónica autoinmune, manifestada por infiltración linfocítica de las glándulas exocrinas, particularmente de las glándulas lacrimales y salivales.

**Metodología:** Se presenta un caso de mujer de 60 años

con desarrollo lento y progresivo de ojos y boca seca. Se identificó un aumento de volumen de partes blandas en el área de las parótidas. Una TC reveló la apariencia nodular de ambas glándulas parótidas.

**Conclusiones:** La TC y la IRM pueden demostrar los hallazgos descritos en el Sx de Sjögren. Las glándulas saliva-

les se observan con apariencia nodular, lo que representa colecciones globulares. Estos hallazgos no son específicos.

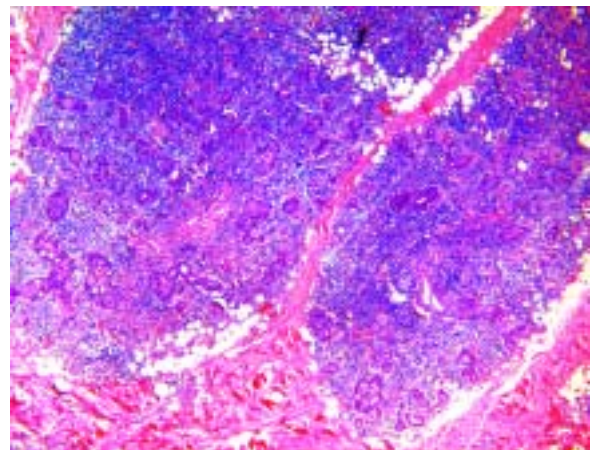
**Palabras clave:** Síndrome de Sjögren, TC, glándula parótida.

*continúa en la pág. 56*

<sup>1</sup> From the Department of Radiology, Louisiana State University, Health Science Center, 1542 Tulane Av., Room 303, New Orleans, LA 70112, USA.  
Copias (copies): Enrique Palacios MD, FACR. E-mail: dipalacios@aol.com

Sjögren's syndrome is a chronic auto immune disorder manifested by lymphocytic infiltration of the exocrine glands, particularly the salivary and lacrimal glands. The sicca complex of xerostomia and keratoconjunctivitis is the hallmark of Sjögren's syndrome.<sup>1</sup> Its association with lymphoma is well documented and is a severe complication of primary Sjögren's syndrome, occurring in 5-10% of the patients followed for more than 10 years.<sup>2,3</sup> Lymphomas developing in Sjögren's syndrome are classified as MALT (mucosa-associated lymphoid tissue) lymphomas, which can be furthered subclassified as either low or high grade.<sup>4</sup> Our case is that of a 60 year-old female with insidious slowly progressive development of dry eyes and mouth. There was no evidence of underlying rheumatoid arthritis. Clinically, a soft tissue mass was identified in the parotid area. A Computed Tomography (CT) examination at the level of the parotid glands revealed a nodular appearance of both parotid glands, indicating dilatation of the acini. Also noted was a low-density soft tissue mass in the right parotid gland that measured approximately three centimeters at its greater diameter, which histologically proved to be a lymphoma (*Figures 1, 2 and 3*). The pathophysiology of lymphoma in Sjögren's syndrome remains unknown. To date, there is no argument

favoring a viral infection or deregulation of a unique oncogene or antioncogene.<sup>2</sup> CT and MR can demonstrate findings consistent with Sjögren's syndrome. The parotid glands reveal a punctate or nodular appearance representing globular collections. These findings, however, are non-specific as they can be seen in chronic sialoadenitis and granulomatous diseases.<sup>4</sup> A 60-year-old man presented complaining of a painful palatal ulcer that had been present for 6-8 months. Review of systems revealed a 3 year history of xerostomia and xerophthalmia requiring frequent use of lubricating eye drops and artificial saliva. He had a 20-pound



**Figure 1.** H&E stain, original magnification 40x.



## ABSTRACT

**Introduction:** Sjögren's Syndrome is a chronic auto immune disorder manifested by lymphocytic infiltration of the exocrine glands, particularly the salivary and lacrimal glands.

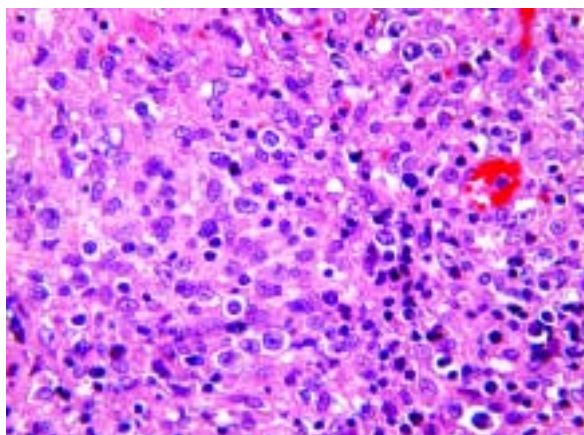
**Methodology:** Our case is that of a 60 year-old female with

insidious slowly progressive development of dry eyes and mouth. A soft tissue mass was identified in the parotid area. A Computed Tomography (CT) examination revealed a nodular appearance of both parotid glands.

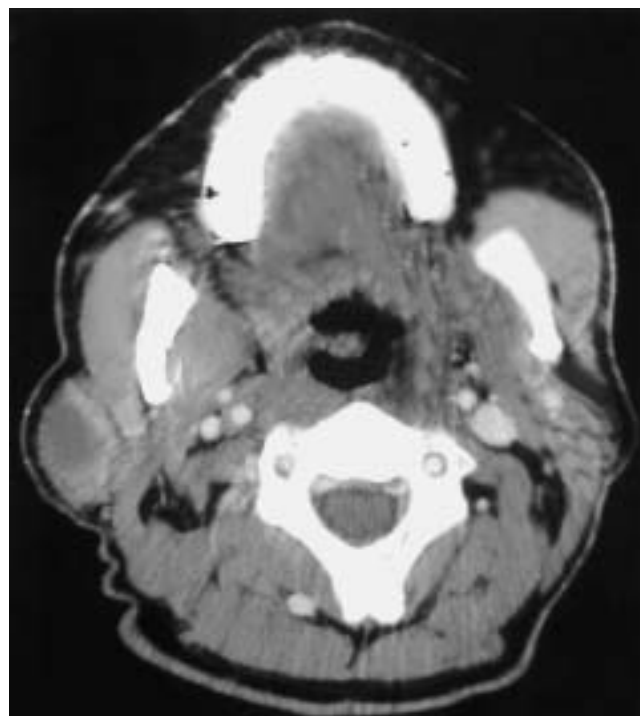
**Conclusions:** CT and MR can demonstrate findings consis-

tent with Sjögren's syndrome. The parotid glands reveal a punctate or nodular appearance representing globular collections. These findings are non-specific.

**Key words:** Sjögren's syndrome, CT, parotid gland.



**Figure 2.** H&E stain, original magnification 400x.



**Figure 3.** CT axial sections post-contrast at the level of the parotid glands revealed a punctate and nodular appearance representing globular collections in both parotid glands (arrow) (A). In another section, a low-density soft tissue mass is identified on the right (arrow) (B).

There were also foci of necrosis and a monotonous proliferation of larger, atypical lymphocytes. Immunohistochemical staining confirmed and extranodal marginal zone lymphoma with areas suspicious for B-cell transformation (Figure 2).

loss of weight over the prior three months, general malaise, nonproductive cough, and afternoon fevers. He denied night sweats, hematochezia, melena, or hematemesis.

Physical examination showed a 2-cm nodule in the tail of the right parotid. A deep palatal ulcer with undermining and gray exudates was present and a second ulcer was noted on the upper left gum adjacent to the incisor.

A chest X-ray showed multiple bilateral parenchymal nodules, suspicious for neoplasm.

Biopsy of the palate ulcer revealed only acute and chronic inflammation but no evidence of malignancy.

Right parotidectomy was performed. Microscopic examination showed a diffuse lymphohistiocytic infiltrate between islands of glandular epithelial cells. Areas of fibrosis were noted. This form of chronic sialadenitis is consistent with Sjögren's syndrome (Figure 1).



## CME Question

Which of the following statements are true as they relate to lymphoma in Sjögren's syndrome:

- (A) Five to ten percent of patients with Sjögren's syndrome followed for more than 10 years will develop lymphoma.
- (B) Lymphomas developing in Sjögren's syndrome maybe classified as MALT (mucosa-associated lymphoid tissue) lymphomas.
- (C) Lymphoma may appear as a low-density mass in a parotid gland with punctate and nodular appearance representing globular collections.
- (D) All of the above

Answer: **(D)** All of the above

## References

1. Sjögren's syndrome. In: Primer on the rheumatic diseases. Schumacher Jr. HR (Ed.). 9th Ed. Atlanta, GA: Arthritis Foundation; 1988, p. 136-8.
2. Mariette X. Gougerot-Sjögren syndrome. risk of lymphoma. Presse Med 1999; 19; 28(22): 1214-8.
3. Voulgarelis M, Moutsopoulos HM. Lymphoproliferation in autoimmunity and Sjögren's syndrome. Curr Rheumatol Rep 2003; 5(4): 317-23.
4. Som PM, Brandwein MS. Salivary Glands. Anatomy and Pathology. In: Som PM, Curtin HD (eds.) Head and Neck Imaging. Chapter 39. Vol. 2. 4th Ed. St. Louis: Mosby; 2003, p. 2005-133.