

Enrique Palacios MD FACR,<sup>1</sup>  
Rafael Rojas Jasso MD,  
Santiago Restrepo,  
Giovanni D. Lorusso MD,  
Luciano Mastrogianni

# Sinonasal hemangiopericytomas. Clinicopathological and Imaging Findings

## ABSTRACT

**Introduction:** Hemangiopericytomas (HPC), vascular tumors, are probably originated of contractile smooth cells modified of the muscle in the external surface of posthair capillaries and venules. Hemangiopericytomas sinonasales (SNHPC) behaves less aggressively than the HPC that happen in other regions of the body.

**Material and methods:** Seven proven cases of sinonasal HPC are reviewed, studied through 12 years in five diverse institutions of EUA and Colom-

bia. The group was compound of four male and three female patients, with ages average of 50 years (of between 23 to 60 years). For their study, images of computerized tomography (CT) and magnetic resonance were used (MR). The etiology is unknown, nevertheless, has been related to trauma, treatment long term steroid, pregnancy and hypertension, but no of them has been proven.

**Conclusion and discussion:** One describes to the clinical projection of image and the pathological evaluations of the seven cases. Also is the surgi-

cal behavior. Most of the patients they presented epistaxis chronic and nasal obstruction. The evaluation of the projection of image with CT and SR turned out essential to determine the extension of the tumor to plan the surgery.

**Key words:** Hemangiopericytomas (HPC), sinonasal hemangiopericytomas, nasopharyngeal angiofibroma, epistaxis.

*continúa en la pág. 334*

<sup>1</sup>From Louisiana State University Health Sciences Center New Orleans, Louisiana. 1542 Tulane Avenue, New Orleans, Louisiana 70112.  
Copias (copies): Dr. Enrique Palacios E-mail: epalac@lsuhsc.edu

## Introduction

Hemangiopericytomas (HPC) are unusual vascular tumors, first described by Stout and Murray in 1942.<sup>1</sup> These tumors originate from the pericytes, which presumably are modified contractile smooth muscle cells found on the external surface of capillaries and postcapillary venules.<sup>2,3</sup> HPC represent 3% of all soft tissue sarcomas and 1% of all vascular tumors. They can arise any place where capillaries are found, primarily in the lower extremities and retroperitoneum.<sup>3-6</sup> Approximately 15% to 25% of all HPCs occur in the head and neck area and less than 5% arise from the sinonasal cavity.<sup>5-9</sup> Sinonasal hemangiopericytomas (SNHPCs) are thought to behave less aggressively than hemangiopericytomas occurring in

other body regions and there is a 5-year survival rate of approximately 88%.<sup>6,8,10</sup>

## Materials and Methods

Seven cases of sinonasal HPC were identified over a period of 12 years from five different institutions (Loyola University of Chicago, Maywood, Illinois; Mac Neal Hospital, Berwyn, Illinois, Louisiana State University Health Sciences Center, New Orleans, Louisiana and Fundación Santa Fe de Bogotá, Bogotá, Colombia). Clinical, pathological and imaging examinations, including Computed Tomography (CT) and Magnetic Resonance (MR) were retrospectively reviewed. All of the cases were histologically proven.

## Case reports

### Case 1

A Sixty-year-old male with a two-year-history intermittent epistaxis. CT revealed a well-marginated soft tissue mass in the superior portion of the right ethmoid sinus. The tumor extended into the right cribriform plate (*Figure*

## RESUMEN

**Introducción:** Los hemangiopericitomas (HPC), tumores vasculares, se originan probablemente de células lisas contráctiles modificadas del músculo en la superficie externa de tubos capilares y vénulas post-capilares. Los hemangiopericitomas sinusales (SNHPC) se comportan menos agresivamente que los HPC que ocurren en otras regiones del cuerpo.

**Material y métodos:** Se revisan siete casos probados de

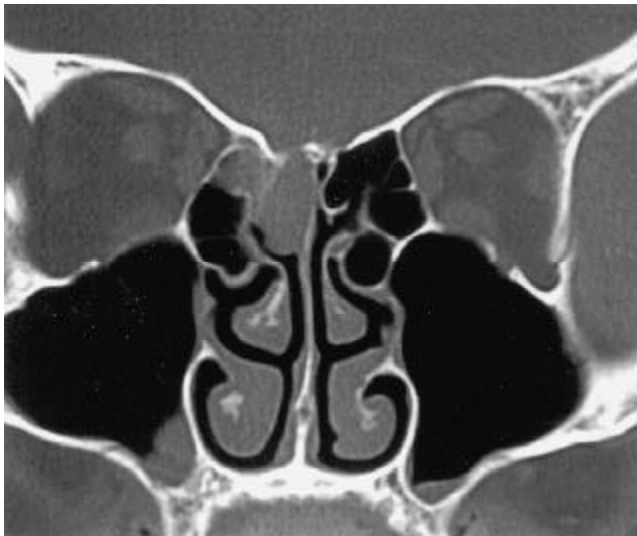HPC sinusal, estudiados a través de 12 años en cinco diversas instituciones de EUA y Colombia. El grupo de pacientes estaba compuesto de cuatro varones y tres mujeres, con edades promedio de 50 años. Para su estudio, se utilizaron imágenes de tomografía computarizada (CT) y de resonancia magnética (MR).

La etiología es desconocida, sin embargo, se ha relacionado con trauma, tratamiento esteroide a largo plazo, embarazo e hipertensión, pero ninguno de ellos ha sido probado.

**Conclusión y discusión:** Se describe la proyección clíni-

ca de imagen y las evaluaciones histológicas de los siete casos. También se muestra el comportamiento quirúrgico. La mayoría de los pacientes presentaron epistaxis crónica y obstrucción nasal. La evaluación de la proyección de imagen con CT y MR resultó esencial para determinar la extensión del tumor para planear la cirugía.

**Palabras clave:** Hemangiopericitomas (HPC), hemangiopericitomas sinusales (SNHPC), angiofibroma nasofaríngeo, epistaxis.



**Figure 1.** Unenhanced coronal CT exam reveals a well-marginated soft tissue mass in the superior portion of the right ethmoid sinus. The tumor extends and erodes the right cribriform plate.

1). The patient underwent endoscopic surgery with complete removal of an HPC in the right ethmoid area. A CSF leak developed that was repaired intraoperatively. At 22 months post surgery, the patient was asymptomatic.

### Case 2

A 35-year-old female with complaints of intermittent nasal obstruction on the left and epistaxis. MR revealed a soft tissue mass in the nasal cavity on the left (*Figure*

2). A complete surgical resection of the mass was performed.

### Case 3

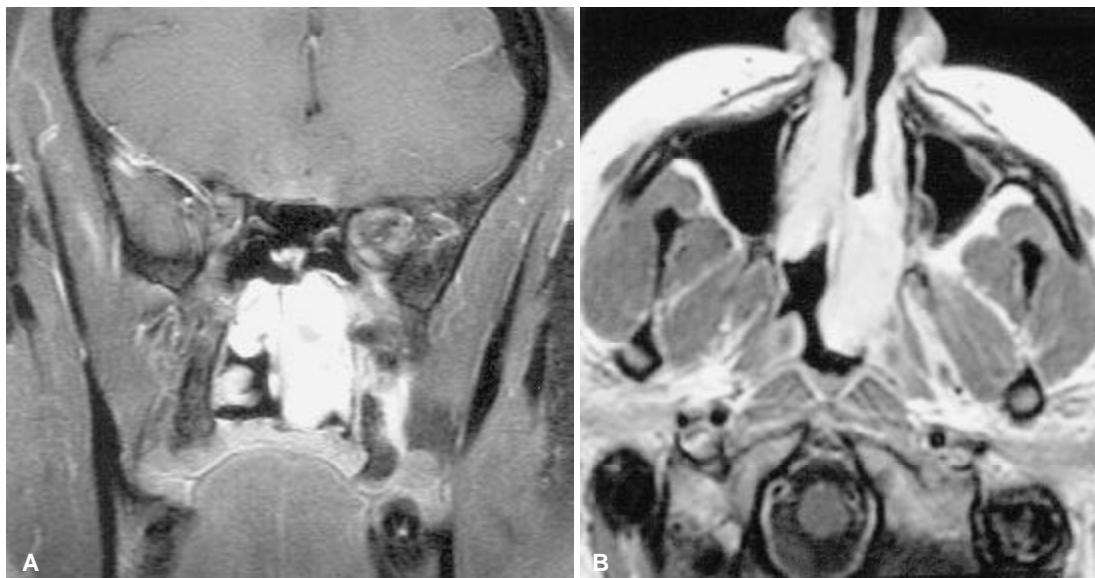
A 66-year-old male with a history of a "nasopharyngeal angiofibroma", resected 16 years earlier complained of nasal obstruction, pain in the nasal and malar area and epistaxis. A large nasal soft tissue mass was identified and it proved to be a SNHPC. Following preoperative embolization, the mass was partially removed surgically. Follow-up CT and MR examinations two years later revealed the recurrence of a large tumor (*Figure 3*) that was partially resected and treated with embolization and radiation therapy.

### Case 4

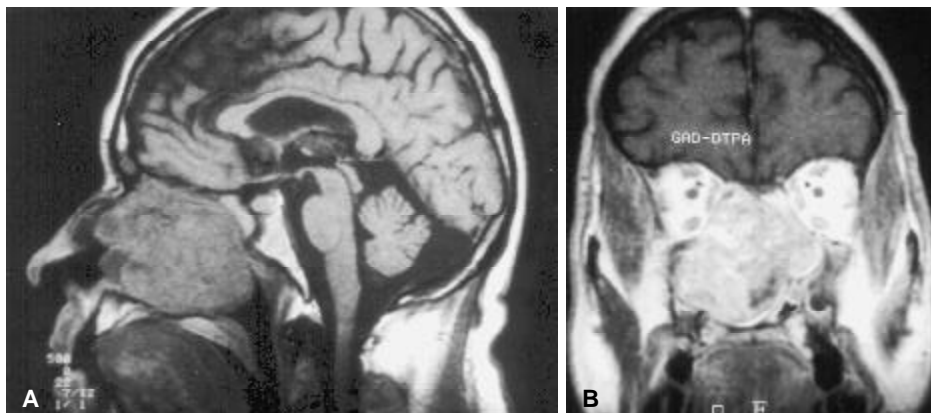
A 23-year-old female had a six-month history of persistent and generalized headaches and occasional bouts of spontaneous decrease in visual acuity of the right eye. In light of the progression of the symptoms, CT and MR examinations were performed revealing a sphenoidal mass extending into the sella and cavernous sinuses (*Figure 4*). The lesion was partially resected surgically and treated with radiation. The patient remained with persistent neurological deficits; however, there was no obvious evidence of recurrence.

### Case 5

A 64-year-old male presented with a history of chronic intermittent epistaxis and nasal obstruction.



**Figures 2.** MR T1-Weighted post-contrast images (A) Coronal and (B) axial coronal reveal a marked enhancement of the soft tissue mass in the left nasal cavity.



**Figures 3.** (A) MR non-contrast sagittal T1 Weighted image reveals a large expansive soft tissue mass in the nasal cavity destroying the turbinates and nasal septum, extending into the ethmoid sinuses. (B) MR coronal T1 Weighted post-contrast image showing a large enhancing mass extending superiorly into the ethmoid sinus, laterally into the maxillary sinuses and inferiorly into the oral cavity.

A soft tissue mass extending into the left ethmoid sinus (not shown) was identified on CT. Complete resection of the mass was performed endoscopically. There was no evidence of recurrence three years later.

#### Case 6

A 48-year-old female presented with a left nasopharyngeal mass and multiple cranial nerve involvement on the left (III-IV-V). On CT, a mass (not shown) extended into the nasal cavity and left parasellar area. The lesion was surgically resected, however, there was recurrence of the mass and symptoms 8 years later.

#### Case 7

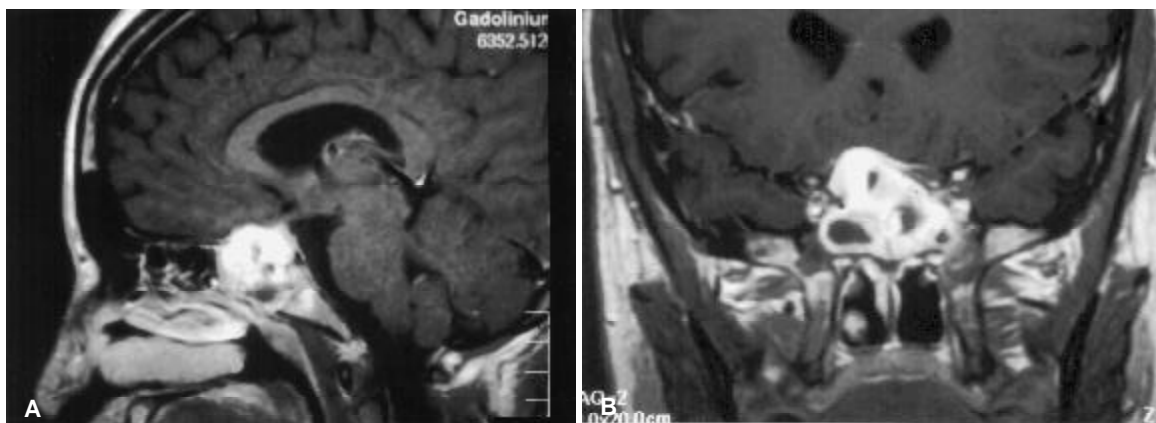
A 58-year-old male complained of nasal obstruction. On CT, a soft tissue mass in the posterior nasal cavity was identified extending into the nasopharynx (not shown). The mass was surgically resected and after 4 years, there was no evidence of recurrence.

## Results

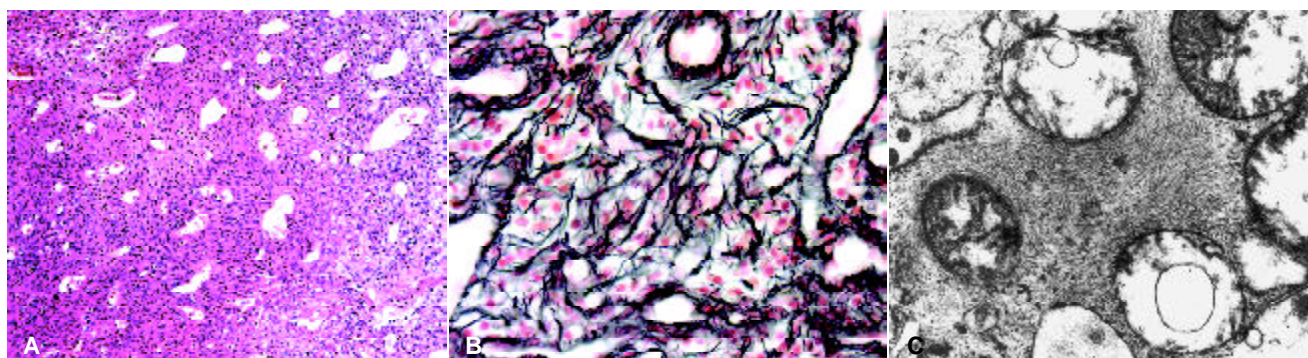
In our group of 7 patients, there were 4 males and 3 females. The ages ranged from 23 to 60 years, with an average age of 50. The patients were evaluated clinically and imaged with Computed Tomography (CT) in all 7 cases and Magnetic Resonance (MR) in 2 cases. Three cases out of the seven had ethmoid sinus involvement. One case involved the sphenoid sinus, with extension into the sellar area, cavernous sinus and optic chiasm. Four patients had involvement of the nasal cavity and 2 had nasopharyngeal extension. Two year after surgical removal of an HPC, one case had a recurrence of the tumor with extension to the ethmoid, sphenoid, maxillary sinuses, as well as to the nasopharyngeal area.

## Discussion

SNHPC affects middle age patients and presents an equal gender distribution.<sup>3-6,9</sup> The etiology is unknown, however, it has been related to trauma, long-term steroid treatment, pregnancy and hypertension, but none



**Figures 4.** MR contrast enhanced coronal T1-Weighted images. **(A)** Sagittal and **(B)** coronal sections demonstrate an inhomogeneous enhancing mass within the sphenoid sinus extending into the pituitary fossa compromising the optic chiasm. Hypointense areas are noted indicating necrotic portions within the tumor.



**Figure 5.** **(A)** H&E stain 20x. A highly vascularized cellular tumor composed of numerous thin walled vessels surrounded by abundant oval or spindle cells. **(B)** Reticulin stain 40x. Reticulin surrounds each individual tumor cell. **(C)** Electron Micrograph 50.000x reveal ed thin cytoplasmic filaments.

of them have been proven.<sup>5,6,8,9</sup> Occurrence in the nasal cavity is approximately twice as common as in the paranasal sinuses. The ethmoid and sphenoid sinuses are involved four times more often than maxillary sinuses.<sup>5,6</sup> Endoscopically, these tumors in the nasal cavity are described as soft and tan colored.<sup>6,8</sup> Due to their gradual expansion, the lesion leads to nasal and sinus obstruction. Spontaneous or induced bleeding and impaired nasal breathing occurs months or years preceding diagnosis.<sup>5-7</sup> Ophthalmologic findings, including, proptosis, cranial nerve involvement with visual loss may be present when the orbits and intracranial structures are invaded.<sup>7,11</sup>

The lesion typically enlarges slowly over a period of years and may suggest a benign process.<sup>7</sup> An expansible growth with smooth borders is more common than infiltration into the surrounding tissues. A diagnosis cannot be made based on clinical or gross morphologic characteristics, but is dependent on careful histologic examination and reticulum staining.<sup>5</sup>

Biopsies should be performed carefully due to the high risk of bleeding.<sup>12</sup>

### Pathology

It is believed by some that SNHPC represent a different type of tumor than HPCs arising from other areas.<sup>13,14</sup> The tumor is composed uniform, ovoid or spindle cells, forming tight aggregates with little intervening collagenous stroma.<sup>15</sup> Mitoses are rare and necrosis is absent. The vasculature is dilated with "staghorn" like vascular spaces. The neoplastic cells do not stain for epithelial, melanocytic or neural markers.

The presence of positive staining for cytokeratin excludes the diagnosis of HPC. The tumor cells are typically positive for Vimentin (98%) and smooth muscle actin (92%) stains.<sup>10</sup> Special stains for reticulin show positivity surrounding individual tumor cells throughout the entire tumor. Some features suggest pericytic differentiation by electron microscopy, revealing thin cytoplasmic filaments,



as well as pinocytic vesicles<sup>14</sup> Figure 5 demonstrates the pathological findings in cases 1 and 2.

### Imaging features

Plain radiographs of the sinonasal area are of limited diagnostic value, however, they may suggest the presence of a space-occupying lesion with mass effect that distorts the adjacent bony structures.<sup>4</sup> CT clearly demonstrates soft tissue mass involvement of the nasal cavity or paranasal sinuses that may enhance after intravenous contrast administration.<sup>6,16</sup> If the lesion is large, bone destruction of the nasal cavity or paranasal sinuses and adjacent orbital and intracranial structures can be clearly demonstrated on CT.<sup>11</sup> On MR imaging, SNHPC are seen as solid masses with isointense signal intensity on T1-WI and iso-low signal intensity on T2-WI, with diffuse enhancement after intravenous administration of gadolinium on T1-WI.<sup>6,16</sup> On postcontrast MR studies, inflammation of the adjacent normal mucosa adjacent to the tumor may sometimes enhance, leading to an overestimation of the tumor size and extension.<sup>6</sup> MR is also of value to differentiate inflammatory fluid caused by sinus obstruction from tumor tissue. Contrast enhanced MR is the best method to demonstrate tumor extension to the base of the skull.<sup>4,6,7,11,16</sup> Vascular signal flow voids in cases of highly vascularized tumors may also be seen on MR.<sup>7</sup> Conventional digital angiography may be the best method for demonstrating the vascular supply to the tumor to determine and to plan preoperative embolization.<sup>6,9,16</sup> Imaging findings of SNHPC may be non-specific and should be differentiated from other tumors involving the sinonasal area, such as, esthesioneuroblastoma, ade-

noid cystic and squamous cell carcinomas and nasopharyngeal angiofibroma, among others.<sup>8,9</sup>

### Management

A wide local excision is the treatment of choice, however, adequate negative surgical margins are usually difficult in the sinonasal region.<sup>5,7,8</sup> Endoscopic resection might be adequate if the lesion is small and the site of origin is well identified.<sup>7</sup> A craniofacial approach will be necessary if the cribriform plate or the base of the skull is breached.<sup>4</sup> While radiation therapy has been used for palliation or as adjuvant treatment, it is not clear whether it leads to improvement in survival when compared to surgery alone.<sup>5-7</sup> In general, HPC manifest a metastatic rate ranging from 12- 60%, affecting primarily the lungs and skeleton. SNHPC present a lower metastatic rate of only 5-10%.<sup>5,6,16</sup> Recurrence has been noted to precede the development of metastasis.<sup>5,8</sup> The local recurrence rate for SNHPC ranges from 8-53%, probably due to inadequate surgical excisions. Since tumor recurrence can occur years after treatment, life-long follow up should be observed.<sup>4-8</sup>

### Conclusion

Clinical, imaging and pathological evaluations of seven cases of SNHPC are described. Surgical management and tumor behavior are also demonstrated. Most of our patients presented with chronic epistaxis and nasal obstruction. Imaging evaluation with CT and MR is essential to assess extension of the tumor for surgical planning. Final pathological diagnosis is achieved with special stains and electron microscopy. The tendency for recurrence of SNHPC is stressed, as well as the need for long-term follow-up.

### References

1. Stout AP, Murray MR. Hemangiopericytoma: A vascular tumor featuring Zimmerman's pericytes. *Ann Surg* 1942; 116:26-33.
2. Zimmerman KW. Der feinere bau der blutcapillaren. *Z Anat Entwicklungsgesch* 1923; 68: 29-109.
3. Millman B, Brett D, Vrabec D. Sinonasal Hemangiopericytoma. *ENT J* 1994; 73: 680-7.
4. Boey H, Mitra S, Yanagisawa E. Intranasal Hemangiopericytoma. *ENT J* 1998; 77: 944-5.
5. Reiner S, Seigel G, Clark K, et al. Hemangiopericytoma of the nasal cavity. *Rhinology* 1990; 28: 129-36.
6. Herve S, Alsamad I, Beatru R, et al. Management of Sinonasal hemangiopericytomas. *Rhinology* 1999; 37: 153-8.
7. Bhattacharya N, Shappiro N, Metson R. Endoscopic resection of a recurrent sinonasal hemangiopericytoma. *Am J Otolaryngol* 1997; 18: 341-4.
8. Catalano P, Brandwein M, Shah D. Sinonasal hemangiopericytomas: A clinicopathologic and immunohistochemical study of seven cases. *Head Neck* 1996; 18: 42-53.
9. Webber W, Henkes H, Metz K. Haemangiopericytoma of the nasal cavity. *Neuroradiology* 2001; 43: 183-6.
10. Thompson LD, Miettinen M, Wenig BM. Sinonasal-type Hemangiopericytoma: A clinicopathologic and immunophenotypic analysis of 104 cases showing perivascular myoid differentiation. *Am J Surg Pathol* 2003; 27 (6): 737-49.
11. Morrison D, Bibby K. Sellar and suprasellar hemangiopericytoma mimicking pituitary adenoma. *Arch Ophthalmol* 1997; 115: 1201-3.
12. Stout AP. Hemangiopericytoma: a study of twenty-five new cases. *Cancer* 1949; 2: 1027-37.
13. Compagno J, Hyams VJ. Hemangiopericytoma-like intranasal tumors: A clinicopathologic study of 23 cases. *Am J Clin Pathol* 1976; 66: 672-83.
14. Watanabe K, Saito A, Suzuki M. True Hemangiopericytoma of the nasal cavity. Immunohistochemical and electron microscopic study of 2 cases and a review of the literature on sinonasal hemangiomas. *Arch Pathol Lab Med* 2001; 125: 686-90.
15. Millis SE, Gaffey MJ, Frierson HF. Tumors of the upper aerodigestive tract and Ear. In: *Atlas of tumor pathology 3rd series. Fascicle 26*. Washington, DC: Armed Forces Institute of Pathology; 2000, p. 248.
16. Ravene J, Goodman P. Late pulmonary metastases from hemangiopericytoma of the mandible: Unusual findings on CT and MR imaging. *AJR* 2001; 177: 244-6.