

CASE REPORT: 29-YEAR-OLD MALE WITH HEMICHOREA-HEMIBALLISMUS AS THE INITIAL MANIFESTATION OF CEREBRAL TOXOPLASMOSIS IN THE SETTING OF UNTREATED HIV

Violante-Villanueva Arturo¹ | López-Hernández Juan Carlos¹✉ | Salas-Alvarado Lilia¹ | García Xiomara¹

1. Department of Neurological Emergencies, Manuel Velasco Suárez National Institute of Neurology and Neurosurgery

Correspondence

Juan Carlos Lopez Hernández.
Department of Neurological Emergencies, Manuel Velasco Suárez National Institute of Neurology and Neurosurgery. Insurgentes Sur 3877, La Fama, Tlalpan, 14269, México City, México.

✉ juanca9684@hotmail.com

Abstract

Background: Hemichorea and hemiballismus are rare movement disorders caused by central nervous system toxoplasmosis. **Objective:** To describe the case of a male patient with treatment-naïve HIV who initiated with right hemichorea and hemiballismus. **Case report:** We present a 29-year-old male with a history of untreated HIV. He presented to the emergency room with right-sided hemichorea and hemiballismus. The neurological examination was unremarkable, except for the presence of abnormal movements characterized by non-rhythmic, large-amplitude, violent and occasionally choreiform movements in the right side of his body. Brain MRI revealed a ring-enhancing lesion in the left basal nuclei, raising suspicion of CNS toxoplasmosis. Further serologic tests confirmed the diagnosis. Treatment was initiated with trimethoprim-sulfamethoxazole, pyrimethamine/clindamycin and antiretrovirals. Haloperidol, aripiprazole, and clonazepam were administered to alleviate abnormal movements. Subsequent MRI scans showed radiological improvement, and the patient was discharged. **Conclusion:** Hemichorea-hemiballismus is a neurological manifestation unfrequently related to CNS toxoplasmosis. Prompt initiation of antiretroviral therapy and antimicrobial treatment is crucial to improve patient outcomes.

Keywords: hemiballismus, hemichorea, toxoplasmosis, HIV, basal ganglia, central nervous system.

Introduction

Neurological manifestations represent the initial clinical presentation of acquired immunodeficiency syndrome (AIDS) in 10-30% of patients. These movement disorders can arise from direct central nervous system infection by human immunodeficiency virus (HIV) or opportunistic infections.¹ Hemiballismus is characterized by violent and involuntary flinging movements on one side of the body. Among the adult HIV-infected population, the prevalence of movement disorders varies from 2% to 44%, with hemichorea-hemiballismus (HCHB) being one of the most frequently observed presentations.²

Toxoplasma gondii is a ubiquitous, intracellular protozoan parasite that invades the central nervous system. The occurrence of hemichorea-ballismus in individuals with cerebral toxoplasmosis is uncommon. However, a subthalamic toxoplasma abscess stands as the leading cause of hemichorea-hemiballismus in AIDS patients. Although both conditions share a similar pathophysiology, ballismus manifests with proximal, high-amplitude movements, while chorea is characterized by more distal, lower amplitude movements.³



Berger et al. were the first to report involuntary movements in AIDS in 1984.⁵ In 1986, Navia et al. conducted an extensive study involving 27 patients with cerebral toxoplasmosis complicating acquired immune deficiency syndrome. Regarding abnormal movements, they reported a patient with hemiballismus who also exhibited choreiform movements in the distal upper and lower extremities and diffuse rigidity. Additionally, they described a second patient with left-sided choreoathetosis.⁶

Case Report

We present the case of a 29-year-old male who arrived at our emergency department with a 41-day history of involuntary movements on the right-side extremities. His medical history includes a three-pack-year history of smoking, high-risk sexual practices, engagement in male-male sexual activity, and a status of treatment-naïve HIV over the past four years.

His initial complaint was acute onset of involuntary and violent movements in his right foot. Within three days, these movements extended to involve the proximal right leg. Over the course of fifteen days, his symptoms worsened, with an increase in both amplitude and frequency, resulting in difficulty to walk. After a month, these abnormal movement progressed to affect his right superior limb. At this point, the patient also exhibited dysarthria and abnormal facial movements. General examination was unremarkable,

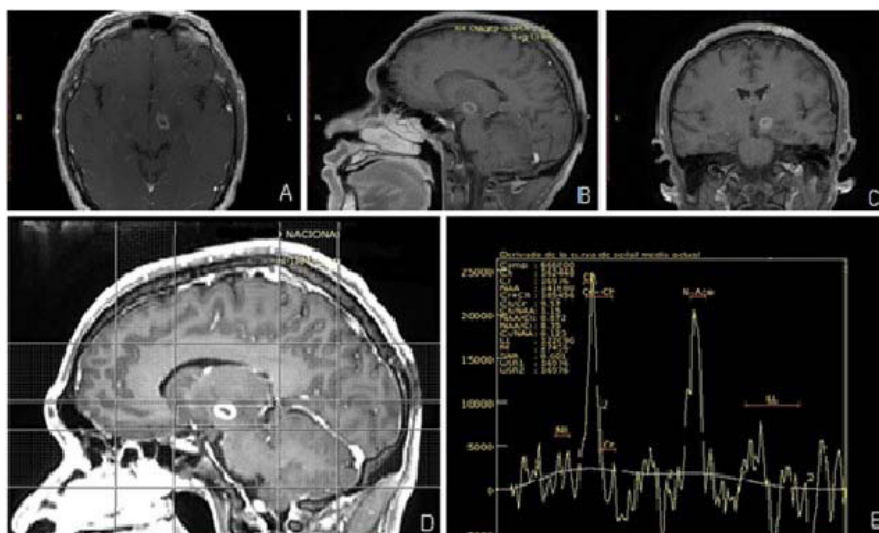
and neurological examination showed irregular high-amplitude abnormal movements in both his right upper and lower limbs (Video 1). These movements indicated a pattern consistent with hemiballismus and hemichorea.

Laboratory test revealed lymphopenia, with a count of 600 cells/ μ L. An MRI scan demonstrated a ring-enhancing lesion located in the left basal ganglia (Figure 1A). Cerebrospinal fluid analysis disclosed an elevated protein concentration (69 mg/dl) with no cells, and further cultures and multiple PCR testing returned negative results. His HIV-RNA viral load measured 456,920 copies, with a CD4 cell count of 129 cells/ μ L. The patient's serum toxoplasma IgG levels were significantly elevated at >150 IU/mL. In contrast, syphilis and ant streptolysin O (ASO) titers were negative.

Treatment was initiated with trimethoprim-sulfamethoxazole (TMP-SMX) at a dose of 160/800 mg/kg/day and pyrimethamine-clindamycin (P-C) for seven days. After treatment, a new MRI did not show improvement (Fig.1 B-C). To address the abnormal movements, the patient was prescribed haloperidol at a dose of 5mg every 8 hours, clonazepam every 8 hours, amantadine at 100mg every 8 hours, and it was considered necessary to add aripiprazole at a dose of 10 mg once a day. After six weeks of treatment, antiretroviral therapy was initiated, consisting of bictegravir (50mg), tenofovir (200mg), and emtricitabine (25mg). Subsequently, the patient demonstrated clinical and radiological improvement.

Video 1. Male patient upon arrival at the emergency department, displaying hemichorea and hemiballismus movements affecting the right side. To watch the video, click on the following link: https://drive.google.com/file/d/1kXIF_DNgKchaAvL8MsQfJcdE2J0tfQPI/view?usp=sharing

Figure 1. A) MRI conducted upon admission, depicting a hyperintense lesion with contrast enhancement located in the left subthalamic nucleus, accompanied by perilesional edema and meningeal enhancement. B-C) MRI scans performed 14 days post-treatment showing no improvement. D-E) Spectroscopy findings disclose a peak of choline and n-acetylcysteine



Discussion

Hemiballismus (HB) it is a rare disorder characterized by unilateral, involuntary, and irregular movements of variable amplitude in the affected individual. It is considered a more severe expression of hemichorea (HC),⁵ which involves involuntary, occasional, rapid, and non-patterned movements. Both of these conditions fall under the category of abnormal hyperkinetic movements, which exhibit a dormant state during sleep.

Stroke is the most common cause of acquired hemiballismus. The differential diagnosis includes any focal lesion, primarily within basal ganglia structures, although it is not exclusive to this region. It is important to mention hyperglycemic hemiballismus and complications associated with HIV infection since they are common and have been recently documented in the medical literature.⁷

Toxoplasma gondii (*T. gondii*) is an obligate intracellular protozoan parasite. Human infection occurs via ingestion of tissue cysts in undercooked meat, oocysts in contaminated water or food, and congenitally.¹¹ Worldwide, an estimated 13,138,600 cases of *Toxoplasma gondii* infection have occurred in patients with HIV infection, with a pooled prevalence among these patients of approximately 35.8%.⁹

In immunocompetent patients, primary *T. gondii* infection often remains asymptomatic. However, in immunocompromised individuals, especially those with HIV (PLHIV) or malignancies, this opportunistic pathogen can lead to severe disease.¹⁰ Typically, it manifests as a late complication in patients with fewer than 200 CD4 T cells/ μ l.^{3,4}

The clinical presentation of cerebral toxoplasmosis is nonspecific but often involves subacute neurologic symptoms and signs. Common presentations include headaches, fever, seizures, focal neurologic deficits, cranial nerve palsies, visual disturbances, confusion, and psychomotor or behavioral changes.⁹ Notably, in the HIV-positive population, known to have a high seropositivity rate for *T. gondii*, movement disorders comprised only 2.7% of neurological complications.¹ The literature reports nearly 30 cases of patients with abnormal movements as the initial presentation of toxoplasmosis infection.

This case is interesting because hemiballismus-hemichorea is uncommon. We describe a patient who had been diagnosed with HIV for four years but had not received treatment.

His CD4-positive T cell count was 129 cells/ μ l. Clinically, he exhibited right hemichorea and hemiballismus, with a reduction in these movements during sleep.

According to US guidelines, the preferred initial therapy for cerebral toxoplasmosis is a combination of pyrimethamine plus sulfadiazine (P-S). For patients with a sulfa allergy history, pyrimethamine plus clindamycin (P-C) is the preferred alternative regimen. TMP-SMX is suggested as a first-line option when P-C and P-S therapies are not available.¹² The mechanism of action of pyrimethamine is synergistic, inhibiting *T. gondii* proliferation and survival by blocking the folate metabolic pathway, particularly the synthesis of tetrahydrofolate, which the parasite requires for DNA synthesis.¹³ In severe and medication-resistant hemiballismus, functional neurosurgery, such as stereotactic thalamotomy or thalamic deep brain stimulation could be considered.⁵

Approximately 30% of *T. gondii* seropositive AIDS patients with a CD4+ T cell count below 200/ μ l experience reactivation, which can be lethal if not treated adequately with antiparasitic drugs. Globally, cerebral toxoplasmosis continues to affect patients for various reasons, including late HIV diagnosis, noncompliance with Highly Active Antiretroviral Therapy (HAART) or preventive antimicrobial drugs, and virological and immunological HAART failure.¹ In AIDS patients, the reactivation of latent cerebral toxoplasmosis holds significant clinical importance.

Conclusion

Toxoplasmosis represents a common neurological infection, yet hemichorea-hemiballismus is unusual. Timely recognition and prompt treatment of acute symptoms during the initial phase of cerebral toxoplasmosis reduces the risk of neurological sequelae and mortality.

Acknowledgements: none.

No author declares any conflict of interest.

Funding sources: none

References

1. Bowen LN, Smith B, Reich D, Quezado M, Nath A. HIV-associated opportunistic CNS infections: pathophysiology, diagnosis and treatment. *Nat Rev Neurol*. 2016;12(11):662-74. doi: [10.1038/nrneurol.2016.149](https://doi.org/10.1038/nrneurol.2016.149)
2. Patel AR, Patel AR, Desai S. Acute hemiballismus as the presenting feature of parietal lobe infarction. *Cureus*. 2019;11(5):e4675. doi: [10.7759/cureus.4675](https://doi.org/10.7759/cureus.4675)
3. Dimal NPM, Santos NJC, Reyes NGD, Astejada MN, Jamora RDG. Hemichorea-hemiballismus as a presentation of cerebritis from intracranial toxoplasmosis and tuberculosis. *Tremor Other Hyperkinet Mov*. 2021;11:2. doi: [10.5334/tohm.576](https://doi.org/10.5334/tohm.576)
4. Mattos JP, de Rosso AL, Corrêa RB, Novis S. Hemicorea asociada a toxoplasmosis cerebral y SIDA. *Arq Neuropsiquiatr*. 1995;53(3A):534.
5. Postuma RB, Lang AE. Hemiballismus: revisiting a classic disorder. *Lancet Neurol*. 2003;2:661-8. doi: [10.1016/S1474-4422\(03\)00554-4](https://doi.org/10.1016/S1474-4422(03)00554-4)
6. Navia BA, Petite CK, Gold JWM, Cho E -S, Jordan BD, Price RW. Cerebral toxoplasmosis complicating the acquired immune deficiency syndrome: Clinical and neuropathological findings in 27 patients. *Ann Neurol*. 1986;19(3):224-38.
7. Kim JS. Case report: vesicocutaneous fistula. *Can Fam Physician*. 2001;47(10):788-9.
8. Tse W, Cersosimo MG, Gracias JM, Morgello S, Olanow CW, Koller W. Movement disorders and AIDS: a review. *Park Relat Disord*. 2004;10(6):323-34. doi: [10.1016/j.parkreldis.2004.03.001](https://doi.org/10.1016/j.parkreldis.2004.03.001)
9. Marcus C, Feizi P, Hogg J, Summerfield H, Castellani R, Sriwastava S, et al. Imaging in differentiating cerebral toxoplasmosis and primary CNS lymphoma with special focus on FDG PET/CT. *Am J Roentgenol*. 2021;216(1):157-64. doi: [10.2214/AJR.19.22629](https://doi.org/10.2214/AJR.19.22629)
10. Safarpour H, Cevik M, Zarean M, Barac A, Hatam-Nahavandi K, Rahimi MT, et al. Global status of *Toxoplasma gondii* infection and associated risk factors in people living with HIV. *Aids*. 2020;34(3):469-74. doi: [10.1097/QAD.0000000000002424](https://doi.org/10.1097/QAD.0000000000002424)
11. Schlüter D, Barragan A. Advances and challenges in understanding cerebral toxoplasmosis. *Front Immunol*. 2019;10:242. doi: [10.3389/fimmu.2019.00242](https://doi.org/10.3389/fimmu.2019.00242)
12. Vidal JE. HIV-related cerebral toxoplasmosis revisited: current concepts and controversies of an old disease. *J Int Assoc Provid AIDS Care*. 2019;18:2325958219867315. doi: [10.1177/2325958219867315](https://doi.org/10.1177/2325958219867315)
13. Hernandez AV, Thota P, Pellegrino D, Pasupuleti V, Benites-Zapata VA, Deshpande A, et al. A systematic review and meta-analysis of the relative efficacy and safety of treatment regimens for HIV-associated cerebral toxoplasmosis: is trimethoprim-sulfamethoxazole a real option? *HIV Med*. 2017;18(2):115-24. doi: [10.1111/hiv.12402](https://doi.org/10.1111/hiv.12402)
14. Hosoda T, Mikita K, Ito M, Nagasaki H, Sakamoto M. Cerebral toxoplasmosis with multiple hemorrhage lesions in an HIV infected patient: A case report and literature review. *Parasitol Int*. 2021;81:102280. doi: [10.1016/j.parint.2020.102280](https://doi.org/10.1016/j.parint.2020.102280)