

Subcutaneous Emphysema Secondary to the Performance of Positive Air Pressure After a Sharp Object Injury to the Hand: Case Report

Enfisema subcutáneo secundario a la entrada de aire a presión positiva tras una lesión por objeto punzocortante: reporte de caso

Víctor Gómez-Recillas,* Fernanda Cortés-Palma,** Laura A. Montes-Rangel,*** Roberto C. Vidal-Juárez,* Juana Fabila-Sánchez,** Jazmín Jiménez-Corona,** Oscar Juárez-Sánchez.**

Abstract

Subcutaneous emphysema is the novo infiltration of air in the subcutaneous layer of skin. The incidence of subcutaneous emphysema varies from 0.43% to 2.34%. and can result from surgical, traumatic, infectious, or idiopathic processes. Air can enter the subcutaneous tissue through occupational accidents, as occurred in our clinical presentation; on physical examination, the most common finding associated with subcutaneous emphysema is crepitus on palpation. It is important to make a timely diagnosis to determine the cause, provide appropriate management and avoid complications.

Keywords: Subcutaneous Emphysema, Injuries, Sharps injuries, Air Pressure

Resumen

El enfisema subcutáneo es la infiltración de novo de aire en la capa subcutánea de la piel. La incidencia de enfisema subcutáneo varía de 0.43% a 2.34% y puede ser resultado de procesos quirúrgicos, traumáticos, infecciosos o idiopáticos. El aire puede entrar al tejido subcutáneo por vía de accidentes de trabajo, como en el presente caso; al examen físico el hallazgo más común asociado al enfisema subcutáneo es la crepitación a la palpación. Es importante hacer un diagnóstico oportuno para determinar la causa, dar el manejo adecuado y evitar complicaciones.

Palabras clave: enfisema subcutáneo, lesiones, cortopunzantes, presión de aire

Received: 20/07/2022
Accepted: 02/08/2022

*General Hospital of Zone 53, Mexican Institute of Social Security (IMSS).

**Family Medicine Unit 78, Mexican Institute of Social Security (IMSS).

***Family Medicine Unit 28, Mexican Institute of Social Security (IMSS).

Correspondence to:
Victor Gómez R. e-mail:
vic_gom_re@hotmail.com

Suggestion of quotation: Gómez-Recillas V, Cortés-Palma F, Montes-Rangel LA, Vidal-Juárez RC, Fabila-Sánchez J, Jiménez-Corona J, Juárez-Sánchez O. Subcutaneous Emphysema Secondary to the Performance of Positive Air Pressure After a Sharp Object Injury. *Aten Fam.* 2022;29(4):268-271. <http://dx.doi.org/10.22201/fm.14058871p.2022.4.83419>

This is an open access article under the CC BY-NC-ND license (<http://creativecommons.org/licenses/by-nc-nd/4.0/>).

Introduction

Subcutaneous emphysema is defined as the presence of air in the subcutaneous layer of skin, the novo generation or by infiltration.¹ Subcutaneous emphysema of the hand and upper extremity caused by minor trauma is a relatively rare phenomenon as a result of industrial accidents.² Subcutaneous emphysema generally presents an incidence of 0.43% to 2.34%, which can be a result from surgical, traumatic, infectious, or spontaneous etiologies.¹ Air can reach tissues depending on the cause. The proposed mechanism in limb wounds is a defect/breach in the skin that acts as a flap valve, enabling air to be introduced into the superficial tissues by the negative pressure caused by movement.³ This, along with opening and closing the hand, drives pressure dynamics, pumping air through the wound inwards. On physical examination, the most common finding associated with subcutaneous emphysema is crepitus on palpation, there may be swelling of the abdomen, chest, neck and face, and phonation changes from vocal cord compression can also be present.^{1,4} To make a timely diagnosis to determine the cause, allows to provide an appropriate management and prevent complications. A patient with a hand injury who repeatedly opened and closed his hand causing immediate extensive emphysema is presented. He was managed conservatively, evolving satisfactorily.

Case report

A 41-year-old male with no apparent relevant medical records, went to the emergency room five hours after having injured his right-hand with a sharp object while working using a drill. The

patient mentioned he extracted the object and proceeded with open-close movements of his hand for more than a minute. He referred feeling the air entering through his wound by the movements. Hours later, he observed increased volume in the hand and arm and speech impediment. At admission to the emergency room, vital signs were reported with normal parameters, a wound in right hand thenar eminence

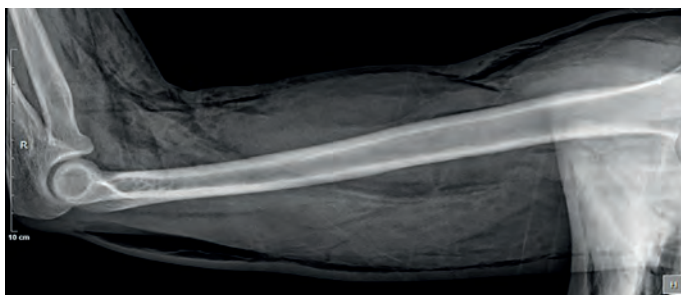
of roughly one centimeter, without erythema, and pain at pressure. Extensive subcutaneous emphysema on the right arm, chest and neck was found on radiographies and palpation, see Figures 1, 2 and 3. Laboratory results are presented in table 1. Clinical management with parenteral solutions, analgesics and antibiotic prophylaxis based on clindamycin, progressed to improvement, and discharged the following day.

Table 1.

Day	Clinical evolution	Laboratory	Radiology
1	Increased volume of the hand and arm Speech impediment Pain after pressure the thenar eminence	Hematic biometrics: Leukocytes 18.3x103/ml Neutrophils 86.4% Hemoglobin 14.7 g/dl Platelets 258.8x103/ml	Fig. 1, 2, 3
2	Decrease in volume Normal speech Painless	Hematic biometrics: Leukocytes 10.5x103/ml Neutrophils 70% Hemoglobin 14.5 g/dl Platelets 258.5x103/ml	

Figure 1. Right hand X Ray. Subcutaneous emphysema

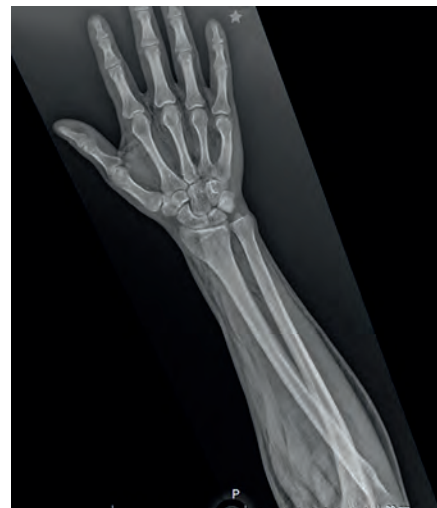

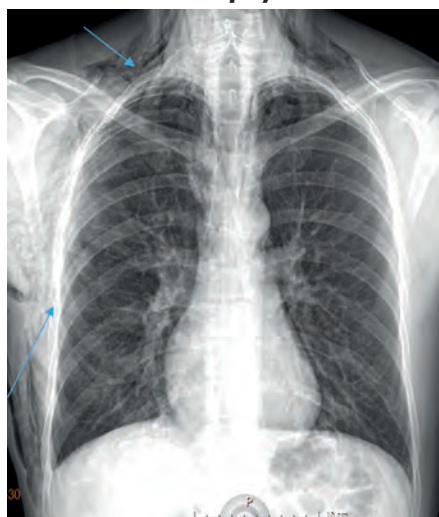Figure 2. Right arm X Ray. Subcutaneous emphysema**Figure 3. Chest X Ray. Subcutaneous emphysema****Discussion**

Different mechanisms have been previously described: 1. Injury to the parietal pleura enabling air passage to pleural and subcutaneous tissues, 2. Alevolar air reaching endovascular sheath and pulmonary hilum into the endothoracic fascia, 3. Mediastinum air extending to cervical viscera and other connecting tissue planes, 4. Air from external sources, 5. Gas generation locally by necrotizing infections.⁵ Air from external sources, is the least common cause of this condition.

The most frequent and prominent signs and symptoms are swelling and crepitus on palpation. Neck involvement is accompanied by chest discomfort. Other symptoms include sore throat, neck pain, difficulty swallowing, shortness of breath, wheezing, distension, and dysphonia due to compression of the vocal cords.⁴

No standardized classification has been reported for severity or extent of emphysema, but Aghajanzadeh classified the severity based on anatomical

extension into five grades in 2015:

1. Base of the neck
2. Complete neck area
3. Subpectoral is major area
4. Chest wall and all the neck area
5. Chest wall, neck, orbit, scalp, abdominal wall, upper limbs, and scrotum.⁵

It is important to differentiate noninfectious (benign) subcutaneous emphysema with infectious. Gas appearing in the subcutaneous tissue within 6-10 hours after trauma is most

likely due to a benign cause, in contrast, gas infection forming pathogen usually takes 12-18 hours to develop along with other symptoms such as fever, chills, hypotension, tachycardia and altered laboratory tests.⁶ Williams and Aston describe some aspects to consider in establishing this difference: “1. Exclusion of clostridial infection, 2. Absence of pyrexia, tachycardia, shock, or leukocytosis, 3. Presence of a puncture site situated over/in a joint involved in repetitive movement, 4. X-ray should demonstrate emphysema confined to the subcutaneous or interfascial planes without myositis (thus excluding gas gangrene), and 5. Emphysema usually progresses rapidly after injury.”³

Diagnosis is made by physical examination (crepitus on palpation over the affected area) and radiological tests show air presence over the affected area. The imaging included radiology, computed tomography (CT) and nuclear magnetic resonance.⁷ Treatment decision can be based on routine laboratory testing.^{8,9}

Treatment will depend on the cause, extent, and severity of emphysema. Subcutaneous emphysema usually resolves spontaneously. In some cases,

it requires urgent management, when it is massive and should be drained, or when it is associated with an infectious process.

In this clinical presentation, patient presented leukocytosis on admission, an infectious process was discarded due to clinical signs and the immediate onset of subcutaneous emphysema after the accident. Alveolar or digestive cause was discarded, no drainage was required. Analgesics, prophylactic antibiotics, relative rest, and hydration was enough to achieve satisfactorily progress after 24 hours.

Conclusion

The aim of reporting this clinical case is to recognize rare and unexpected causes of subcutaneous emphysema. In our patient, the explanation is movement maneuvers with the hand after suffering the hand injury that allowed a wide diffusion. Recognizing causes and mechanisms allows correct and timely management for the benefit of patients.

References

1. Kukuruza K, Aboeed A. Subcutaneous Emphysema. StatPearls. PMID: 31194349. [Internet]. [Consulted 2022 May 2]. Available at: <https://www.ncbi.nlm.nih.gov/books/NBK542192/>
2. Saela S, Decilveo A, Isaac R, Patel DV. Traumatic subcutaneous emphysema of the hand/

forearm: A case report. *Chin J Traumatol.* 2022;S1008-1275(22)00038-4. DOI: 10.1016/j.cjtee.2022.04.001

3. Williams AB, Aston NO. Sucking injury or gas gangrene? *Ann R Coll Surg Engl.* 1999;81(2):115-16.
4. Karadakhly KA, Kakamad FH, Mohammed SH, Salih AM, Ali RK, Kakamad SH, et al. Recurrent spontaneous subcutaneous emphysema of unknown origin: A case report with literature review. *Ann Med Surg (Lond).* 2022;76:103443. DOI: 10.1016/j.amsu.2022.103443
5. Aghajanzadeh M, Dehnadi A, Ebrahimi H, Falah Karkan M, Khajeh Jahromi S, Amir Maafi A, Aghajanzadeh G. Classification and Management of Subcutaneous Emphysema: a 10-Year Experience. *Indian J Surg.* 2015;77(2):673-7. DOI: 10.1007/s12262-013-0975-4
6. Stahl I, Puchkov N, Dreyfuss D. Noninfectious Subcutaneous Emphysema of the Upper Extremity-Case Report and Review of the Literature. *Sch J Emerg Med Crit Care.* 2017;1(1):21-24.
7. Peña-Pérez, Carrillo-Esper R, Meza Márquez JM, Martínez Baltazar YI. Enfisema subcutáneo extenso. *Medicina Crítica.* 2021;35(2):101-105. DOI: 10.35366/99531
8. Christen SM, Gruenert JG, Winsauer S. Benign subcutaneous emphysema: a rare and challenging entity a case report and review of the literature. *Case Reports Plast Surg Hand Surg.* 2021;8(1):153-157. DOI: 10.1080/23320885.2021.1984922
9. Kruppa C, Königshausen M, Gessmann J, Dudda M, Schildhauer T, Seybold D. Air Entrapment durch einen Ventilmechanismus bei chronischen Wunden, ein harmloses Phänomen? Eine Beschreibung von 3 Fällen [Air Entrapment Caused by Valve Mechanisms in Chronic Wounds, a Benign Phenomenon? A Series of Three Cases]. *Z Orthop Unfall.* 2015;153(6):648-51. DOI: 10.1055/s-0041-106787