

CLINICAL CASE

Ohtahara syndrome associated with H-type tracheoesophageal fistula

Mario Eduardo Rodríguez Miralrío,¹ Marco Antonio Toxtle Román,² Carlos Javier Huesca Quintero^{1,3}

ABSTRACT

Background. Ohtahara syndrome is an early infantile epileptic encephalopathy characterized by frequent tonic spasms, partial seizures and occasional myoclonus. Interictal EEG characteristically shows a pattern of burst of spikes alternating with phases of suppression of brain electrical activity ("burst-suppression"). Clinical manifestations usually begin before 20 days of life. The few cases reported in the literature do not mention associated congenital malformations.

Case report. We report the first case of a 6-month-old male infant with Ohtahara syndrome associated with H-type tracheoesophageal fistula.

Conclusions. The association between Ohtahara syndrome and tracheoesophageal fistula may be due to a fortuitous presentation without any relationship with the neurological syndrome.

Key words: Ohtahara syndrome, seizures, burst-suppression, tracheoesophageal fistula.

INTRODUCTION

Ohtahara syndrome (OS) or early infantile epileptic encephalopathy (EIEE) is a progressive and debilitating neurological disorder that results in untreatable seizures and severe mental retardation. Clinically, OS is characterized by tonic spasms initially associated with a severe and continuous burst activity pattern.¹ Its etiology is idiopathic or symptomatic.² It was described for the first time in 1976 by Ohtahara as a syndrome characterized by tonic spasms that occur before 20 days of life, generally in the first 5 days, and that lacked the fragmentary myoclonus or clonic crisis described by Aicardi and Gutierrez but that had the same electroencephalographic (EEG) type pattern of burst-suppression (BS).³⁻⁵

The tracheoesophageal fistula (TEF) is a congenital malformation that occurs as a consequence of a failure in the course of the development of the tracheoesophageal ridge (tracheobronchial canal) during the sixth week of embryonic development. There is an actual incidence of

1:4000 newborns, equally affecting both genders. In 50-70% of the cases it is associated with cardiac, gastrointestinal and genitourinary abnormalities.⁶

There are no cases reported in the literature of patients with these two disorders, given that they have a different embryological origin whose formation is made up of different gestational ages. In this study we documented the presence of these two abnormalities in the same patient.

CLINICAL CASE

We present the case of a 6-month-old male. The patient was the product of a GIII mother, 32 years of age, who had a normal pregnancy and adequate prenatal care. The patient was vaginally delivered in the hospital at 37 weeks gestation, with a birth weight of 2055 g and length of 48 cm. Apgar score was unknown. He was discharged to home at 24 h of birth. There was no family history of convulsive crisis or epilepsy. At 72 h of life the patient had a cardiac arrest secondary to convulsive crisis and was transferred to the nearest hospital center. On examination he was found to be hypotrophic and hypoactive with global spasticity. Head was microcephalic with overriding of the sutures and widened anterior fontanel. Cardiopulmonary system was without apparent alterations. The patient displayed poor tolerance to oral feeding without sucking reflex.

¹ Hospital General Regional 25 Zaragoza, Instituto Mexicano del Seguro Social, México, D.F.

² Hospital Integral Atlapexco, SSA Atlapexco, Hidalgo.

³ Centro Médico Nacional La Raza, México D.F.

Received for publication: 3-3-13

Accepted for publication: 6-12-13

The extremities were hyperreflexic and exhaust clonus. It was decided to use advanced airway management due to recurrent seizures refractory to treatment with midazolam 100 mg/kg/dose and phenytoin at 7 mg/kg/day. Thus the patient was referred to a tertiary care hospital for study protocol.

The patient persisted to have tonic/clonic seizures (Figure 1); therefore, study protocol was initiated. A broad metabolic screening was carried out, which did not identify disorders or innate metabolic errors. Cytological, cytochemical and spinal fluid cultures were all normal. Skull tomography demonstrated global leucoencephalomalacia probably secondary to hypoxic-ischemic encephalopathy (Figure 2). EEG revealed a BS pattern. On this basis, diagnosis of OS was established by the Department of Pediatric Neurology (Figure 3). Vigabatrin treatment was started at 80 mg/kg/day and valproic acid at 20 mg/kg/day, resulting in control of the seizures. The patient was referred to a secondary level hospital for further management.

Upon re-admission the patient presented weak sucking response; therefore, gastrostomy was performed in order to improve nutrition. Esophagogastroduodenoscopy revealed passage of contrast media to the airway (Figure 4) with the diagnosis of type H TEF (Figure 5).

During the patient's hospital stay, he experienced a nosocomial infection due to *Pseudomonas aeruginosa* (central and peripheral blood culture positive). The antibiogram showed intermediate susceptibility to meropenem (120 mg/kg/day) and cefepime (150 mg/kg/day). However, he presented poor response to antibiotic treatment and developed septic shock with disseminated intravascular coagulation, which ultimately caused his death at 6 months of age.

DISCUSSION

OS is an epileptic disorder such as West syndrome and can be idiopathic or symptomatic as well as age dependent.^{7,8} The most frequent characteristics of this syndrome are its initiation prior to 3 months of age, poor prognosis, refractoriness to antiepileptic treatment and a BS EEG pattern.⁸⁻¹⁰ This EEG pattern is the most constant characteristic and of greater specificity. Ohtahara described the parameters used for diagnosing the syndrome:

- Bursts of amplitude of 150 to 300 μ V of second duration and mixed frequency that includes spike discharges
- Periods of suppression and reduced amplitude with duration of 5-7 sec.¹¹

Children with OS have four common characteristics, although lacking in specificity:

- 1) Beginning of convulsions in infancy
- 2) Poor prognosis
- 3) Tonic clonic convulsions
- 4) Burst suppression activity in the EEG

The newborn period is the stage in which convulsions are most frequent and are normally associated with a poor prognosis.¹¹

The difference between OS and early myoclonic encephalopathy (EMT) has been emphasized by some authors who classify all newborns with multifocal myoclonic convulsions as EMT. Both syndromes share the BS pattern in the EEG, independent of the sleep-awake state.⁸ These authors base themselves on the presence of myoclonus to exclude OS.^{9,11}

However, BS in EMT is generally most evident during the sleep state, making EEG recordings during sleep to be of great importance for diagnosis. It must be emphasized that BS in EIEE is found from the beginning only in limited cases (generally disappearing at 6 months), whereas BS in EMT is found persistently in all cases, even after 1 year of age and up to the end of follow-up.¹

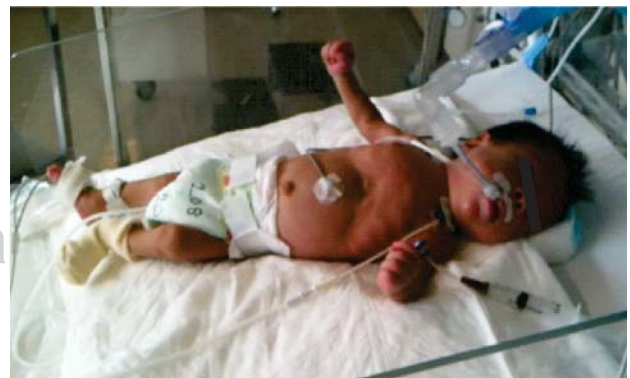

Figure 1. Three-month-old male with Ohtahara syndrome with mechanical ventilation.

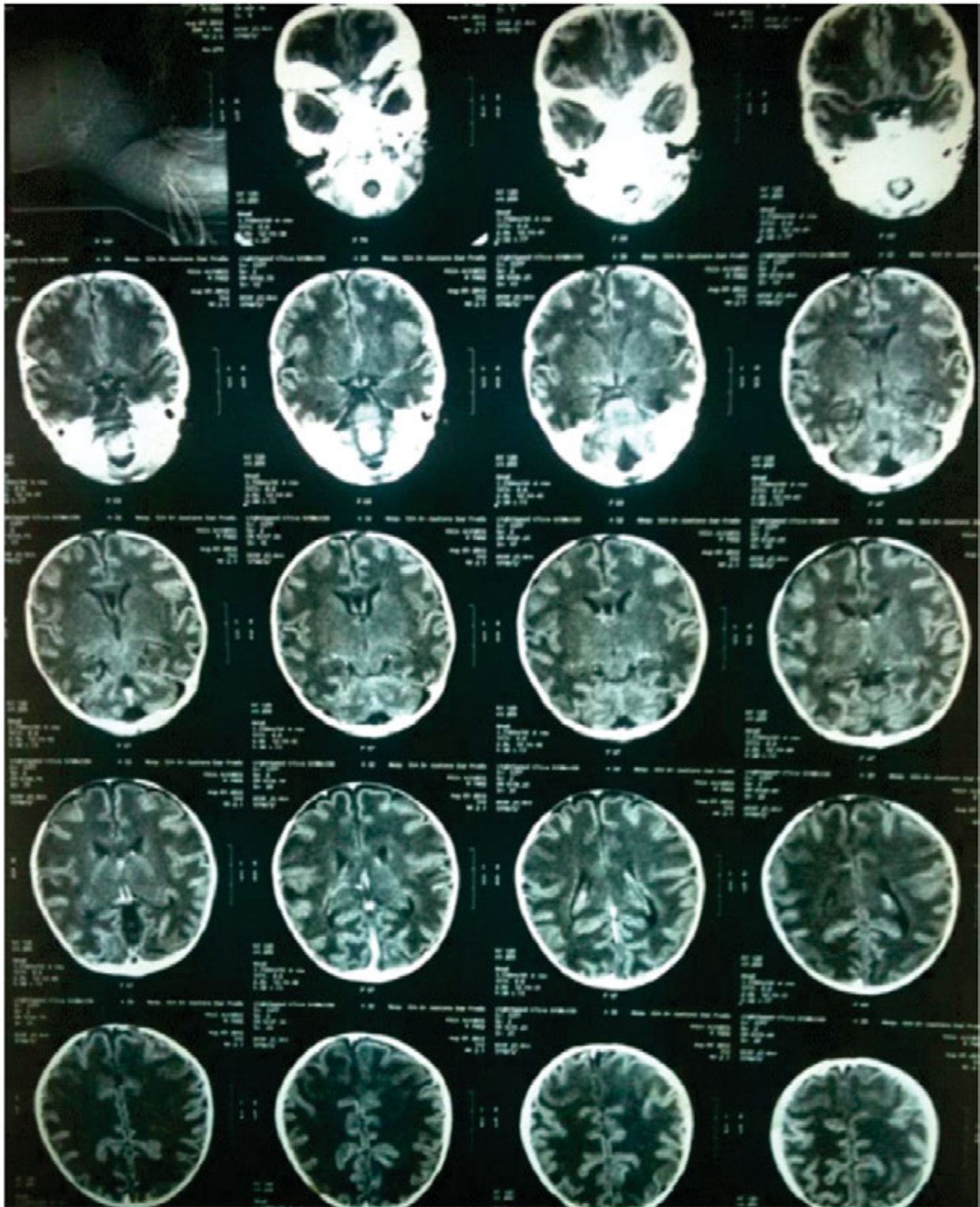


Figure 2. Tomography of brain with generalized leucoencephalomalacia.

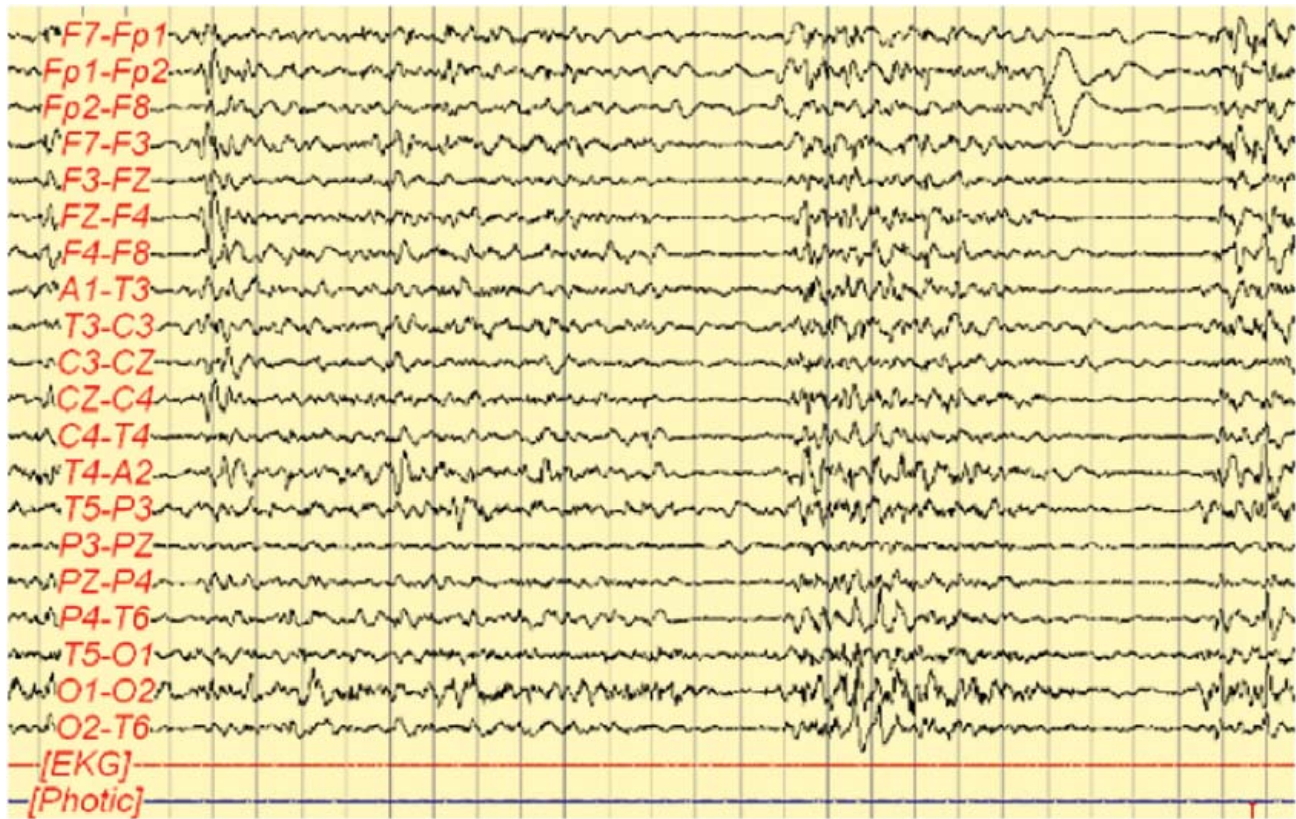

Figure 3. Electroencephalogram with burst-suppression pattern.

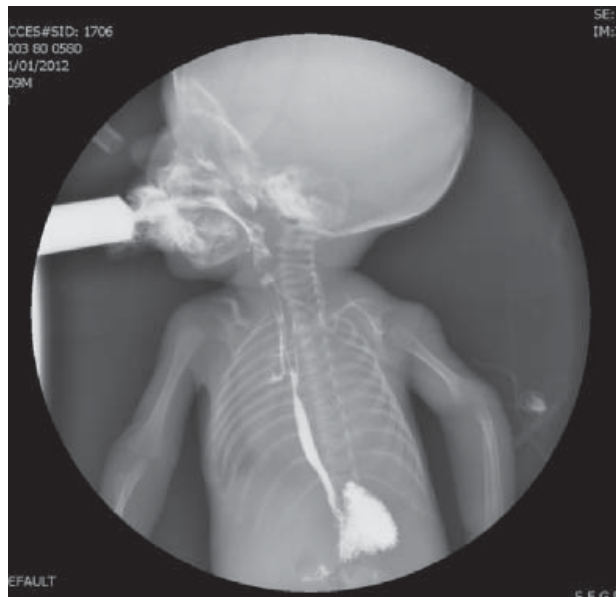

Figure 4. Gastroesophageal studies. Contrast medium is deflected to the right side at the fifth intercostal space.

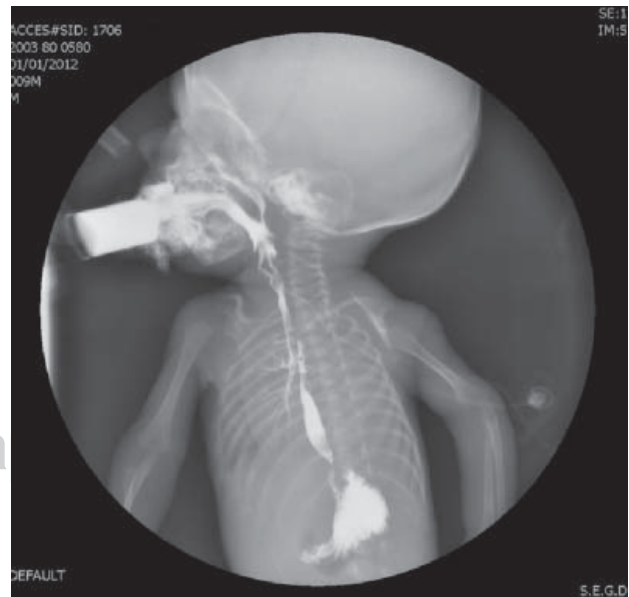


Figure 5. Gastroesophagoduodenal series. Passage of the contrast medium forms an H-type image and bronchial plot is displayed.

Currently they are included as two separate syndromes in the classification of epilepsy but are used interchangeably as synonyms in the McKusick (OMIM) classification.^{1,12} Preliminary molecular studies appear to indicate genetic differences between the two disorders (EMT is probably caused by the rupture of the neuregulin-1 receptor ErbB4).¹³ Despite a series of clinical and neurophysiological coincidences,¹⁴ EIEE, EMT and other primary epileptic encephalopathies such as West syndrome and Lennox-Gastaut syndrome are probably part of a continuous phenotype whose clinical differences (for example type of crisis, the EEG patterns, transition to other forms of epilepsy, natural history and response to treatment) are dictated by abnormal proteins as a result of specific genetic mutations.¹

Based on the clinical picture and BS EEG pattern, this patient presented with OS. The malformations most frequently associated with this syndrome are those pertaining to the central nervous system. Furthermore, this case was associated with TEF, which was found coincidentally.

Many of the original characteristics proposed by Ohtahara have remained consistent through time.¹⁵⁻¹⁷ Other neurophysiological characteristics and etiological findings have been integrated as a result of more recent advances.¹⁸ OS is a rare entity from the epidemiological point of view. Data are scarce and controversial, with a prevalence from 0.2% to 4% of infantile epilepsies.^{1,19}

Clinical picture of OS

The age at which convulsions appear is limited to the neonatal age or very infantile periods. In a study, in ~30% of cases there were convulsions within the first 10 days of life compared with ~70% of 1-month-old children.¹⁸ The principal pattern of the convulsions is tonic spasms with or without clustering, which is observed in all cases and can be generalized, symmetrical or lateralized. The duration of the spasms is short (up to 10 sec). These spasms are clinically similar to those of West syndrome although with some different characteristics: both appear during the wake state and sleep state and without clustering.^{18,20-22}

In addition to tonic spasms, in ~30% of cases partial motor seizures, hemiconvulsions or generalized tonic seizures are observed. The daily frequency of attacks is very high, going from 100-300 episodes in children with isolated seizures and from 10 to 20 clusters in individuals expe-

riencing groups of convulsions. Myoclonic seizures are rarely recorded.^{1,17}

Interictal EEG findings

The most specific feature of the EEG is the BS pattern, which presents bursts of high voltage slow-wave spikes mixed with multifocal peaks, alternating with a flat tracing (isoelectric) of suppression to an approximately regular velocity. Among other distinctive characteristics is the consistent appearance, both in the wake stage as well as in sleep, and the frequency. This is a very specific diagnostic finding.^{20,21}

Electroencephalographically, BS pattern gradually decreases from 3 months of age. It usually disappears after 6 months: it becomes hypsarrhythmia in most cases (between 2 and 6 months of age) or displays a slower transition and becomes spike-wave or multiple independent peaks.²³

Neuroimaging findings

The most common structural abnormalities include cerebral asymmetry, macrocephaly, hemimegalencephaly, agyria pachygyria, polymicrogyria, focal cortical dysplasia, olivary dysplasia, collicoli dysgenesis and posterior fossa abnormalities.^{22,24-26} However, the most common brain abnormality is hypodemyelination and diffuse cortical atrophy.

Therapeutic strategies

Administration of ACTH (adrenocorticotropin hormone) has proven to be effective in OS and, in some cases, even after the transition to West syndrome. Anecdotal cases have also been reported of clonazepam and acetazolamide effectiveness. We used high doses of vitamin B6, sodium valproate, vigabatrin or a ketogenic diet, but with poor results.

In a recent study, zonisamide was used to suppress convulsions. However, these results should be interpreted with caution. However, these results should be interpreted with caution. Hemispherectomy in selected children with brain abnormalities (e.g., macrocephaly or callosum) has shown promising results, suggesting that age is not a contraindication for surgery.¹

Apparently, the association between OS and TEF is due to a fortuitous situation with no relation with the neurological syndrome. This case was managed with vigabatrin and valproic acid, with achievement of seizure

control, although the ideal is continuous EEG monitoring for adequate clinical evidence of response to antiepileptic management.

Correspondence: Dr. Marco Antonio Toxtle Román
E-mail: drmatr@hotmail.com

REFERENCES

- Pavone P, Spalice A, Polizzi A, Parisi P, Ruggieri M. Ohtahara syndrome with emphasis on recent genetic discovery. *Brain Dev* 2012;34:459-468.
- Campistol J. Convulsiones neonatales refractarias. *Medicina (Buenos Aires)* 2009;69:41-50.
- Faúndez JC. Convulsiones neonatales. *Rev Pediatr Elec* 2005;2:26-35.
- Feld V, Vita C. Encefalopatía epiléptica infantil temprana (EEIT). Manifestación clínica, etiología y tratamiento neonatal, a propósito de un caso. *Rev Hosp Mat Inf Ramón Sardá* 2011;30:54-57.
- Palencia R. Síndromes convulsivos en el período neonatal. *Bol Pediatr* 2002;42:31-39.
- Instituto Nacional de Perinatología. Defectos del aparato digestivo. Atresia de esófago y fístula traqueoesofágica. In: *Normas y Procedimientos de Neonatología*. México, DF: In-Per; 2009. pp. 120-123.
- Aviña-Fierro JA, Hernández-Aviña DA. Encefalopatía epiléptica infantil temprana. Descripción de un caso de síndrome de Ohtahara. *Rev Mex Pediatr* 2007;74:109-112.
- Krasemann T, Hoovey S, Uekoetter J, Bosse H, Kurlmann G, Debus OM. Early infantile epileptic encephalopathy (Ohtahara syndrome) after maternal electric injury during pregnancy: etiological considerations. *Brain Dev* 2001;23:359-362.
- Aicardi J. Early myoclonic encephalopathy. In: Roger J, Bureau M, Dravet C, Dreifuss FE, Perret A, Wolf P, eds. *Epileptic Syndromes in Infancy, Childhood and Adolescence*. London: John Libbey Eurotext; 1985; pp. 12-21.
- Korff CM, Vulliemoz S, Picard F, Fluss J. Ohtahara syndrome or early-onset West syndrome? A case with overlapping features and favorable response to vigabatrin. *Eur J Paediatr Neurol* 2012;16:753-757.
- Yelin K, Alfonso I, Papazian O. Síndrome de Ohtahara. *Rev Neurol* 1999;29:340-342.
- OMIM. Online Mendelian Inheritance in Man. Baltimore: Johns Hopkins University Press; 2008.
- Guerrini R. Epilepsy in children. *Lancet* 2006;367:499-524.
- Backx L, Ceulemans B, Vermeesch JR, Devriendt K, Van Esch H. Early myoclonic encephalopathy caused by a disruption of the neuregulin-1 receptor ErbB4. *Eur J Hum Genet* 2009;17:378-382.
- Ohtahara S, Ishida T, Oka E, Yamatogi Y, Inoue H, Kanda S. On the specific age-dependent epileptic syndrome: the early-infantile epileptic encephalopathy with suppression-burst. *No To Hattatsu* 1976;8:270-280.
- Ohtahara S. A study of the age-dependent epileptic encephalopathy. *No To Hattatsu* 1977;9:2-21.
- Delgado-Ochoa MA, Marca-González SR, Huerta-Hurtado AM, Pérez-Ramírez JM, Hernández-Hernández M, Baragán-Pérez EJ. Síndrome de Ohtahara: casuística de 10 años en el Hospital Infantil de México Federico Gómez. *Rev Med Hondur* 2007;75:182-185.
- Saito H, Kato M, Mizuguchi T, Hamada K, Osaka H, Tohyama J, et al. De novo mutations in the gene encoding STXBP1 (MUNC18-1) cause early infantile epileptic encephalopathy. *Nat Genet* 2008;40:782-788.
- Thambyayah M. Early epileptic encephalopathies including West syndrome: a 3-year retrospective study from Klang Hospital, Malaysia. *Brain Dev* 2001;23:603-604.
- Ohtahara S, Yamatogi Y. Epileptic encephalopathies in early infancy with suppression-burst. *J Clin Neurophysiol* 2003;20:398-407.
- Fusco L, Pachatz C, Di Capua M, Vigeveno F. Video/EEG aspects of early-infantile epileptic encephalopathy with suppression-bursts (Ohtahara syndrome). *Brain Dev* 2001;23:708-714.
- Beal JC, Cherian K, Moshe SL. Early-onset epileptic encephalopathies: Ohtahara syndrome and early myoclonic encephalopathy. *Pediatr Neurol* 2012;47:317-323.
- Ohtahara S, Ohtsuka Y, Yamatogi Y, Oka E. The early-infantile epileptic encephalopathy with suppression-burst: developmental aspects. *Brain Dev* 1987;9:371-376.
- Bastos H, Sobral da Silva PF, Veloso de Albuquerque MA, Mattos A, Santos RR, Ohlweiler L, et al. Proteus syndrome associated with hemimegalencephaly and Ohtahara syndrome: report of two cases. *Seizure* 2008;17:378-382.
- Hmaimess G, Raftopoulos C, Kadhim H, Nassogne MC, Ghariani S, de Tourchaninoff M, et al. Impact of early hemispherotomy in a case of Ohtahara syndrome with left parieto-occipital megalencephaly. *Seizure* 2005;14:439-442.
- Raspall M, Ortega-Aznar A, del Toro M, Roig M, Macaya A. Neonatal rigid-akinetic syndrome and dentato-olivary dysplasia. *Pediatr Neurol* 2006;34:132-134.