

CLINICOPATHOLOGICALCASE

Laryngotracheal stenosis

Carlos Rafael Bañuelos Ortiz,¹ Gustavo Teyssier Morales,² Rosa Delia Delgado Hernández,³
Carlos Alberto Serrano Bello⁴

SUMMARY OF THE CLINICAL HISTORY (A-09-65)

We present the case of a male patient, 2 years 11 months of age, with burns due to scalding when he accidentally tipped a pot of boiling water (pot with corn) on his head, anterior and posterior trunk, and extremities.

Family history. The mother is 32 years of age. She is a local vendor, uneducated, Catholic by religion, and reported having epilepsy treated with carbamazepine. The father is 25 years of age, a local vendor not living within the nuclear family. His past medical history is unknown. The patient has two healthy brothers aged 4 and 3 years.

Non-medical history. The patient is from, and a resident of, Acatzingo, Puebla. He lives in a rented house that has all basic urban services. There is a septic tank. The house has only one bedroom. There are four persons living in the house, indicating overcrowding. Promiscuity is denied. Normal hygienic habits are reported.

Nutrition. The patient was fed breast milk during the first year of life and was weaned at 6 months of age with fruits and vegetables, later being integrated into the family diet at 12 months of age. At present, a normal diet without restrictions is reported.

Psychomotor development. The following were reported: social smile at 3 months, gaze fixation at 1 month, head support at 3 months, sitting at 8 months, walking

at 12 months. Articulation of words, but not phrases, is reported. The patient does not yet have sphincter control.

Immunizations. The patient is still awaiting the first dose of DPT.

Perinatal and medical history. The patient is the product of G IV, normal pregnancy with prenatal care from the third month of pregnancy, with six prenatal visits. Intake of folic acid and ferrous sulfate was reported from the first visit. Third trimester USG was reported as normal. The patient was a full-term vaginal birth at the hospital. Weight, height and Apgar score were unknown. The patient had an immediate cry and respiration at birth. Neonatal complications were denied.

MAY 13, 2009. The patient received scalding burns when a boiling pot (pot with corn) accidentally was emptied on his head, anterior and posterior trunk, and extremities, with second degree superficial and deep burns covering 30% of his body surface. He received care in the General Hospital of Puebla for 2 days and experienced cardiorespiratory arrest (reported by the mother). A modified Galveston scheme was administered with debridement and aminergic support (dobutamine and epinephrine). Severe respiratory difficulties were reported. There was suspicion of liquid aspiration. For this reason the patient was intubated. A dermatomy was performed due to neurovascular compromise of the left hand. The mother reported a fall of one meter in height in the hospital where he was first seen. He was referred to the Pediatric Hospital of Tacubaya for continued management.

MAY 15, 2009–AUGUST 9, 2009. The patient was admitted to the Pediatric Hospital at Tacubaya where he was managed with analgesics and sedation (nalbuphine, paracetamol, ketorolac and metamizol). He required management with amines (dobutamine for 9 days and epinephrine for 4 days) due to data of low cardiac output. He received assisted mechanical ventilation for 13 days.

¹ Departamento de Urgencias
² Departamento de Cirugía de Tórax y Endoscopia
³ Departamento de Radiología
⁴ Departamento de Patología

Hospital Infantil de México Federico Gómez
México D.F., México

Received for publication: 4-2-13
Accepted for publication: 4-25-13

MAY 16, 2009. The patient experienced a right tension pneumothorax secondary to subclavian catheter placement and a pleural miniseal was placed.

MAY 21, 2009. Right apical pneumonia was reported associated with the ventilator with right pleural effusion. Management was initiated with vancomycin and imipenem.

MAY 29, 2009. Extubation was scheduled. The patient had stridor and respiratory difficulty that were controlled with inhaled steroids. This clinical picture was seen on two more occasions, the last without response to inhaled steroids or racemic epinephrine. Therefore, he was reintubated.

JUNE 16, 2009. Reintubation was done with a 4-mm (internal diameter, ID) catheter (previous one was 5 mm). Narrowing of the airway was found. For this reason the patient was referred to the Thoracic Surgery Department of the Hospital Infantil de Mexico Federico Gomez (HIMFG).

There were multiple infections reported in cultures with growth of methicillin-resistant *S. aureus* (MRSA) in central blood culture, secretion culture positive for *Acinetobacter*; orotracheal cannula tip with *E. cloacae*, catheter tip positive for *Pseudomonas aeruginosa*, secretion positive for *Candida*, left ear secretion positive for *P. aeruginosa*, urine culture positive for *E. coli*, occipital eschar with growth for *E. coli*, catheter tip point positive for *C. albicans*. Due to the former, during his hospital stay he received treatment with ampicillin (5 days), amikacin (5 days), dicloxacillin (5 days), imipenem (10 days), vancomycin (10 days), ciprofloxacin (10 days) and tobramycin (10 days).

Several surgical procedures were performed due to the burns. Because of the presence of compartment syndrome of the left hand, the following were carried out: dermatomy of the left hand (5/15/09), central venous catheter placement to the right internal jugular (5/24/09), placement of Epifast (5/29/09), graft harvesting and placement (6/5/09, 6/25/09, 7/1/09, 7/14/09, 7/28/09), dermatomy of the left upper extremity (7/6/09), bone curettage, and VAC placement (7/10/09). The patient was discharged from the Hospital Pediatria de Tacubaya on 8/9/09 with a tracheostomy, management with rifocyne in the donor areas every 24 h, lubrication of wounds with sweet almond oil and outpatient plastic surgery consultation for 8/14/09 and for rehabilitation.

JUNE 19-20, 2009 (THORACIC SURGERY). The patient at 2 years of age, weight 13 kg, height 85 cm is seen for the

first time in the HIMFG for evaluation. A tracheostomy was performed without complications, placing a 4-mm Portex cannula. Vocal cords were normal and there was an anterior and posterior ulcer at the level of the anterior commissure with discrete decrease in the tracheal lumen. The patient was admitted to the Surgical Intensive Care Unit (SICU) for postsurgical monitoring, with mechanical ventilation support 11 h with successful removal from the ventilation with supplemental O₂ at 5 l/min, FiO₂ 60%, with SpO₂% >95%. Management was begun with analgesia and antibiotic prophylaxis. The patient remained at the HIMFG for 24 h and was re-transferred to the Pediatric Hospital in Tacubaya with an appointment for a new laryngoscopy.

JULY 24, 2009 (THORACIC SURGERY). A laryngotracheostomy was performed. A normal epiglottis and arytenoids were observed with discrete inflammation, glottis with mild inflammation of the lateral walls, vocal cords with good mobility, and with effacement due to inflammation. In the subglottic space there was stenosis of 70% in an elliptical shape in transverse position, able to be passed with a 4-mm optic. In the trachea a small peristomal granulation was observed that occluded 10% of the tracheal lumen. Main bronchi were normal. Bronchus IDx was 70% subglottic stenosis Cotton 3. The patient was scheduled for an appointment in 2 months.

SEPTEMBER 23, 2009 (THORACIC SURGERY). Bronchoscopy. Subglottic stenosis was observed borderline with the trachea with elliptical shape and transverse position, with decrease in the airway of 65-70%. There was a very small granuloma in the tracheostomy stoma. A tracheoplasty was scheduled.

Current disease. The patient was scheduled for a second admission to HIMFG for a tracheoplasty. On physical examination he was noted to be active, reactive, with adequate hydration and skin color and turgor, grafts without compromise, permeable tracheostomy cannula and cardiopulmonary, abdomen and extremities without any alterations. Preoperative management was NPO, base solutions 1500/2:1/30, cephalotin 50 mg/kg/dose.

Laboratory and imaging studies. The following were reported: hemoglobin (Hgb) 13.4 g/dl, hematocrit (Hct) 40%, platelets (Plat) 538,000, leukocytes (Leu) 11,700 U/l, segments (Seg) 44%, lymphocytes (Lymph) 46%, monocytes (Mon) 7%, prothrombin time (PT) 11.8 sec, partial thromboplastin time (PTT) 24.8 sec, INR 0.92.

December 10, 2009. Tracheoplasty and cricotracheal resection were done. Transsurgical findings were stenotic areas in the cricoid without involvement of the glottic space. Distal trachea was of normal caliber. The prior tracheostomy stoma was resected. A laryngofissure was performed and a "triangle" was left on the anterior face of the trachea for the anastomosis. A stent was placed and a new tracheostomy was performed with a 4.0 cannula. A subclavian venous catheter was placed. Surgical time was 3 h. The patient continued to surgical therapy with the following management: fasting, base fluid 1800 ml/m² SC/day, potassium 30 mEq/m² SC/day, calcium gluconate 100 mg/kg/day, magnesium sulfate 50 mg/kg/day, cephalotin 100 mg/kg/day, ranitidine 1 mg/kg/dose c/8 h, vitamin K 0.3 mg/kg/day, midazolam 4 µg/kg/min, fentanyl 2 µg/kg/h, paracetamol 15 mg/kg/dose.

Laboratory and Imaging Studies. The following were reported: sodium (Na) 139 mEq/l, potassium (K) 3.7 mEq/l, chlorine (Cl) 108 mEq/l, calcium (Ca) 8.0 mg/dl, phosphorus (P) 4.7 mg/dl, glucose (Gluc) 117 mg/dl, urea nitrogen (BUN) 10 mg/dl, creatinine 0.2 mg/dl, total bilirubin (TB) 0.19 g/dl, direct bilirubin (DB) 0.04 g/dl, indirect bilirubin (IB) 0.15 g/dl, T protein (TP) 5.4 g/dl, albumin (Alb) 2.9 g/dl.

December 11-15, 2009. The patient remained in the SICU under monitoring. Assisted mechanical ventilation was removed, supplemental oxygen was administered. Midazolam/fentanyl were discontinued and the patient was begun on buprenorphine (8 µg/kg/day). Due to the presence of two fever spikes, maximum of 38.3 °C, clindamycin/amikacin was begun. After this, he was afebrile, without systemic inflammatory response. Oral feeding was begun.

DECEMBER 14, 2009. The patient was transferred to the floor.

Laboratory and Imaging Studies. The following were reported: hemoglobin (Hgb) 11.1 g/dl, hematocrit (Hct) 32.8%, platelets (Plat) 403,000, leukocytes (Leu) 14,900 U/L, segments (Seg) 85%, lymphocytes (Lymph) 5%, bands (Ban) 9%.

DECEMBER 16, 2009 (THORACIC SURGERY). The stent was removed with alligator clamp on the first attempt and without complications. The larynx demonstrated inflamed vocal cords, subglottic space with presence of films at the site of the stent, granular appearance of the mucosa, tracheostomy and distal trachea without alterations. Time of

anesthesia was 25 min. Premedication used was atropine. Induction was with propofol. Maintenance was with sevoflurane. The patient was admitted to the floor at 14:00 h. Normal diet was begun with removal of base solutions.

20:30 h. The patient presented cyanosis, cardiopulmonary arrest, and volume increase in the bilateral cervical region with subcutaneous emphysema in the head, neck, chest and abdomen. An endotracheal tube was placed (ID 4 mm) at the site of the tracheostomy. There was much resistance to the ventilation in both hemithorax; therefore, two miniseals were placed and, after that, bilateral pleural catheter with air output. With this the resistance to the ventilation decreased. Intake and output of air was auscultated. Resuscitation maneuvers were given for 40 min with five doses of adrenaline, bicarbonate, and physiological solution boluses without response. No family members were present in the area.

21:00 h, Blood Gases. The following were reported: pH 6.45, PaO₂ 54.2, PaCO₂ 127, HCO₃ 8.3, EB -33.8, SatO₂ 36.7%, Lact 24.

CASE PRESENTATION

(Dr. Gustavo Teyssier Morales)

The patient who is presented in this case is a 2 year, 11 months of age male at the time of his admission. The patient was originally from Acatzingo, Puebla. There is no relevant family history. He is the product of healthy parents. Psychomotor development was adequate for his age. He had a complete vaccination schedule. He is the G IV product of an uneventful pregnancy with adequate prenatal care. Labor was in the hospital without perinatal complications.

In May 2009, at 2 years 7 months of age, the child suffered scalding burns covering 30% of his total body surface involving the head, trunk and extremities. For this reason he was admitted to a second-level hospital where he suffered cardiopulmonary arrest. He was orotracheally intubated with mechanical ventilatory support and begun on vasopressor medications due to the state of shock. He was maintained intubated for 13 days. During this period of time he presented various complications. Among them, pneumothorax secondary to central venous catheter placement and pneumonia associated with the ventilator with pleural effusion. He was extubated in a programmed fashion. Later, he began to have stridor and respiratory

difficulty. He was managed in the original hospital with micronebulizations, racemic epinephrine and steroids. Initially he was observed to have an apparent improvement; however, the clinical picture recurs on two occasions, and he was finally reintubated. The period that transpired between the extubation and the reintubation is not clear. Reintubation was done with a 4-mm ID endotracheal tube. He was initially intubated with a 5-mm ID orotracheal tube because during laryngoscopy he was noted to have narrowing of the airway.

It is important to comment on some aspects to take into account whenever we have a patient with history of prolonged intubation. It is not uncommon that a patient, after an event of instrumentation of the airway, will have inflammation and mucosal edema at the level of the glottic and subglottic structures. It is a transient picture referred to as postextubation croup characterized by laryngeal stridor and ventilatory difficulty. With management using vasoconstrictors and inhaled and systemic anti-inflammatories there is generally rapid evolution towards improvement with disappearance of symptoms. One must exercise caution when a patient persists with symptoms despite treatment. One must take into account the duration of the period of intubation, whether the patient had multiple extubations and re-intubations, if the caliber of the endotracheal tube used was adequate, and if there was appropriate care of the endotracheal tube. When one has a patient with a history of prolonged orotracheal intubation who presents with stridor, mainly biphasic, and has not progressed adequately, one must always consider the possibility of damage to the laryngeal structures secondary to the intubation event. Laryngoscopy and bronchoscopy will always be indicated in these patients.

On June 19, 2009 the patient was referred to the Department of Thoracic Surgery and Endoscopy of the HIMFG for laryngoscopy and bronchoscopy. There were ulcers found in the anterior and posterior commissures of the glottis with mild narrowing of the tracheal lumen. At this time a tracheostomy was performed due to the possibility of developing subglottic stenosis and because of the impossibility of extubation. He was transferred to the intensive care unit for postoperative management. Mechanical ventilatory support was removed 11 h after the tracheostomy is performed. Twenty-four hours later he was referred back to the hospital of origin for continuation of burn treatment. During his stay in the hospital of origin, he

had multiple episodes of infections: catheter-related sepsis, urinary tract infections, and perforated acute otitis media. Multiple surgical procedures were carried out such as dermatomies and fasciotomies. Finally, he was discharged to home on August 9, 2009 with outpatient appointments with plastic surgery, rehabilitation and thoracic surgery in HIMFG. On July 24, almost 1 month after the first laryngoscopy, a new endoscopic study was performed where a normal epiglottis was seen. The glottis was still inflamed and the vocal cords were effaced by edema but with adequate mobility. Also observed was stenosis of the subglottic space of 70%, which corresponds to grade III of the Cotton-Myers classification. This stenosis was elliptical in shape and in transversal position. He also had a peristomal granuloma that occluded 10% of the tracheal lumen. It must be emphasized at this point that the subglottic stenosis is not a pathology that we frequently observe at the time of extubation as the endotracheal tube functions as a cap that maintains the subglottic space open during the first hours or days after extubation, such as occurred in this patient in whom no stenosis was observed during the first laryngoscopy. What is generally seen at the time of extubation is inflammation and lesions (ulcers or zones of cartilage exposure) that suggest that the patient is at risk of developing glottic or posterior subglottic stenosis. Because of this, the tracheostomy was done at the time of the first laryngoscopy. The final stenotic lesion can be seen up to 3 weeks after the intubation event. In this patient, because inflammation was still found in the glottic structures at the time of the second laryngoscopy, it was decided to perform a third laryngoscopy 3 months later to rule out the glottic or subglottic stenosis. On September 23 a third laryngoscopy was performed where it was demonstrated that the subglottic damage did not progress. The patient continued with grade III stenosis without involvement of the glottis. For this reason the family was consulted and it was decided to perform a laryngotracheal reconstruction. On December 19 the patient was scheduled to be admitted for surgery. Preoperative studies were reported to be normal, with a hemoglobin of 13 g/dl, 11,700 leukocytes/mm³, with normal differential, coagulation times and platelets. On December 10 a laryngotracheal reconstruction was carried out. During reconstruction, the anterior face of the cricoid cartilage was resected, which houses the subglottic space (zone of stenosis). The scarred mucosa was completely resected along with three tracheal rings

(which included the tracheal stoma). Finally, tracheal anastomosis with the thyroid cartilage from a healthy area was performed. A new tracheostomy tube was done for security. Surgical time was 3 h and there were no perioperative complications. The patient was discharged to the surgical intensive care unit sedated and relaxed. Mechanical ventilatory support via the tracheostomy cannula was discontinued during the first 24 h after the surgery and oral feeding was begun. The patient had two fever spikes during the postoperative period of up 38.3°C. The antimicrobial scheme was changed to clindamycin and amikacin. Despite this, his progress during his stay in the surgical intensive care unit was favorable. Five days after the surgery a control laryngoscopy was performed to remove the laryngeal prosthesis, which was left during the surgery. That day, blood studies reported 14,900 leukocytes, 85% segments, 9% bands and 300,000 platelets. However, the patient remained afebrile without a clinical picture of systemic inflammatory response. During the endoscopic study, the prosthesis was removed and the larynx was noted to have inflamed vocal cords. The subglottic space was permeable but with a fibrin layer at the site where the prosthesis had been placed. The mucosa had a granular appearance due to inflammation, and the tracheostomy and distal trachea were observed to be without changes.

At 2 PM on that same day, the patient was discharged to the thoracic surgery room. Oral feeding was reinitiated and solutions were discontinued. At 8:30 PM he had cyanosis, sudden cardiopulmonary arrest, increase in volume in the cervical region, and subcutaneous emphysema of the head, neck, chest and abdomen. As an emergency measure the tracheostomy cannula was removed and an endotracheal tube was placed through the tracheal stoma, after which he demonstrated much resistance to the ventilation. Pleural catheters were placed. However, there was no response to the resuscitation maneuvers and after 40 min they were stopped.

In this case one must consider two fundamental situations: first, in a patient with a tracheostomy who presents cyanosis and sudden ventilatory difficulty one must consider its malfunction, whether due to obstruction or accidental decannulation. In this situation one must always keep in mind that the objective is to ventilate the patient by any means, not necessarily through the tracheostomy. We must remember that because this was a recently done tracheostomy (the patient had 6 days from being operated), a

tracheocutaneous fistula had not yet formed, which would allow the easy insertion of the tube through the tracheal stoma. Therefore, there is a great possibility of forming a false route outside the trachea. On the other hand, in patients with subglottic stenosis, obstruction of the upper airway makes that, in cases of accidental decannulation or obstruction of the cannula, ventilation through the mouth, whether with a mask or orotracheal intubation, to be impossible. The same occurs in operated patients who still have the laryngeal prosthesis in the subglottic space. Therefore, the only method of ventilating these patients is through the tracheal stoma. In this patient, because of the recent laryngeal surgery orotracheal intubation was very risky because it is possible to cause a dehiscence of the anastomosis with the tube. For this reason, the decision was probably made to intubate through the tracheal stoma, even though it was of recent elaboration. The inability to adequately ventilate the patient and the sudden appearance of generalized emphysema suggests that there was not adequate recanalization of the trachea, creating a false route and triggering a fatal event.

The second possibility that is evident is dehiscence of the thyrotracheal anastomosis. It was mentioned that at the time of the laryngoscopy some fibrin films were observed within the subglottic space, which could suggest an infection at the level of the site of the anastomosis or perhaps these films may have hidden some small dehiscence not seen on the laryngoscopy. Anastomotic dehiscence of the airway generally does not occur suddenly in the total circumference of the anastomosis. These begin with a small leak that produces progressive local emphysema. Occasionally, it can progress rapidly to generalized subcutaneous emphysema. In this case it would have had to have been a very large dehiscence in order to cause such a catastrophic evolution.

In any of these situations, it is logical to think that the final scenario was that of the total or partial dehiscence of the thyrotracheal anastomosis, whether by a primary failure of the anastomosis or secondary to the manipulation during the recanalization of the tracheal stoma and cardiopulmonary resuscitation. The final diagnoses are as follows:

- Thyrotracheal anastomosis dehiscence
- Postoperative laryngotracheal reconstruction
- Grade III subglottic stenosis (Cotton-Myers)
- Scalding burn covering 30% of the body surface

Imaging

(Dra. Rosa Delia Delgado Hernández)

On the x-ray of 10/12/09, the tracheostomy cannula is observed as well as the tip of the central catheter in the right atrium and nasogastric tube (Figure 1). The thymus is of adequate size. The pericardial silhouette shows a discrete dilatation of both ventricles. Cephalization of pulmonary vascular flow is more evident for the left hilum. There is elevation of the right hemidiaphragm secondary to hepatomegaly.

Imaging done on 11/12/09 shows the tracheostomy cannula and a thymus of adequate size. The pericardial silhouette shows a discrete prominence of the superior vena cava and the right atrium. There is discrete cephalization of the pulmonary vascular flow. Hepatomegaly is noted.

Imaging of 12/14/09 shows the tracheostomy cannula added to the reservoir. The pericardial silhouette shows a discrete prominence of the superior vena cava and the right atrium. A radiopaque lesion is seen on the right upper lobe compatible with atelectasis. Hepatomegaly is noted.

Pathology Service

(Dr. Carlos Alberto Serrano Bello)

Anatomopathological Findings. This is the case of a male patient with the reported age similar to the chronolo-

gical age with normal development. There are burn zones in the process of re-epithelialization on the lateral face of the abdomen, chest, neck, arms, forearms and thighs. He also presented a tracheostomy wound of 2 x 2 cm and a

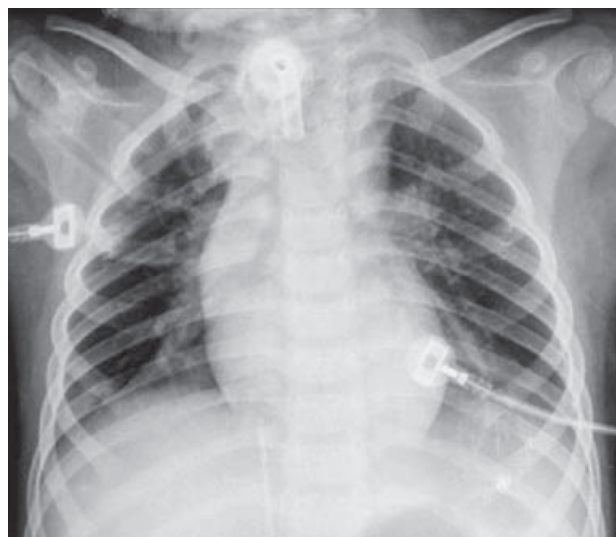

Figure 2. Tracheostomy cannula. Presence of thymus of adequate size. The pericardial silhouette shows discrete prominence of the superior vena cava and right atrium. Discrete cephalization of pulmonary vascular flow. Hepatomegaly.

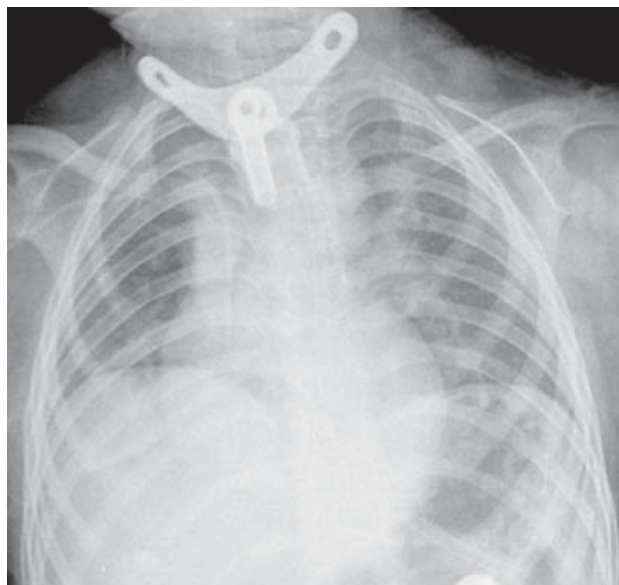


Figure 1. Tracheostomy cannula. Tip of central catheter in the right atrium. Nasogastric catheter. Presence of adequate-sized thymus.

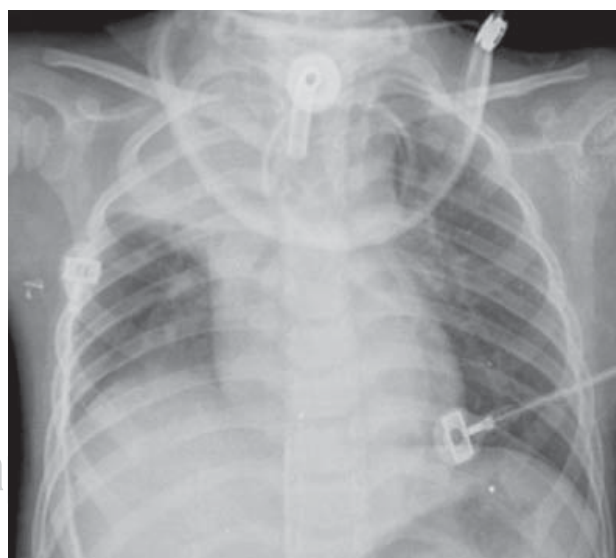


Figure 3. Tracheostomy cannula coupled with reservoir. The pericardial silhouette shows discrete prominence of the superior vena cava and right atrium. Radiopaque lesion in right upper lobe compatible with atelectasis. Hepatomegaly.

secondary wound below that, with 1.3-cm sutured margins (Figure 4).

On neck dissection, the trachea presented absence of the second and third cartilage with presence of sutures, which were found to be dehiscenced (Figure 5).

On histological cuts, the tracheal mucosa was observed completely ulcerated with loss of epithelium and an

extensive inflammatory infiltrate constituted for the most part by neutrophils. The infiltrate extended up to the peritracheal soft tissues and to the cartilage where a recent hemorrhage was observed as well. No microorganisms were observed (Figure 6).

Histologically, the tracheostomy demonstrated mucosal ulceration with polymorphonuclear inflammatory infiltrate without evidence of microorganisms. Upon opening

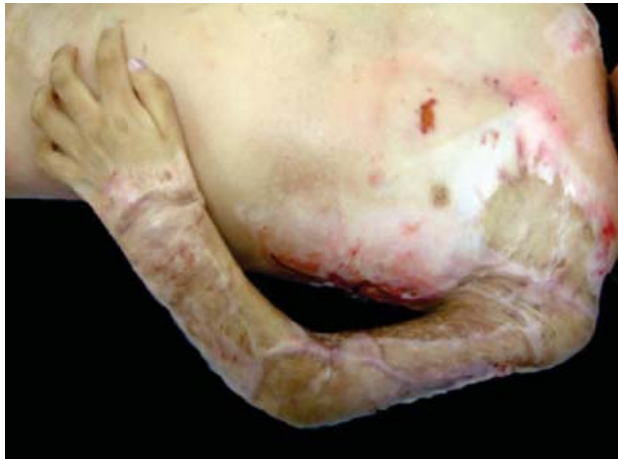

Figure 4. Areas of re-epithelialized burns on the anterior chest and extremities.

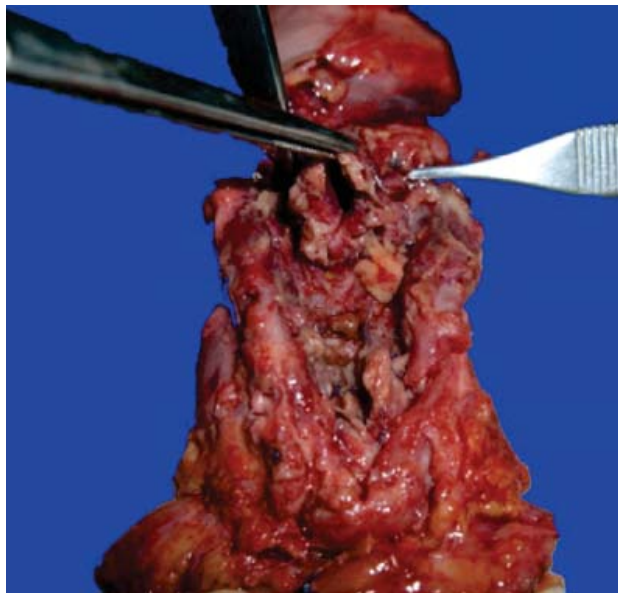


Figure 5. Dehiscence of the tracheoplasty with abundant fibrin at the margins is observed.

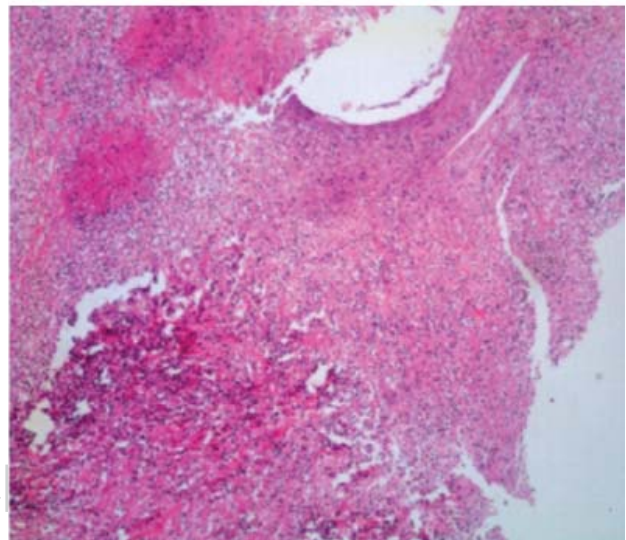
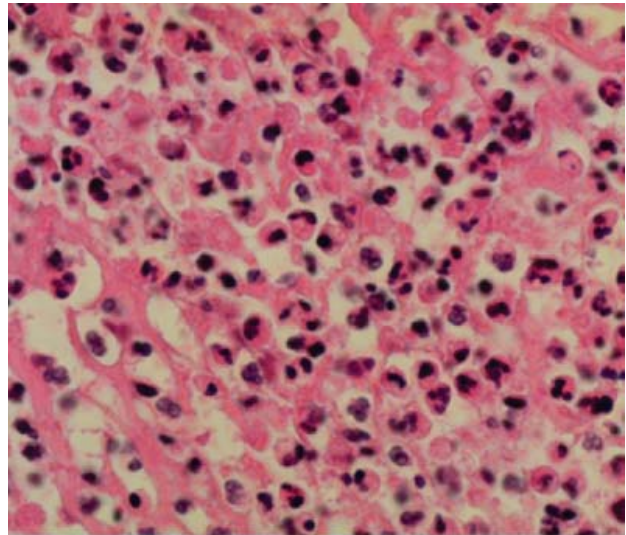


Figure 6. Histological section stained with hematoxylin-eosin (HE), which corresponds to the margins of the tracheoplasty (dehiscence) where intense inflammatory infiltrate is identified constituted by neutrophils and fibrin. Healthy viable tissue is not identified.

the thoracic cavity, a hematoma on the anterior mediastinum was observed, which involved the thymus (Figure 7). The heart was morphologically without alterations. Histological cuts showed subendocardial zones of rare fibrosis. The remainder of the myocardium showed signs of shock.

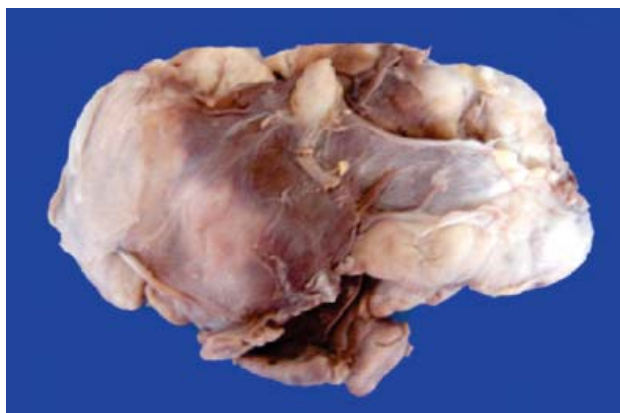


Figure 7. Macroscopic photography making evident the hematoma in the mediastinum affecting the thymus.

The lungs showed multiple bilateral areas of congestion and hemorrhage which, on histological cuts, corresponded to areas of recent intraalveolar edema and hemorrhage. Also observed in other areas was necrosis of the pneumocytes with formation of hyaline membranes that corresponded to a shocked lung. In other areas there was presence of giant multinucleated cells and plasma-lymphocyte inflammatory infiltrate that corresponded to a chronic pneumonitis due to aspiration (Figure 8).

Upon opening the abdominal cavity, the stomach presented flattening of the mucosal folds with areas of congestion. Macroscopically, the esophagus was without alterations. On histological cuts, rare mononuclear inflammatory infiltrate was observed in the superficial epithelium and contraction bands on the muscular layers. The small intestine and the colon also demonstrated flattening of the mucosal folds and contraction bands due to sustained hypoxia. The pancreas presented a homogeneous parenchyma with histological changes of shock. The liver demonstrated

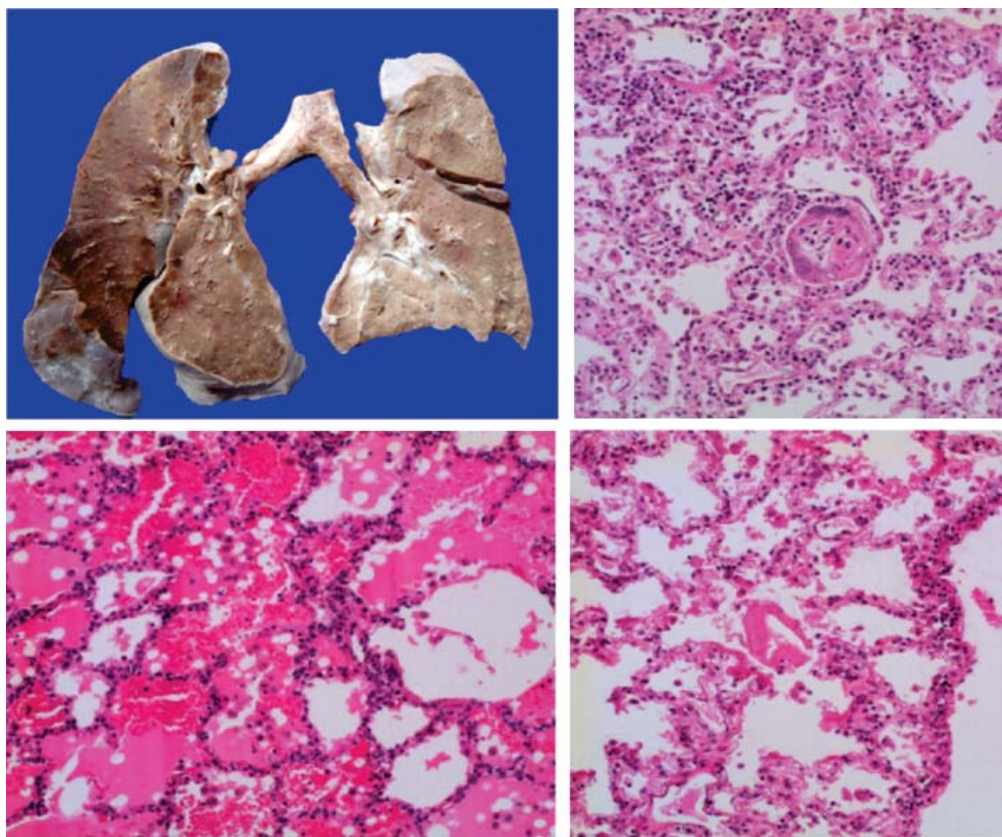


Figure 8.

Above left, a section of the lungs is identified that shows parenchyma with areas of hemorrhage and congestion, mainly basal. Above right, a histological section where giant multinucleated cells of a foreign body are identified. Below left, extensive areas of intraalveolar hemorrhage are noted. Below right, formation of small hyaline membranes.

a brown homogeneous surface, and histological cuts showed dilatation with stasis of erythrocytes on the sinusoids. The spleen, similarly, demonstrated sinusoidal congestion.

The kidneys presented discrete lobulation with parenchymal congestion and adequate cortex-medulla ratio. Histologically, they presented necrosis of the tubular epithelium with formation of focal calcifications within. These changes correspond to acute tubular necrosis and nephrocalcinosis, similar to that observed in states of shock (Figure 9).

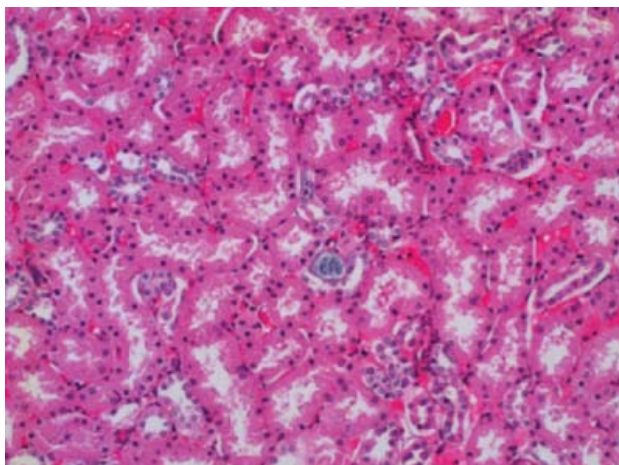


Figure 9. Histological section with HE stain where necrosis of the tubular epithelium is seen with formation of calcifications.

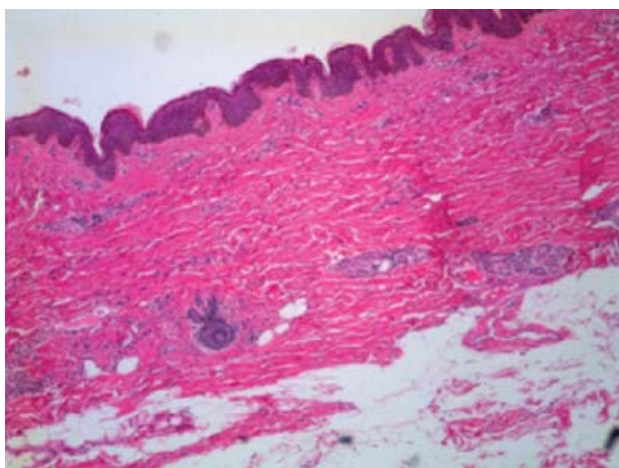


Figure 10. Histological section of skin showing fibrosis of the dermis with bands of thick collagen, which corresponds to a scar.

In the areas of skin burns there were regenerative changes, which consisted mainly in hyalinization of the dermis with fibrosis (Figure 10).

The skull showed congestion of meningeal vessels. On cut, there were areas of vascular congestion and histological changes of tissue hypoxia characterized by clear perineuronal halos.

According to the findings previously described, we can conclude with a principal diagnosis of 70% subglottic stenosis secondary to chronic intubation precipitated by second- and third-degree burns covering 30% of the body surface. The patient had tracheoplasty, which was complicated by dehiscence of the tracheal anastomosis causing a cervical hematoma that extended to the mediastinum. As concomitant alterations, the patient presented chronic pneumonitis due to aspiration with focal fibrosis of the right pulmonary lobe, anatomic data of shock with diffuse alveolar damage, ischemic-hypoxic visceral myopathy, acute tubular necrosis, nephrocalcinosis and hepatic and splenic congestion. According to these findings, it can be considered that hypovolemic shock due to hemorrhage in the neck was the cause of death.

Final Comments

(Dr. Carlos Rafael Bañuelos Ortiz)

This case results in various useful points for discussion. The first of which is when one should suspect the presence of an acquired subglottic stenosis. Obviously, the history necessary for the diagnosis is prior orotracheal intubation, which causes laryngotracheal stenosis in >90% of the cases. In infants and preschool-age children, the lesions caused by the intubation are manifested as failed extubation. In school-age children and adolescents the only symptom may be the presence of dysphonia. As a general rule, a failed extubation or persistent dysphonia for 3 days after extubation is a mandatory indication for an endoscopic evaluation of the larynx and the subglottic space. If the lesion is not sufficiently severe, the development of a subglottic stenosis is to be expected 3 to 6 weeks after extubation. In this case, the predominant symptoms are persistent or intermittent stridor and respiratory difficulty triggered or exacerbated by acute inflammatory processes.

The incidence of postintubation stenosis is variable with reports from 0.9 to 3%. The factors that predispose the development of postextubation stenosis are related with the patient, the endotracheal tube (ET), intubation techni-

que and the postintubation care provided in the pediatric intensive care unit. The presence of hypoperfusion (state of shock, anemia and sepsis), gastroesophageal reflux or infections may exacerbate the damage caused by the ET tube on the mucosa. Other factors include age (less risk in infants than in adolescents), condition of the larynx (small larynx, anatomic abnormalities, infection), abnormalities in scarring, immunosuppression, diabetes, and bronchopulmonary dysplasia. The duration of the intubation was previously considered to be a principal factor; however, it is now believed to be another predisposing factor that should be considered with other risk factors. At present, in the neonatal age as in the pediatric age, intubation can be maintained for weeks without significant laryngeal sequelae, if and when the other factors are controlled. However, the risk of laryngotracheal stenosis is increased after 4 weeks of intubation. The factor of greatest impact seems to be the size of the ET tube. Other influencing characteristics are the rigidity of the tube and poor biocompatibility. On introducing the ET tube, pressure is exercised on the posterior glottis over the mucosa of the surrounding tissues. The larger the tube size, the greater will be the risk of using more pressure. When the pressure of the ET tube surpasses the pressure of the capillary perfusion (≈ 20 – 40 mmHg) ischemia with progression to necrosis is produced. The characteristic data of this lesion are the presence of edema, mucosal erosions and ulcerations with exposure of the perichondrium and adjacent cartilage. The degree of ischemia-necrosis is the most important factor related to the sequelae, even in intubations of 48–72 h. The related superinfection with prolonged intubation increases the severity of the perichondritis and cartilage necrosis. The tracheostomy performed at this time worsens the situation by increasing the colonization of the airway. After the lesion, granulation forms at the edges of the wound, which favors re-epithelialization.

On having a greater growth than the epithelium, the granulation tissue causes the obstruction of the airway with later formation of scar tissue. An important point to rule out is the use of the ET tubes with balloon (or handle). Since 2005, the American Heart Association recommended that these types of tubes could be used in children <8 years of age. In fact, the present recommendation is that they can be used from 1 month of life, mainly or preferentially in situations in which the use of elevated inspiratory pressures or the use of positive end expiration pressure

is expected to be high. However, it is recommended that the pressure of the inflation be monitored, i.e., from 20–25 cmH₂O and that the balloon be desufflated daily for 1–2 h to decrease the pressure on the tracheal mucosa and, with it, the risk of ischemia-necrosis. In addition to the duration of the intubation, the fact of it being multiple or traumatic conditions the risk for the development of sequelae. A traumatic intubation could be due to anatomic differences that make the intubation difficult or due to the lack of experience by the personnel who carry out the procedure. Other influencing factors are the use of a large orotracheal tube (inadequate for the age), inadequate sedation-relaxation, and presence of congenital stenosis as well as an inadequate intubation technique. Finally, factors associated with the care of the patient who is already intubated, such as inadequate sedation, traumatic and repetitive aspirations, and the presence of nasogastric catheter or movement of the tube caused by inadequate fixation of the ventilator and circuit that will cause greater movement of the tube and risk of injury. It is important to point out that the presence of various factors will result in that the injury will be sufficiently significant such as to cause a laryngotracheal stenosis.

During the discussion of the case at the clinical pathology meeting it was commented that, in the HIMFG, dilations in cases of subglottic stenosis are no longer performed due to the low success rate reported worldwide, as well as to the risk of complications of the procedure. For this reason, the decision is made to perform tracheoplasty in these situations.

The complications that are seen associated with this procedure are several. One of them, which this patient presented, is atelectasis. The patient was administered medical treatment, and later a bronchoscopy was carried out to remove the stent. Obviously, the inspiratory positive pressure was managed with what was expected would have resolved the atelectasis. However, a control x-ray was not obtained afterwards which, to my way of thinking, was an error and could have conditioned the later respiratory difficulty (atelectasis). Other complications include pneumonia or bronchospasm, which require the administration of antibiotics or bronchodilators, respectively. The most feared complications are dehiscence of the anastomosis, injury to the recurrent laryngeal nerve and late recurrent stenosis. Dehiscence of the anastomosis is rare. Monnier et al. reported in their series 6/108 cases of dehiscence (5.6%).¹ In

the HIMFG, Dr. Jaime Penchyna et al. (unpublished data) reported an incidence of 3/115 cases of dehiscence (2.6%) with only one fatality. It is reported in the literature that this complication usually presents itself after the tenth day.² In this case it presented itself on the sixth day. A perfect approximation of the mucosa at the site of the anastomosis without fibrin deposit is unlikely to evolve into a separation of the anastomosis. On the other hand, fibrin deposits may represent an incipient separation of the anastomosis: some may scar completely, whereas others result in a late recurrent stenosis. In cases of chronic colonization of the airways with MRSA or *P. aeruginosa*, the risk of restenosis is greatly increased. In our environment the presence of MRSA is infrequent. Despite this, the usual protocol of the Thoracic Surgery and Endoscopy Department is to provide prophylaxis with clindamycin/amikacin in these types of surgeries. In the literature it is reported that these types of dehiscences never occur abruptly, but that they present incipiently or subtly. There is a biphasic stridor that should alert the physician due to the movement of the tracheal secretions to the level of the partially dehisced anastomosis. The neck may remain normal, but the presence of mucus may be observed at the level of the gauze covering the Penrose drain. Endoscopic and surgical evaluation should immediately be undertaken according to the case. Recurrent stenosis is produced from a partial dehiscence of the anastomosis that is produced progressively and slowly during a 3- to 6-week period. Similarly, the child will experience progressive dyspnea accompanied by biphasic stridor, requiring endoscopic or surgical evaluation.

In the case that is presented, the clinical history reports the sudden appearance of cyanosis, volume increase in the face, neck, chest and abdomen and cardiopulmonary arrest, initially with difficulty in ventilation, which improves after the resolution of the bilateral pneumothorax. If the arterial blood gas is analyzed, the oxemia for a state of zero flow shows us that, very probably, the intubation via the stoma was successful. If we review the findings of the endoscopy, the presence of inflammation and of fibrin film was reported at the surgical site. Also, there was fever noted on the days prior and a blood test showed leukocytosis in the upper limits for age, with neutrophilia and

9% immature bands. All of this suggests the presence of an infectious process at the site of the anastomosis, corroborated in the histological study where the tracheal mucosa was noted to be completely ulcerated with loss of the epithelium and inflammatory infiltrate that extended up to the peritracheal soft tissues and cartilage. Taking this into account, one can consider that there a dehiscence of the anastomosis, which was not created suddenly but rather in a relatively short period. It certainly must have gone unnoticed until the fatal event occurred: complete dehiscence. However, arterial blood gases are analyzed once again, showing a severe hyperlactatemic metabolic acidosis. This dehiscence produced a major hemorrhage (evidenced by a large hematoma on the anterior mediastinum in the histopathological study), which also caused a state of hemorrhagic shock that led to the patient's death.

In conclusion, it must be emphasized that the best way in which to avoid the outcome of this child is prevention. It is worth describing the conditions in which the majority of our country's population lives, notably the lack of a culture and policy of accident prevention both at home and as a pedestrian and with the use of vehicles. It goes without saying that the cause of the patient's problem was part of the "modus vivendi" of the family. During the discussion session the possibility of abuse due to negligence or omission was discussed; however, it is difficult to arrive at this conclusion due to the prevailing socioeconomic and cultural conditions of the family and that, unfortunately, are prevalent in our society.

Correspondence: Dr. Carlos Rafael Bañuelos Ortiz
E-mail: carlos_ban@hotmail.com

REFERENCES

1. Monnier P. Pediatric Airway Surgery. Management of Laryngotracheal Stenosis in Infants and Children. Berlin: Springer-Verlag; 2011. pp. 183-278.
2. Kleinman ME, Chameides L, Schexnayder SM, Samson RA, Hazinski MF, Atkins DL, et al. Part 14: Pediatric Advance Life Support: 2010 American Heart Association Guidelines for Cardiopulmonary Resuscitation and Emergency Cardiovascular Care. *Circulation* 2010;122(suppl 3):S876-S908.