

PEDIATRIC THEME

Importance of upper gastrointestinal series in children with gastroesophageal reflux

Wilver Ernesto Herrera García,¹ Ismael Lares-Asseff²

ABSTRACT

Midgut volvulus is a surgical emergency and occurs as a complication in patients with malrotation. The importance of an upper gastrointestinal (UGI) series in all patients with gastroesophageal reflux (GER) disease is to rule out any anatomic abnormality precipitated by GER. Of these abnormalities, "midgut volvulus" is the most catastrophic complication and occurs with intestinal malrotation and should be treated as a surgical emergency. Patients with intestinal malrotation present symptoms such as the following: gastric or bilious vomiting, GER, nausea, anorexia, abdominal distension or intermittent chronic abdominal pain, constipation, diarrhea, bloody stools, and stunted growth. However, some patients may not demonstrate any of the above symptoms or may be asymptomatic. Approximately 75% of patients with intestinal malrotation present features of GER disease or vomiting bile, but in the remaining 25% of patients, GER disease is characteristic of GI symptoms and may go unnoticed. In these patients, UGI series followed by intestinal transit remains the study of choice to rule out anatomic malformations or disorders of the digestive tract such as intestinal malrotation or volvulus.

Key words: upper gastrointestinal series, intestinal malrotation, volvulus, short bowel syndrome, gastroesophageal reflux disease.

INTRODUCTION

Historically, the usefulness of the upper gastrointestinal (UGI) study has been misinterpreted in patients with gastroesophageal reflux (GER). A diagnosis of GER with UGI study has been done. However, it is now known that GER is not diagnosed with UGI study because it has a very low sensitivity and specificity. For this reason, a 24-h pH measurement should be done, which is currently the gold standard for the diagnosis of GER.¹

That said, the UGI study continues to be essential during the initial study of pediatric patients with GER for one simple reason: the UGI series is the diagnostic study of choice for detecting anatomic abnormalities associated with GER, hiatal hernia, esophageal stricture, pyloric or

duodenal obstruction, tracheoesophageal fistula, some extrinsic vascular compression, etc. Above all, it helps to diagnose malrotation and prevent complications such as midgut volvulus, whose evolution is sudden and deadly without a timely diagnosis. UGI also helps to consider medical treatment or surgery.¹

Intestinal malrotation

Intestinal malrotation (IM) is a relatively common disorder with an incidence of 1/500 live newborns.²⁻⁴ IM could be defined as a failure in rotation and normal fixation of the mid-intestine during fetal development. It is a broad term that encompasses a great variety of anomalies of intestinal rotation and fixation, the diagnosis of which the clinical pediatrician, the pediatric surgeon and the radiologist play an important role because it often represents a true challenge as a result of the wide variety of clinical and radiological presentations. Malrotation of the mid-intestine could be characterized by congenital bands (Ladd's bands) that may obstruct the duodenum, duodenojejunal junction, ileocecal junction and the colon. The ligament of Treitz is the normal fixation point of the mesentery. It extends from the duodenojejunal junction of the angle of Treitz to the lumen, giving amplitude to the mesentery (Figure 1).

¹ Servicio de Cirugía
Hospital General de Ensenada
Baja California, México

² Instituto Politécnico Nacional CIIDIR
Unidad Durango, Durango, México

Received for publication: 5-15-13

Accepted for publication: 9-11-13

In patients with IM, the ligament of Treitz is not fixed in its normal location (Figure 2). Any abnormality in its location suggests mid-intestinal malrotation, which is characterized by a decrease in the amplitude of the mesentery, short mesentery and narrow base, a pedicle around the mesenteric vessels with a predisposition to intestinal torsion around this pedicle (torsion or volvulus causing intrinsic compression of the intestine, obstruction at the base of the pedicle and, if the torsion persists, occlusion of the mesenteric vessels, intestinal necrosis and death of the patient if its progress is left unchallenged). In patients with malrotation, the cecum is generally found in its normal condition, which is known as an incomplete malrotation. In cases of complete IM, the cecum is found in the hepatic angle or is localized to the left of the midline (Figure 3).⁴⁻⁷

Torsion of the poorly fixated intestine around its short mesentery is known as mid-intestinal volvulus, a very serious and catastrophic consequence of IM (Figures 4 and 5).^{4,7,8} Physiological GER is the presence of gastric content in the esophagus as part of a normal event of GI tract function without repercussions on the quality of life and without clinical consequences.¹

GER disease is a group of clinical disorders secondary to GER with direct consequences on the patient's health status.¹ Defined in a simple manner, pathologic GER is the consequence of excessive exposure of the esophagus to the gastric content. Vomiting is not always indicative of

pathological GER or is pathological GER always associated with the presence of vomiting.¹

The risk factors for GER include an increase in abdominal pressure, gastric distention, hiatal hernia and gastric or esophageal dysmotility, chronic relaxation of the gastroesophageal sphincter, prematurity with the immaturity of the inferior esophageal sphincter. Children with serious problems in neurological development or congenital anatomic anomalies of the GI tract are particularly at risk of suffering GER.⁹

The gold standard for diagnosis of GER has been 24-h monitoring because monitoring of intraesophageal pH for 24 h has a replication rate of 84% and 93%, a sensitivity of 88% and specificity of up to 96%. Currently, impedance tests for the diagnosis of GER are also performed.¹

Clinical characteristics of patients with IM

Symptoms that may accompany patients with IM are biliary or gastric vomiting, GER, nausea, abdominal distention or chronic intermittent abdominal pain, constipation or diarrhea, occasional bloody bowel movements, anorexia, growth delay and weight gain or failure to thrive. However, there may be patients with malrotation who are asymptomatic although patients with malrotation generally have some symptoms. Studies have demonstrated that there are patients with IM whose only symptom is GER.^{3,5-7,10}

Of the patients with IM, 75% have GER or vomiting with biliary characteristics; however, in the remaining

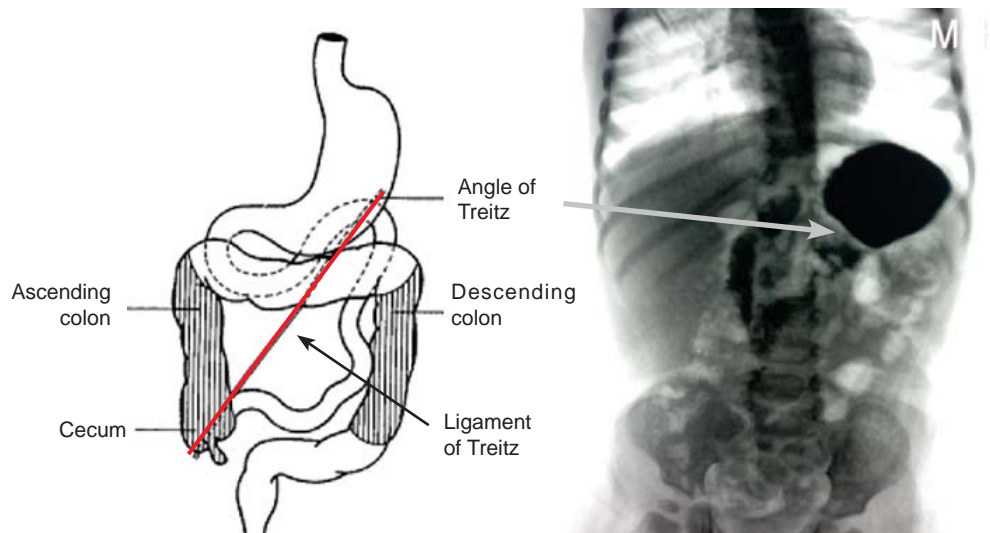


Figure 1.

Location of the angle of Treitz should normally be to the left of the spine at the level of the splenic angle.

25% GER has gastric characteristics or may be food related and malrotation may go unnoticed. Of patients with IM, 75% have symptoms from the first month of life, 90% have symptoms in the first year and 10% may go un-

ticed and reach adult age with the risk of intestinal volvulus, short gut syndrome and death as a result. However, in the majority there is a history of gastrointestinal disorders throughout life.^{5,6}

Therefore, it is considered a serious medical error to not rule out an IM lasting 3 to 6 months prior to antireflux treatment because these patients will not have favorable results. It is even worse when the physician decides to perform a fundoplication when antireflux treatment does not work as it is not the surgical treatment of choice for IM. Although it is true that, with fundoplication, esophageal reflux will be prevented in those patients. But by itself will only correct the anatomic defect of the malrotated mid-intestine, which increases the risk of intestinal volvulus and death in the postoperative future. In a patient with IM, the surgical treatment of choice should be a Ladd procedure.⁴⁻⁹

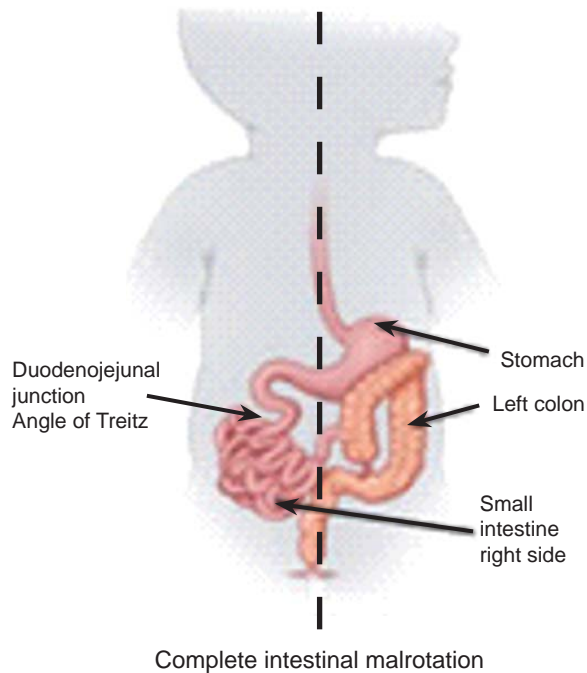


Figure 2. The position of the duodenojejunal junction to the right of the midline and the position of the cecum to the left of the midline suggests complete intestinal malrotation.

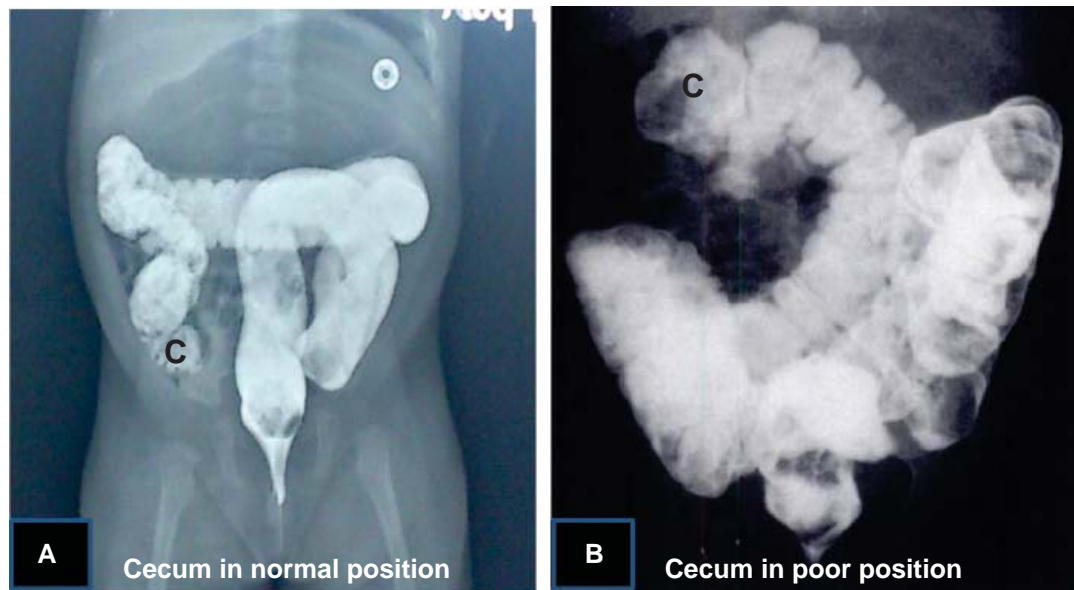
Clinical characteristics of patients with intestinal volvulus in evolution

It is always important to differentiate an IM from intestinal volvulus. Malrotation is in itself the anatomic alteration in intestinal fixation (Figure 2).

An intestinal volvulus is a complication of a patient with IM and will always be a sudden process and an immediate surgical urgency (Figure 4). Intestinal volvulus is characterized by gastric distention with abdominal pain, hypovole-

Figure 3.

Colon enema is not the ideal study for ruling out IM. In a high percentage of malrotated patients, the cecum may be in its normal position and does not rule out an incomplete IM. (A) Cecum (C) in normal position in a malrotated patient. (B) Cecum (C) in the hepatic angle or in the left flank, diagnostic of a complete IM.



mia and data of hypovolemic shock due to incarceration of the mesentery. The key is that the symptomatology occurs suddenly without apparent cause. The first 4 h of initiation of the intestinal volvulus are vital to save the intestine. After this time, the risk of massive intestinal necrosis and death is increased by >90% due to not making a timely diagnosis (Figure 5). The vomitus of biliary content or fecalith always requires surgical treatment and it is urgent to diagnose an IM or an intestinal volvulus in progress.^{4,6,7}

As pediatricians and pediatric surgeons, there is the responsibility of performing a timely diagnosis during infancy as IM in adults is frequently associated with a delay in diagnosis and an increase in morbidity due to mid-intestinal volvulus with catastrophic consequences for the patient.^{4,10-12}

Methods of diagnosing intestinal malrotation

Simple x-ray of the abdomen

A simple x-ray does not exclude the diagnosis of malrotation or intestinal volvulus. On a simple x-ray of the abdomen there is no image suggestive of IM or intestinal volvulus; therefore, it is not suggested as a first-line diagnostic method. However, in a patient with data of acute abdomen without prior history of surgery and with data of sudden shock, an x-ray with data of intestinal occlusion should suggest an intestinal volvulus in progression.⁷

Colon enema

Colon enema is not the ideal study for ruling out an IM. In 20-30% of patients with incomplete malrotation, the

cecum may be in its normal position and IM or Ladd bands in the mid-intestine cannot be ruled out.⁸ However, the finding of a high cecum of the right or left side in the hepatic angle is abnormal and consistent with an IM.⁵ In the presence of a complete IM, the angle of Treitz is found in the right part of the midline of the abdomen, and the cecum tends to be on the left side (Figure 3).

Doppler ultrasound, CAT and MRI

There are radiological studies such as Doppler ultrasound (USG), CAT or MRI, which are of great assistance for diagnosis of IM or intestinal volvulus. However, often due to their lack of availability other studies are not considered as first-line studies. In the USG, ultrasonographic data of intestinal malrotation are the superior mesenteric vein (SMV) to the right of the superior mesenteric artery (SMA) and the inversion of the relationship between the SMA and the SMV. On CAT, torsion of the SMA and SMV pedicles or “swirl sign” is a radiological finding with intravenous contrast media that confirms the diagnosis. On the MRI, data of inversion of the SMA and the SMV or malpositioning of the colon are suggestive of IM. USG, MRI and CAT with intravenous contrast media are useful studies; however, these studies are often operator dependent and an experienced pediatric radiologist is required for adequate interpretation. Also, these studies are not usually available in public hospitals 24 h/day. Any finding suggestive of malrotation on an ultrasound, CAT or MRI

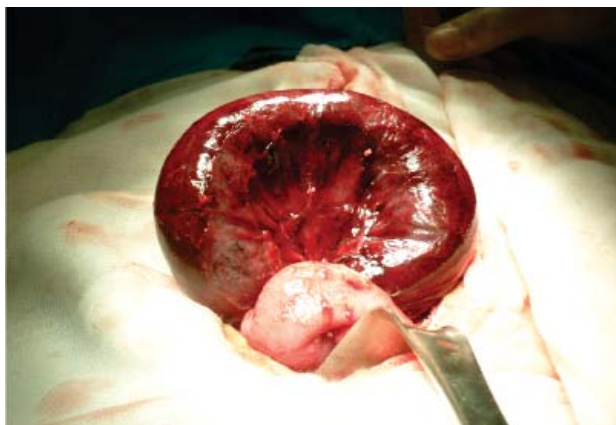

Figure 4. Imaging of a segment of intestinal volvulus in a patient with IM operated with a Nissen fundoplication. Data of intestinal necrosis is seen.

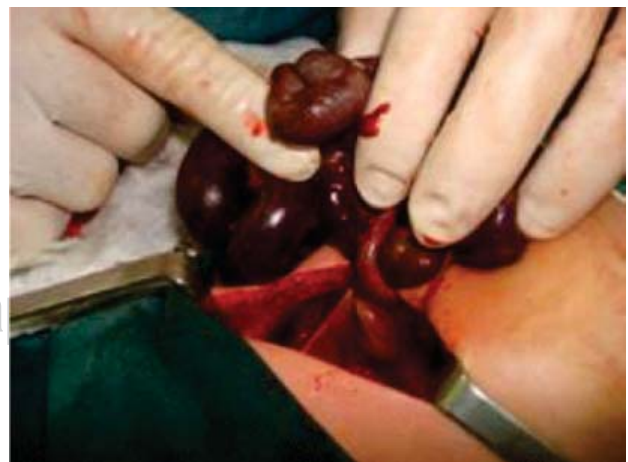

Figure 5. Intestinal volvulus around the vascular pedicle with massive intestinal necrosis.

requires the performance of an upper gastrointestinal transit study to either confirm or rule out IM.^{2,8,13}

Importance of UGI series

UGI series is a radiological method of great importance in patients with suspected GER as it allows evaluation of the upper gastrointestinal tract and diagnosis of any anatomic anomaly that may be causing the GER. This is the main indication for performing UGI series in all patients with symptoms of GER followed by intestinal transit study.⁸

UGI series with barium is not recommended although it is an easy study to perform and great accessibility. Barium is not physiological. It is not absorbed in the intestine and for a short time evaluates the episodes of reflux and may not be detected. There is a false negative or false positive rate of ~50% when compared with 24-h pH monitoring. For this reason the UGI series is not useful for diagnosing GER.¹

In children, UGI series is generally done with hydro-soluble contrast media that offers greater advantages over barium, among which is that it is absorbed in the digestive tract. On the other hand, UGI series with swallow can be requested to rule out any swallowing disorder in cases where there is a psychomotor delay suspected. Also, the study can be continued with an upper intestinal transit study to see the anatomy of the mid-intestine and continue to the colon, which would help with the differential diag-

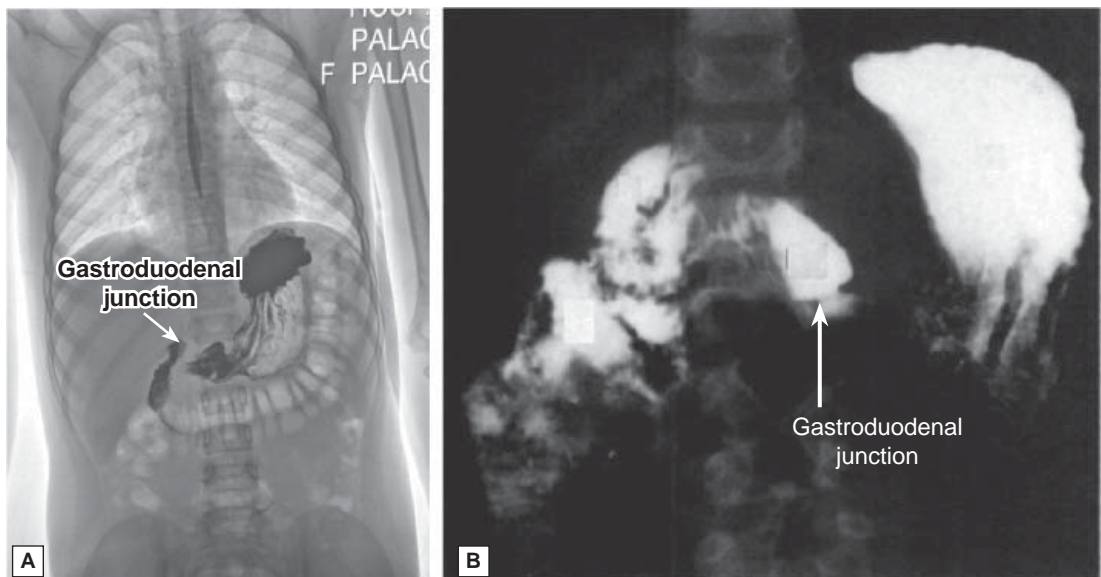
nosis of any anatomic abnormality causing the GER or vomiting in a pediatric patient.

In the emergency service, UGI series with hydro-soluble contrast media is a very useful tool for rapid and timely diagnosis in those patients with suspicion of an intestinal volvulus, avoiding a delay in diagnosis and its complications.^{8,14} There are various radiological data which, together with the patient's clinical information, help to diagnose an IM or an intestinal volvulus.^{2,3,5,8,13,14}

- The gastroduodenal junction is not found in its normal position, to the right of the midline. In cases of malrotation, the gastroduodenal junction is found in a low anterior position, frequently medial or to the left of the midline. The lateral image is very useful for evaluation of the anterior and posterior relationships of the duodenojejunal junction (Figure 6).⁵
- In the UGI series it is important to observe the esophageal anatomy, the stomach and the "C" normal duodenum made up by the first, second, third and fourth portion of the duodenum up to the duodenojejunal junction or angle of Treitz (Figure 7). Normally, the location of the angle of Treitz should be to the left of the spinal column at the level of the splenic angle (Figure 8). Any position outside this site, whether it is at the level of the spine or to the right of the spine, is diagnostic of IM.

Figure 6.

(A) The gastroduodenal junction is not found in its normal position to the right of the dorsal spine (arrow). (B) In cases of malrotation, the gastroduodenal junction is found in a low anterior position frequently medial or to the left of the spine (arrow). The lateral image is very useful for the evaluation of the anterior and posterior relationships of the duodenojejunal junction.



- On observing changes in the duodenum, whether a dilation or stenosis due to external obstruction of Ladd bands, with incomplete duodenal obstruction due to a partial rotation of the duodenum, as well as the absence of the angle of Treitz in the UGI are indirect data of intestinal malrotation (Figure 9). It is important to rule out duodenal atresia or fenestrated duodenal membrane because these types of intestinal malforma-

tions are usually associated with IM due to the absence of the duodenojejunal junction (Figure 10).^{5,8,14}

- The lumen located outside its normal position in the hepatic angle or located to the left side suggests the diagnosis of complete IM (Figure 3).

Intestinal volvulus is the catastrophic complication in a patient with IM. A standing x-ray of the abdomen will

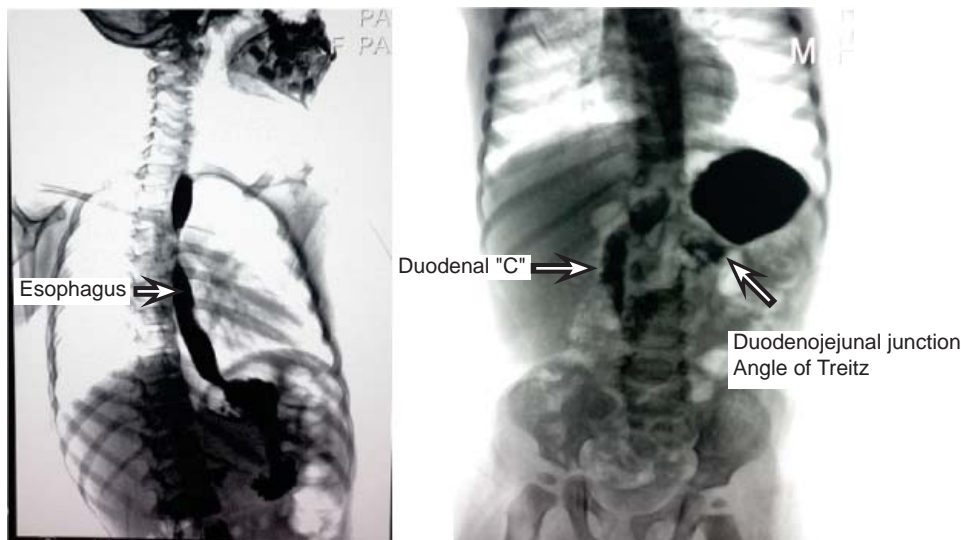


Figure 7.

UGI series is indicated for ruling out anatomic abnormalities. One can see the esophagus, stomach and duodenum. It is very important to observe the duodenal "C" up to the angle of Treitz and its relationship with the spine.

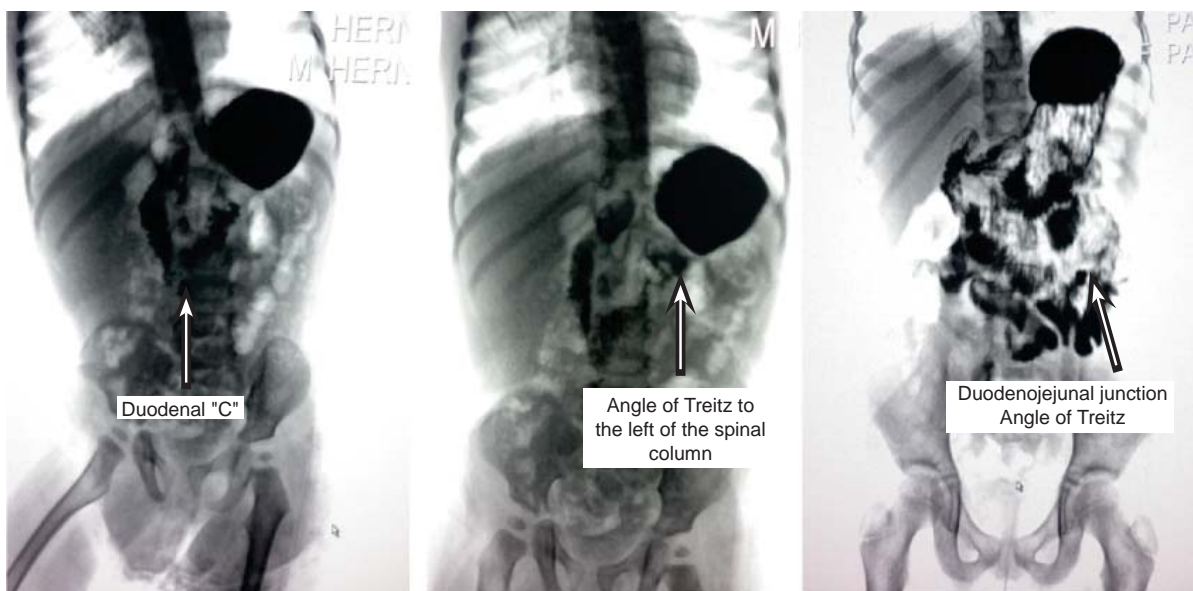


Figure 8. Location of the angle of Treitz should normally be to the left of the spine at the level of the splenic junction. Any position outside this site or to the right of the spine suggests complete duodenal or intestinal malrotation.

only display data of mechanical obstruction; however, there are no pathognomonic images. Therefore, for rapid diagnosis in an emergency service, UGI series can be done through a nasogastric tube passing contrast media, preferably water soluble. According to UGI series, de-

tails suggesting an intestinal volvulus are cut images or those with an air fluid level, image resembling a bird's peak, corkscrew, or image in "Z" accompanied by a clinical picture of acute abdomen and sudden shock (Figure 11).^{5,8}

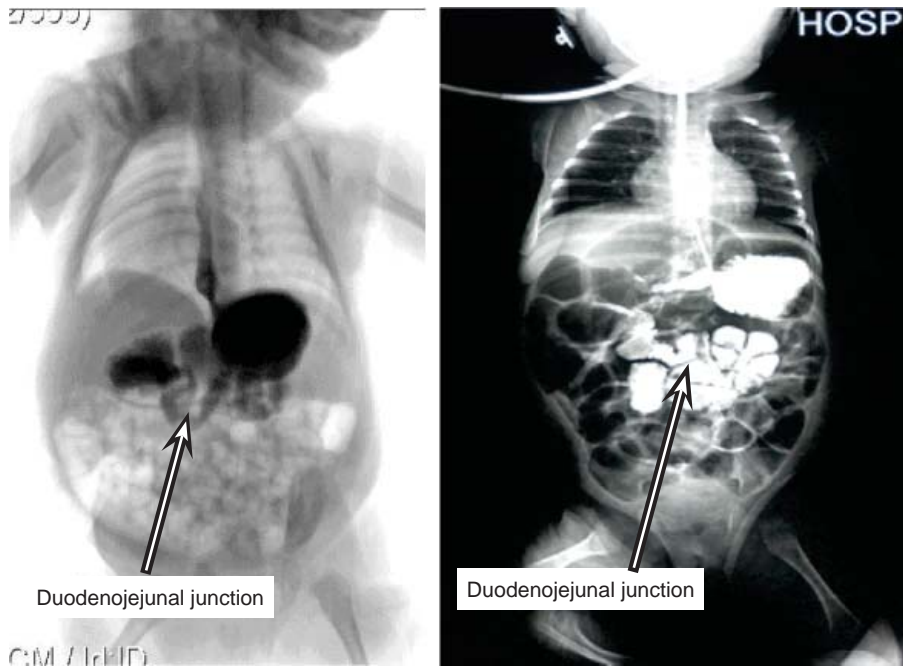


Figure 9.

One can observe the duodenojejunal junction poorly positioned to the right or over the dorsal spine, as well as the alterations in the duodenum (dilation or distal stenosis due to external obstruction by the Ladd bands or a partial rotation of the duodenum) are indicative of IM.

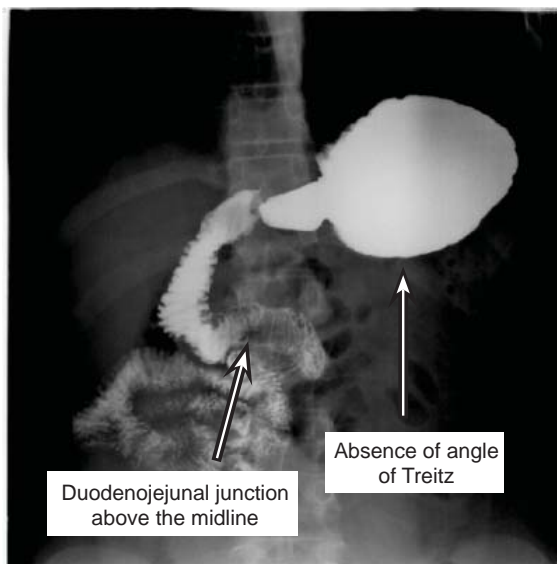


Figure 10. Absence of the angle of Treitz on a UGI series is an indirect finding of IM.

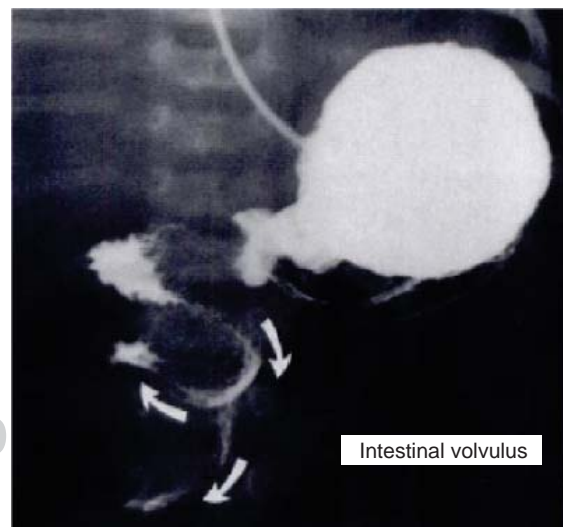


Figure 11. Radiographic findings of volvulus by UGI series are a short image or with an air fluid level, bird's peak image, corkscrew or in "Z" accompanied by clinical picture of acute abdomen and sudden shock.

To identify this data, UGI series should be performed in a dynamic manner with fluoroscopy by a pediatric radiologist. X-rays should be taken in anterior-posterior and lateral position of the duodenum.

Treatment of patients with IM

In patients with secondary IM and GER, the Ladd procedure is the surgical method of choice. It is important to mention that this procedure is recommended for all children with IM, even when the patient is asymptomatic, especially in children <1 year of age due to the high risk of mid-intestinal volvulus in infancy.^{5,6,12}

Recently, laparoscopic techniques for neonates with IM have been described. However, adequate training and the services of a neonatal laparoscopic team for performing such procedures in neonates is required.^{15,16}

IM with propensity to volvulus represents a diagnostic challenge in pediatric patients. It should always be kept in mind that an abnormally rotated intestine is an abnormally fixed intestine and therefore, predisposed to a volvulus. IM is a frequent disorder and early diagnosis is important for a favorable outcome as well as to avoid the short intestine syndrome secondary to mid-intestinal volvulus or death. It is important to carry out UGI series with hydrosoluble contrast media followed by upper intestinal transit in all patients with a clinical picture of GER with the intention of ruling out anatomic alterations such as IM. UGI series with upper intestinal transit continues to be a very useful tool and accessible to any hospital or emergency service.

Correspondence: Dr. Wilver Ernesto Herrera García
E-mail: wwwilver@hotmail.com

REFERENCES

1. Duque-Quintero A, Ramírez-Yusti N, Salazar-Gómez O, Álvarez-López F, Santos-Luna HA, Villegas-Isaza CA. Guías de Práctica Clínica Basadas en la Evidencia. Reflujo Gastroesofágico en Niños. Available at: <http://www.yumpu.com/es/document/view/12894457/reflujo-gastroesofagico-en-ninos-telesalud-universidad-de-caldas>
2. Miller CR. Ultrasound in the assessment of the acute abdomen in children: its advantages and its limitations. *Ultrasound Clin* 2007;2:525-540.
3. McVay MR, Kokoska ER, Jackson RJ, Smith SD. Jack Barney Award. The changing spectrum of intestinal malrotation: diagnosis and management. *Am J Surg* 2007;194:712-719.
4. Malek MM, Burd RS. The optimal management of malrotation diagnosed after infancy: a decision analysis. *Am J Surg* 2006;191:45-51.
5. Clark LA, Oldham KT. Malrotation. In: Ashcraft KW, Holcomb GW, Murphy JP, eds. *Pediatric Surgery*. Philadelphia: WB Saunders; 2000. pp. 449-459.
6. Dassinger MS, Smith SD. Disorders of intestinal rotation and fixation. In: Coran AG, Grosfeld JL, O'Neill JA Jr, Fonkalsrud EW, eds. *Pediatric Surgery*. Philadelphia: Elsevier. 2006; pp.1342-1357.
7. Baeza-Herrera C, Escobar-Izquierdo MA, Martínez-Rivera ML, García-Cabello LM, Nájera-Garduño HM. Malrotación y volvulus intestinal perinatal. *Acta Pediatr Mex* 2008;29:73-77.
8. Berrocal T, Gayá F, de Pablo L. Aspectos embriológicos, clínicos y radiológicos de la malrotación intestinal. *Radiología* 2005;47:237-251.
9. Kumar Y, Sarvananthan R. Gastro-oesophageal reflux in children. *Clin Evid* 2004;11:414-423.
10. Durkin ET, Lund DP, Shaaban AF, Schurr MJ, Weber SM. Age-related differences in diagnosis and morbidity of intestinal malrotation. *J Am Coll Surg* 2008;206:658-663.
11. Etchevers J, Palermo M, Salvatore MG, Tarsitano F, Villafañe V. Malrotación intestinal en adultos: causa infrecuente de abdomen agudo oclusivo. *Rev Argent Radiol* 2008;72:435-438.
12. Palmer OP, Rhee HH, Park WG, Visser BC. Adult intestinal malrotation: when things turn the wrong way. *Dig Dis Sci* 2012;57:284-287.
13. Yousefzadeh DK. Regarding online publication of 'CT appearance of the duodenum and mesenteric vessels in children with normal and abnormal bowel rotation'. *Pediatr Radiol* 2011;41:1481-1482.
14. Long FR, Kramer SS, Markowitz RI, Taylor GE. Radiographic patterns of intestinal malrotation in children. *Radiographics* 1996;16:547-556.
15. Hagendoorn J, Vieira-Travassos D, van der Zee D. Laparoscopic treatment of intestinal malrotation in neonates and infants: retrospective study. *Surg Endosc* 2011;25:217-220.
16. Sucandy I, Bonanni F. Surgical management of intestinal malrotation during laparoscopic roux-en-Y gastric bypass. *Am Surg* 2012;78:E106-E108.