

## Anomalous left coronary artery from the pulmonary artery (ALCAPA) in adult age. A 5-case series successfully repaired with surgery

*Origen anómalo de la coronaria izquierda en la arteria pulmonar (ALCAPA) en la edad adulta.*

*Una serie de 5 casos reparados con éxito con cirugía*

**Key words:**

Congenital heart disease, pulmonary artery abnormalities, ALCAPA, myocardial ischemia, coronary reimplantation.

**Palabras clave:**

Cardiopatías congénitas, anomalías de la arteria pulmonar, ALCAPA, isquemia miocárdica, reimplantación coronaria.

Lucelli Yáñez-Gutiérrez,\* Diana López-Gallegos,\* Carmen Emma Cerrud-Sánchez,\* Horacio Márquez-González,\* Marlenne Berenice García-Pacheco,\* Moisés Jiménez-Santos,\*\* Jaime Alfonso Santiago-Hernández,\*\*\* Homero Alberto Ramírez-Reyes,\*\*\* Carlos Riera-Kinkel\*\*\*\*

### ABSTRACT

**Objective:** To describe conduct, evolution and surgical treatment of ALCAPA in adult patients. **Material and methods:** Series of five cases, > eighteen years old. Clinical data (including surgery and follow-up), and echocardiographic/hemodynamic studies were reviewed. **Results:** The series comprised four women (80%) and a man (20%), with a mean age of 38.2 (range 18-65) years. Myocardial ischemia was found in three patients (60%), detection of a cardiac murmur in one patient (20%) and aborted sudden death in one patient (20%). Physical examination was normal in every case. Two patients (40%) presented grade II cardiomegaly and venocapillary pulmonary hypertension. In three cases, subendocardial ischemia was found on the EKG without necrosis evidence. Echocardiogram was performed in every patient. On the short axis window turbulent (mosaic) retrograde flow on left interventricular septum and left coronary artery absence was documented. Myocardial scintigraphy was performed on four patients finding moderate to severe anterolateral ischemia. CT angiography was performed on 80% of cases. In 40% of patients, left ventricular end diastolic pressure was elevated in cardiac catheterization. Surgical repair was successful in every case. Coronary reimplantation was performed on two patients, Takeuchi procedure was performed on two patients and revascularization with an internal mammary artery-to-anomalous left coronary artery from the pulmonary artery procedure in one patient. After 48 months of follow-up, every patient is alive in functional class I. **Conclusions:** Natural history of ALCAPA includes chronic ischemia, ventricular dysfunction

### RESUMEN

**Objetivo:** Describir el comportamiento, evolución y tratamiento quirúrgico de ALCAPA en pacientes adultos. **Material y métodos:** Serie de cinco casos, mayores de 18 años de edad. Se revisaron los datos clínicos, ecocardiográficos, hemodinámicos, quirúrgicos y del seguimiento. **Resultados:** La serie comprendió cuatro mujeres (80%) y un varón (20%), con edad promedio de 38.2 años (rango 18-65 años). Se encontró isquemia miocárdica en 60% de los casos, detección de soplo en 20% y muerte súbita abortada en el 20%. La exploración física fue normal en todos los casos. Dos pacientes con cardiomegalia grado II e hipertensión venocapilar. En tres casos el ECG mostró isquemia subendocárdica pero sin evidencia de necrosis. El ecocardiograma reveló flujo turbulento retrógrado en septum interventricular y ausencia de la arteria coronaria izquierda en el eje corto. El gammagrama cardíaco fue positivo para isquemia, moderada a severa en región anterolateral. Se realizó angiografía en 80% de los casos. En 40% de los pacientes, la presión diastólica final del ventrículo izquierdo se encontró elevada en el cateterismo cardíaco. La cirugía fue exitosa en todos los casos. La técnica quirúrgica de elección fue el implante de la arteria coronaria en dos pacientes, procedimiento de Takeuchi (túnel intrapulmonar) en dos casos y en un solo caso con revascularización con arteria mamaria interna. Después de 48 meses de seguimiento todos los pacientes están vivos y en clase funcional I. **Conclusiones:** La historia natural de la ALPACA implica isquemia crónica y disfunción ventricular además de arritmias severas que pueden llevar a la muerte. Son pocos los adultos con esta entidad

\* Congenital Heart Disease Department.

\*\* Computed

Tomography

Department.

\*\*\* Interventional

Cardiology/

Catheterization Lab.

\*\*\*\* Cardiothoracic

Surgery Division.

Cardiology Hospital,  
National Medical Center  
«UMAE Siglo XXI»

and severe arrhythmias that could lead to death. There are very few cases in adults and the likelihood of reaching this age depends on collateral circulation provided by the right coronary artery. This was found in each case in this series, documented by echocardiography and cardiac catheterization. Surgical procedures for this entity include coronary reimplantation, Takeuchi procedure and internal mammary artery-to-anomalous left coronary artery from the pulmonary artery procedure (performed in one patient on this series). Prognosis is good, as long as the congenital defect is corrected.

*y depende del grado de circulación colateral a partir de la coronaria derecha, esto se encontró en todos nuestros casos y están documentados en el ecocardiograma y confirmados con el cateterismo cardiaco. Las opciones terapéuticas quirúrgicas incluyen el reimplante de la arteria coronaria o bien la revascularización miocárdica con puentes de arteria mamaria. Como ocurrió en una sola de nuestras pacientes que fue la de mayor edad. El pronóstico es bueno, siempre y cuando se corrija la lesión congénita.*

## INTRODUCTION

Anomalous left coronary artery from the pulmonary artery (ALCAPA) is an infrequent congenital defect, representing 0.25 to 0.5% of congenital heart defects,<sup>1</sup> and affecting one in 300,000 live births. In pediatric population, it can cause cardiac dilatation or myocardial ischemia, whereas in neonatal population, it can be highly lethal, with mortality rates over 90% when it is complicated with myocardial infarction. In this scenario, only 10 to 15% of patients will reach adult age, depending largely on intercoronary collateral circulation. Furthermore, the disorder, besides of causing ischemia, can produce myocardial fibrosis, left ventricular remodeling and chamber dilatation, mitral valve insufficiency and congestive heart failure.<sup>2</sup>

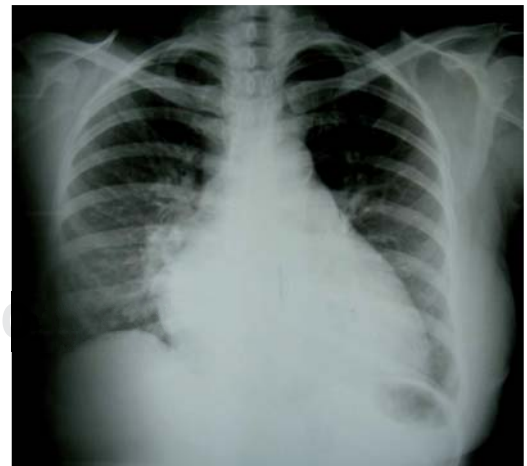
The clinical spectrum of this defect in adults presents from an asymptomatic course to a severe clinical presentation with malignant ventricular arrhythmias and myocardial ischemia. Thus, it is necessary to perform opportune surgical procedure with any of the techniques that establishes a two coronary arteries system: coronary reimplantation, creation of an intrapulmonary aortocoronary tunnel (Takeuchi procedure) or revascularization (either venous or arterial), along with a mitral valve repair if needed.<sup>3</sup>

## CASE DESCRIPTION

All cases of patients over the age of 18, diagnosed with ALCAPA in our center, in a 5-year period were included. Patients who did not accept surgical treatment or failed to complete a follow-up were excluded.

Five patients meeting the criteria were included, four women (80%), and one man, with a mean age of 38.2 (range 18-65) years. In the series, one patient was asymptomatic (20%), three more have had retrosternal pain (60%) and other had aborted sudden cardiac death with sustained ventricular tachycardia (20%).

Physical examination was irrelevant in every case, but there was a systolic murmur in three cases (60%). X-ray chest film showed cardiomegaly grade II and venocapillary hypertension in two patients (*Figure 1*), being normal on the remaining three patients (*Figure 2*). In two cases (40%) resting EKG showed subendocardial ischemia, in one case signs of anteroseptal necrosis was found (*Figure 3*), while in the remaining two cases any electrocardiographic abnormality was detected (*Figure 4*).



**Figure 1.** Chest roentgenogram, case 2, 65-year old woman, cardiomegaly grade II and venocapillary hypertension.

An early positive stress test was found on two patients, with subendocardial extensive anterior ischemia, that disappeared at rest (Figure 5).

Echocardiogram was the key study to establish ALCAPA diagnosis in every patient. In three cases (60%) we found left ventricular dilatation with anteroseptal and anterior motility alterations. None of the patients suffered from mitral insufficiency. With color Doppler, turbulent (mosaic) retrograde flow was found on apical and four-chamber windows on every patient, ascending from apical portion to basal portion of the left ventricle. When continuous Doppler was used, low gradients and velocities were found (Figure 6). On the short axis window we documented turbulent (mosaic) retrograde flow on left interventricular septum and left coronary artery absence (Figure 7).

Myocardial scintigraphy was performed on four patients, finding moderate to severe

anterolateral ischemia (Figure 8). CT angiography was performed on four patients, finding absence of left coronary artery, the origin of the left coronary artery from the pulmonary artery and contralateral coronary circulation (Figure 9).

All patients underwent bilateral selective coronariography and left heart catheterization, finding elevated left ventricular end diastolic pressure in two patients. Angiography demonstrated left coronary absence, right coronary circulation and opacification of both the left coronary system and pulmonary artery (Figure 10). In one case, it was possible to selectively cannulate the left coronary artery through the pulmonary artery

The surgical technique was chosen based on anatomical findings. On three patients, coronary reimplantation was performed. Takeuchi procedure was performed in one patient and in other an internal mammary artery-to-anomalous left coronary artery from the pulmonary artery procedure was performed.

All patients are alive and are asymptomatic after 48-months of follow-up, in functional class I and without evidence of residual ischemia.

The patient who underwent Takeuchi procedure developed mild right ventricle outlet obstruction gradient. At this time, however, surgical procedure is not indicated

## REVIEW

Despite its rarity, this anomaly has been extensively studied, since Brook's first description in 1886.<sup>4</sup> In 1908, Abbot described the anomaly in detail, but it was until 1933 when Bland, White and Garland coined the current name: ALCAPA, the English acronym of Anomalous Left Coronary Artery from Pulmonary Artery.<sup>1</sup>

The incidence is low, affecting only 1 in 300,000 live births. Although it represents less than 0.5% of all congenital heart disease, it is the most common congenital defect of the coronary arteries.<sup>1,2</sup>

Even though ALCAPA usually occurs as an isolated defect, it is sometimes associated to other congenital heart disease (transposition of great vessels, pulmonary atresia with intact ventricular septum, tetralogy of Fallot, double right ventricle outlet and common arterial trunk).<sup>4</sup>

Figure 2.

Chest roentgenogram, case 1. 18-year old man with no cardiomegaly.

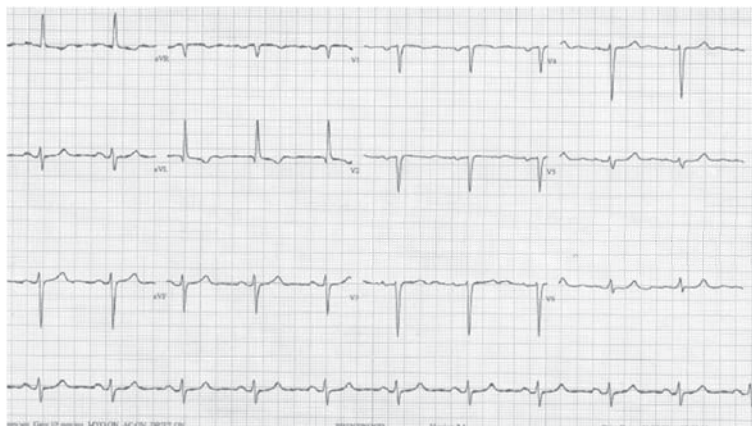
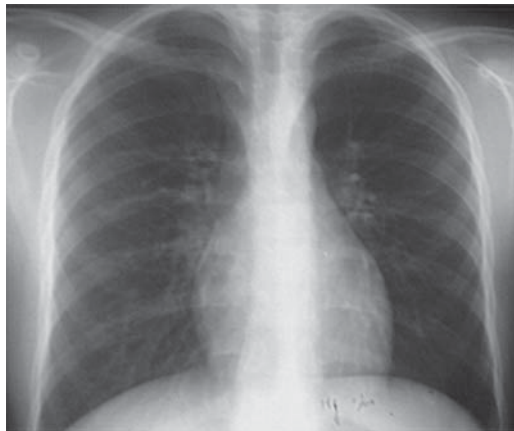
Figure 3. EKG, case 2. Anteroseptal necrosis and systolic overload data.

There are three embryologic theories trying to explain this anomaly: the first one proposes an abnormal disposition of the aortic-pulmonary septum, the second one set forth the persistence of the left coronary primordia (anlage) on the pulmonary artery which permits the anomalous development of the artery in the wrong artery, and the last one that put forward a conotruncus separation defect.<sup>1</sup>

Four anatomic/hemodynamic phases are described:

1. Elevated pulmonary artery pressure with blood flow from the pulmonary artery to the left coronary artery without any sign of ischemia.
2. A decrease in both pulmonary artery pressure and pulmonary artery resistance, with flow from the right to the left coronary artery through collateral circulation. Therefore, hypoperfusion, myocardial ischemia and its clinical consequences like angina or infarction, when there is insufficient flow through collateral circulation.

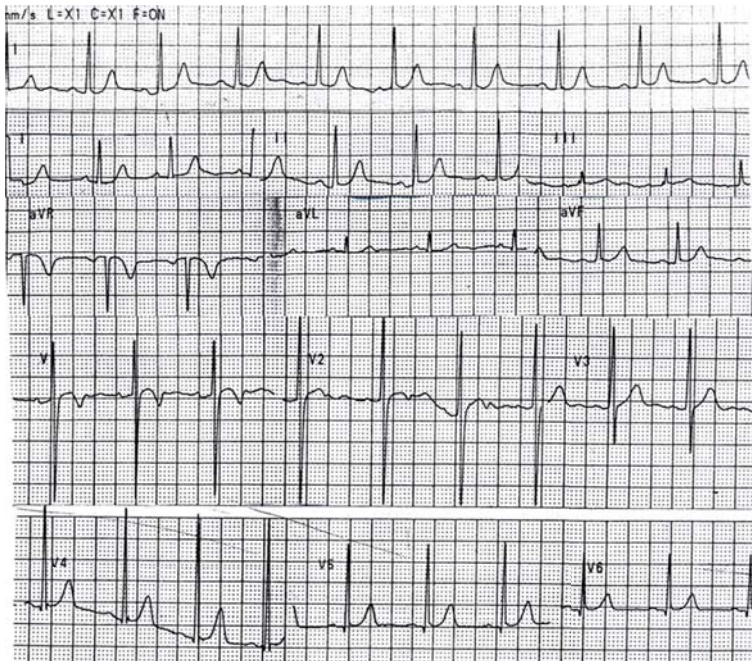


Figure 4. EKG, case 1. Normal.

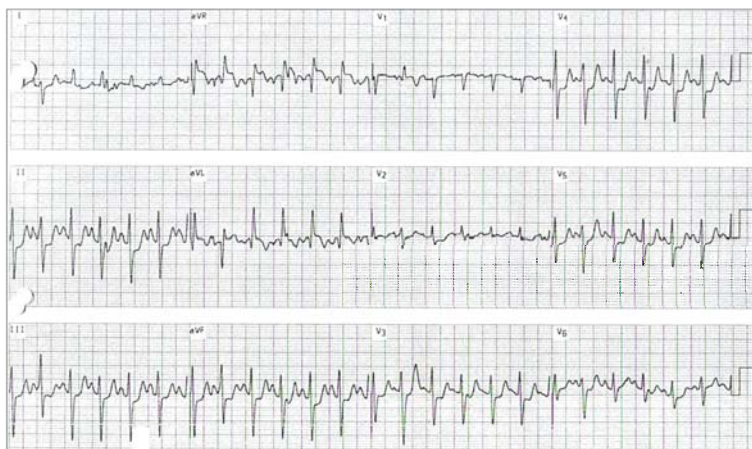

Figure 5. Stress test, case 1. Descent in ST segment in anterior and inferior locations.

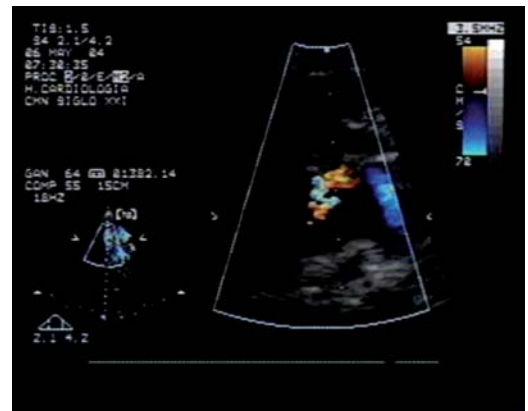


Figure 6. Echocardiography, short axis at the great vessels, where absence of left coronary is seen.

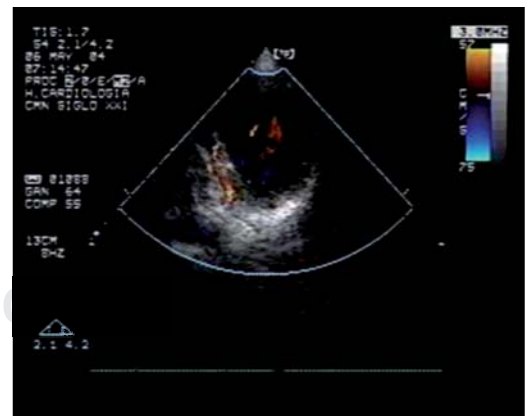


Figure 7. Echocardiogram, short axis at the left ventricle. Mosaic color corresponds to coronary contralateral circulation.

3. A decrease in both the pulmonary artery pressure and pulmonary artery resistance, but with multiple intercoronary connections and an adequate left coronary artery filling pressure, with no evidence of ischemia.
4. Normal pulmonary artery pressure and pulmonary artery resistance, with left coronary

artery flow depending on right coronary artery flow and its collaterals, which steal oxygenated blood from the right coronary artery and the pulmonary trunk causing left-to-right shunt. In this phase, myocardial ischemia may be subclinical.<sup>5</sup>

Unfortunately, a minority of patients will reach phases 2 or 3 because 85% of them die within the first year of age. The remaining 15% will reach phases 3 or 4 with a life expectancy of 30 to 40 years, dying of heart failure or arrhythmia (sudden death).<sup>3,4</sup>

The spectrum of the disease depends on collateral circulation and the development of ischemia, conditioning the clinical expression of the disease in two groups of ages: pediatric and adult ALCAPA.

The first group (pediatric ALCAPA) comprises newborns and infants that may have tachypnea, uncontrollable crying spells because of angina, failure to gain weight, irritability, heart failure, mitral insufficiency, cardiac arrhythmias, myocardial infarction and sudden death. Physical examination could reveal a holosystolic murmur due to mitral regurgitation. Approximately 15% of these patients are asymptomatic with a continuous murmur.

The second group (adult ALCAPA) may show no symptoms. This fact largely depends on the magnitude of collateral circulation from the right coronary artery. Some patients will suffer from silent or symptomatic ischemia, mitral insufficiency (dilatation of the mitral valve ring)

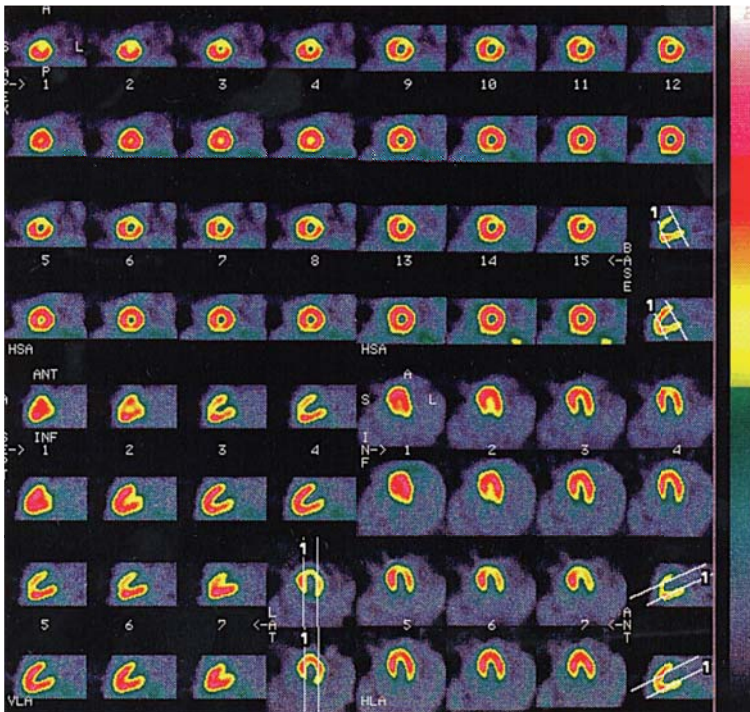


Figure 8. Cardiac scintigraphy, case 3. Severe ischemia induced by stress is shown at the anteroapical region.

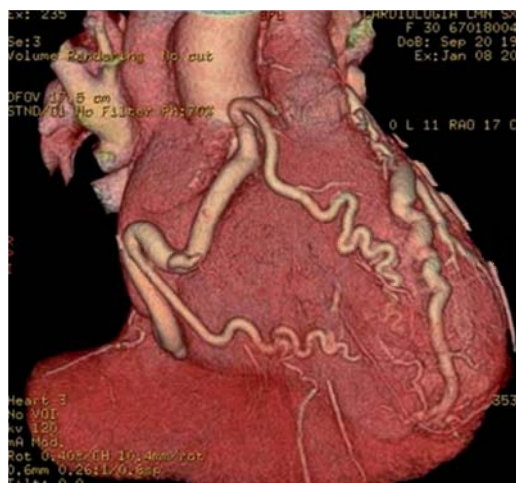


Figure 9. CT angiography, case 4.

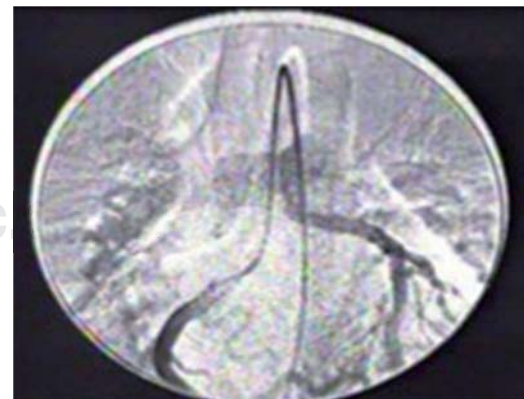


Figure 10. CT angiography, case 5.

and sudden death which may be the first symptom of the disease (one patient in our series).<sup>3-5</sup>

EKG will show necrosis with deep Q waves on DI and aVL, left axial deviation and left ventricular hypertrophy.<sup>2,4,6</sup>

X-ray chest film may show cardiomegaly and left atrial/ventricular enlargement.

Echocardiography is a very important diagnostic tool, disclosing left ventricular function, and furthermore permitting ischemia evaluation (motility disorders and mitral insufficiency secondary to mitral valve ring dilatation). The coronary artery origin is evaluated on the short-axis window allowing to evince the absence of the left coronary artery. With Doppler color, a retrograde flow mosaic, ascending from the apex through interventricular septum (describing anterior descending coronary artery route filled by collateral circulation coming from the right coronary artery) could be shown.<sup>7</sup>

The previously discussed findings can be confirmed with CT angiography, allowing the location of the artery origin as well as the measure of distances among different structures, helping the surgeon to plan a specific type of repair.

Coronary angiography with aortography is the diagnostic gold standard in ALCAPA because both contrast studies unveil doubtlessly the left coronary artery absence, permitting selective both right coronary artery cannulation to evince collateral circulation and coronary anterior descending artery from the pulmonary artery.<sup>3,8</sup>

There is no doubt that surgery is the best treatment option for patients with ALCAPA and it can be an emergency intervention in a symptomatic infant. Several techniques have been described establishing a system of two coronary arteries: coronary artery ligation, revascularization, direct anastomosis (using internal mammary artery, saphenous or subclavian vein and prosthetic materials), coronary artery reimplantation or Takeuchi procedure. All of them with mortality rate below 15%. In our center, all our patients are alive after four years of successful surgical correction.<sup>9,10</sup>

Adverse prognostic factors include: age at onset, ventricular dysfunction and poor col-

lateral circulation. Mitral annuloplasty must be considered in the presence of severe mitral insufficiency. Other treatment options may include left coronary artery occlusion.

As mentioned above, mortality in referral centers is as low as 15%; in our hospital every patient treated is alive after four years of successful surgical treatment.<sup>9,10</sup>

#### REFERENCES

1. Murala JSK, Sankar MN, Agarwal R et al. Anomalous origin of left coronary artery from pulmonary artery in adults. *Asian Cardiovasc Thorac Ann.* 2006; 14 (1): 38-42.
2. Guo HW, Xu JP, Song YH et al. Repair of anomalous origin of left coronary artery from the pulmonary artery. *Asian Cardiovasc Thorac Ann.* 2007; 15 (3): 240-242.
3. Mohanty SR, Murthy KS, Varghese R et al. Evolution of surgical strategies for anomalous left coronary artery. *Asian Cardiovasc Thorac Ann.* 2001; 9: 269-274.
4. Brooks H. Two cases of an abnormal coronary of the heart, arising from the pulmonary artery: with some remarks upon effect of this anomaly in producing cricoid dilatation of the vessels. *J Anat Physiol.* 1885; 20: 26-29.
5. Frescura C, Basso C, Thiene G et al. Anomalous origin of coronary arteries and risk of sudden death: A study based on an autopsy population of congenital heart disease. *Hum Pathol.* 1998; 29: 689-695.
6. Cabello R, Álvarez A, Cáceres J, Moruno A, Santos J, García-Perla JL y cols. Origen anómalo de la arteria coronaria izquierda en la arteria pulmonar. *Rev Esp Cardiol.* 1992; 45: 665-668.
7. Domínguez W, Maitre Azcárate M, Cazzaniga Bul-lon M y cols. Origen anómalo de la arteria coronaria izquierda del tronco pulmonar: diagnóstico mediante ecocardiografía en un lactante asintomático. *An Esp Pediatr.* 1993; 38: 261-263.
8. Walsh M, Duff O, Redmond M. ALCAPA the 20 years Prince Charles Hospital experience. *HEART, Lung and Circulation.* 2007; 16: 111-115.
9. Angellini P. Anomalous origin of the left coronary artery from the pulmonary artery. the location of the ectopic ostium and the course of the proximal left coronary artery make a difference. *Tex Heart Inst J.* 2008; 35 (1): 36-37.
10. Manoly I, Karangelis D, Viola N et al. Repair o Bland-White-Garland Syndrome via a modified technique. *Tex Heart Inst J.* 2014; 41 (1): 48-50.

#### Correspondence to:

**Lucelli Yáñez Gutiérrez, MD**

Cuahtémoc Núm 330,

Col. Doctores, 06720

Mexico, City.

Phone number: +52 (55) 56-27-69-00 ext. 22203

E-mail: lucelli.yanez@imss.gob.mx