

## Percutaneous coronary intervention with bioabsorbable vascular scaffolds in anomalous origin of right coronary artery: case report

*Intervención coronaria percutánea con stents bioabsorbibles en origen anómalo de la arteria coronaria derecha: reporte de caso*

Héctor Hugo Escutia-Cuevas,\* Ernesto Fernández-Ceseña,\*\*  
Marco Antonio Alcántara-Meléndez,\*\* Andrés Figueroa-Cabrera,\*  
Roberto López-Rosas,\*\* Lizzeth Campuzano-Pineda\*

### Key words:

Bioabsorbable scaffolds, absorb, anomalous origin, right coronary.

### Palabras clave:

Stents bioabsorbibles, absorber, origen anómalo, coronaria derecha.

### ABSTRACT

**Introduction:** A case report describing the use of bio-absorbable vascular scaffolds in a patient with rare anomalous origin of right coronary artery. **Case report:** Male 71 years, ST-segment elevation myocardial infarction in the inferior region wall, thrombolysis with tenecteplase, with reperfusion criteria. Coronary angiography: left coronary system without angiographic lesions, right coronary artery with a significant lesion in the middle segment. An elective percutaneous coronary intervention was performed using 2 bio-absorbable vascular scaffolds (Absorb 3.5 x 28 mm joined in proximal segment with an Absorb 3.5 x 23 mm), posterior review with optical coherence tomography. **Results:** Discharged 24 hours later, remaining asymptomatic at 6 months follow-up. **Conclusion:** In this case, the significant stenosis of the artery involved was treated with the implantation of two bio-absorbable vascular scaffolds, obtaining an appropriate outcome after six months follow-up. This is the first report of a patient with anomalous origin of the right coronary artery treated with bio-absorbable vascular scaffolds in Mexico.

### RESUMEN

**Introducción:** Se trata de un caso clínico que describe el uso de stents bioabsorbibles en un paciente con origen anómalo de arteria coronaria derecha de rara presentación. **Caso clínico:** Hombre de 71 años, con antecedente de infarto del miocardio con elevación del segmento ST en la cara inferior, sometido a trombolisis con tenecteplase, presentando criterios de perfusión. El angiograma coronario reporta el sistema coronario izquierdo sin lesiones significativas, así como la arteria coronaria derecha con una lesión significativa en el segmento proximal a medio. Se realizó una intervención coronaria percutánea electiva con dos stents bioabsorbibles (Absorb 3.5 x 28 mm el cual se empalmó en el segmento proximal con un Absorb 3.5 x 23 mm), revisión posterior con tomografía de coherencia óptica con adecuada aposición. **Resultados:** Egresado 24 horas más tarde, permaneciendo asintomático a los seis meses de seguimiento. **Conclusión:** En este caso, la estenosis significativa de la arteria involucrada fue tratada con la implantación de dos stents bioabsorbibles, con la obtención de un resultado clínico apropiado después de seis meses de seguimiento. Éste es el primer informe de un paciente con un origen anómalo de la arteria coronaria derecha tratado con stents bioabsorbibles en México.

\* División de  
Cardiología.  
\*\* Hemodinamia  
y Cardiología  
Intervencionista.

Centro Médico Nacional  
20 de Noviembre,  
ISSSTE.

Received:  
05/09/2016  
Accepted:  
16/11/2016

### INTRODUCTION

Anomalies of the coronary arteries affect about 1% of the general population, however its prevalence may range from 0.3 to 5.6% in reports of patients undergoing coronary angiography, can be detected in 1%

of the routine necropsies.<sup>1</sup> Anomalous origin of the right coronary artery from the left sinus of Valsalva or interarterial is a rare congenital abnormality with a prevalence of 0.025 to 0.25%.<sup>2</sup> We present here the first case report of a patient with anomalous origin of the right coronary artery underwent elective percutaneous

ous coronary intervention with bio-absorbable vascular scaffolds (BVS).

### CASE REPORT

Male, 71 years of age, history of smoking, diabetes mellitus type 2 and hypertension, both of long evolution.

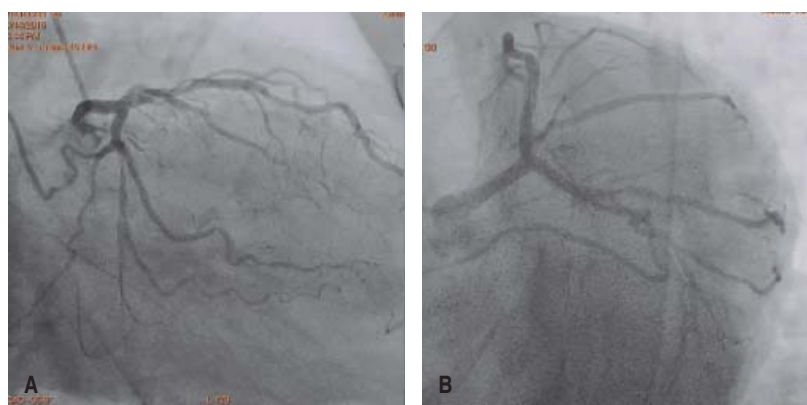
He began with typical angina at rest, being evaluated with 3 hours of symptoms onset, the diagnosis ST-segment elevation myocardial infarction in inferior wall was integrated, being a candidate for thrombolysis with tenecteplase, presenting reperfusion criteria. He was sent to our institution, being received out-time for pharmacoinvasive strategy, with hemodynamic stability.

At 72 hours maintains hemodynamic stability and stratification is performed with perfusory scintigraphy (technetium 99m-sestamibi) reporting inferior severe ischemia. At 96 hours of symptoms onset a transradial coronary angiography was performed, registering the left coronary system without angiographic lesions and normal

distal flow (*Figure 1*), dominant right coronary artery with anomalous origin in the left side region of the ascending aorta, inter-arterial, between aorta and pulmonary artery, circumferentially traveling through the posterior wall of the ascending aorta, with an angiographic significant lesion in the middle segment and a maximum narrowness site of 70% (*Figure 2*), requiring an elective percutaneous coronary intervention (PCI), advancing universal guide to the posterior descending artery with subsequent evaluation of the lesion with optical coherence tomography (OCT) (*Figure 3*). After determining the characteristics balloon pre-dilatation was made with a 3 x 20 mm balloon in the mid-proximal segment. A BVS Absorb 3.5 x 28 mm was sailed in the middle segment and joined in proximal segment with BVS Absorb 3.5 x 23 mm, post-dilatating with 3.5 x 15 mm non-compliant balloon (*Figure 4*), posterior review with OCT showing an adequate expansion of the scaffolds, without complications or events (*Figure 5*). Discharged 24 hours after the procedure,

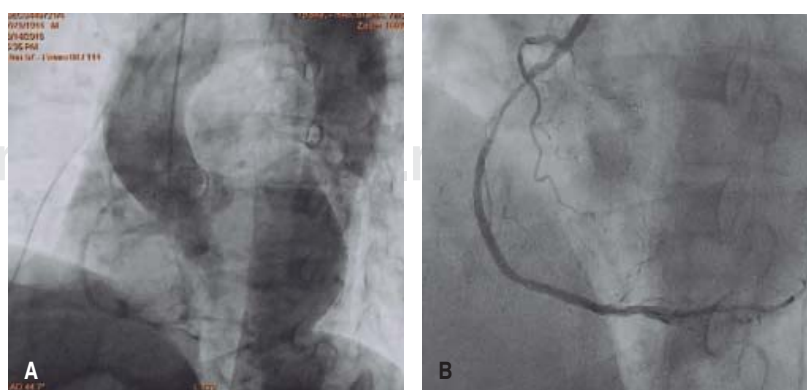
**Figure 1.**

Diagnostic coronary angiography of the left system with no significant angiographic lesions with normal distal flow.



**Figure 2.**

Angiography of aorta in left anterior oblique projection. The anomalous origin of the right coronary artery in the anterolateral region of the ascending aorta (A). Coronary angiography of the right system showing a significant stenosis in the proximal and middle segment of the right coronary artery (B).



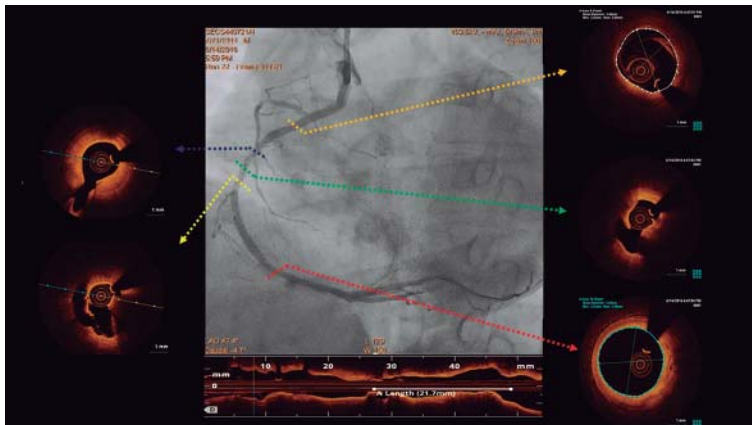it was performed a coronary tomography for further evaluation of placed BVS showing permeability of the right coronary artery (Figure 6). Maintaining asymptomatic after six months of follow-up.

## DISCUSSION

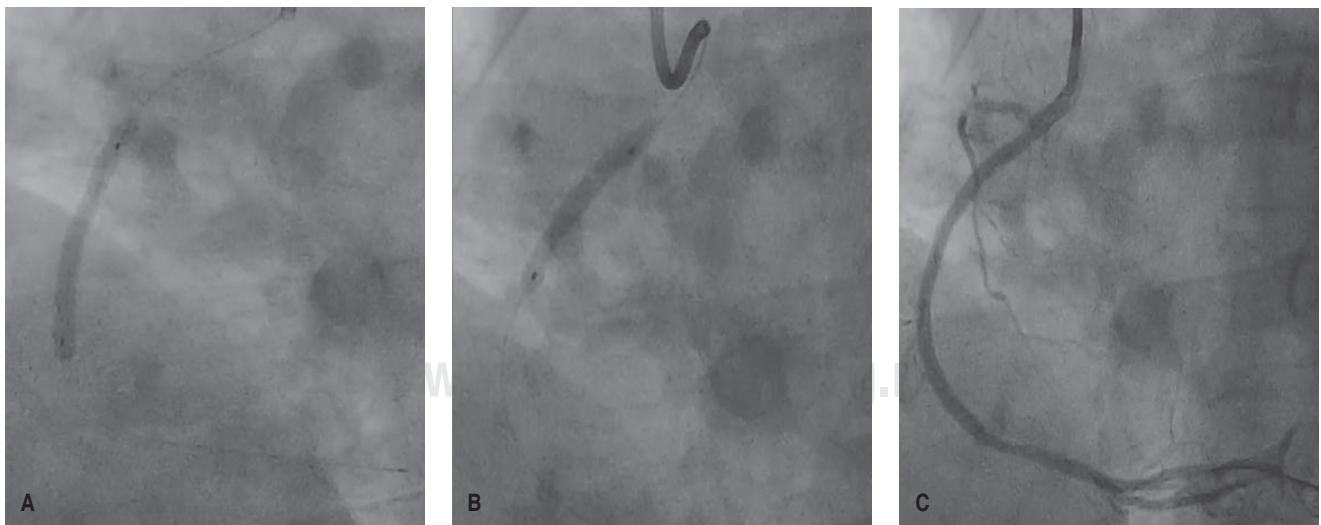
The BVS born after two decades of continuous learning in stent technology. Since its as-

sociation with anticoagulation schemes to the current dual antiplatelet regime, supported by intravascular imaging studies, there have been progressively acceptable results.<sup>3</sup> Until the advent of drug-eluting stents (DES), which in the long term showed other behavior, specifically with vascular remodeling and other problems previously non-conceived as the difficulty or inability to perform coronary bypass (CABG) in extensive coronary territories treated via endovascular.<sup>4</sup> Because of all the past experience the bio-absorbable technology emerged. These stents restore the coronary vasomotion at 12 months, facilitate the vessel remodeling, restore cyclic pulsatility in the implantation site and recover the lumen with plaque regression between 2-5 years after implantation.<sup>5</sup> The first ABSORB study opened possibility for increasing use, provided that the optimum conditions for its implementation were present.<sup>6</sup>

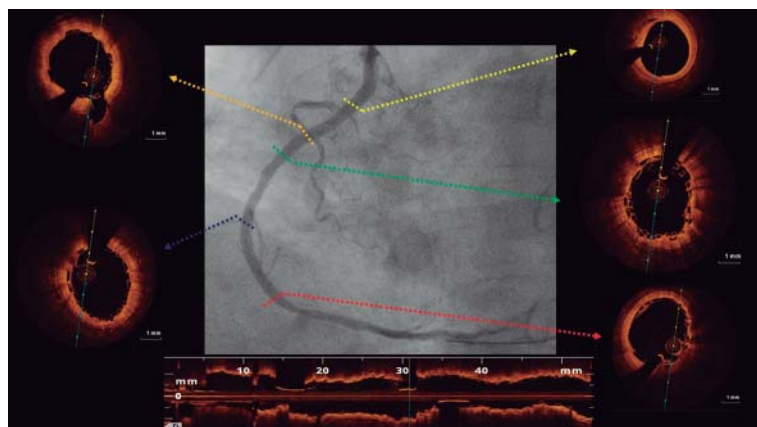
The ABSORB III trial<sup>7</sup> which compared BVS with DES (Everolimus), reported no-inferiority between BVS and DES after 1 year of implantation in rates of angina, complete revascularization and revascularization of culprit vessel but no statistically significant changes in mortality and incidence of myocardial infarction. These results have been reported similarly in other trials.<sup>8</sup> Subacute thrombosis was more prevalent in BVS in the European register GHOST-EU,<sup>9</sup>



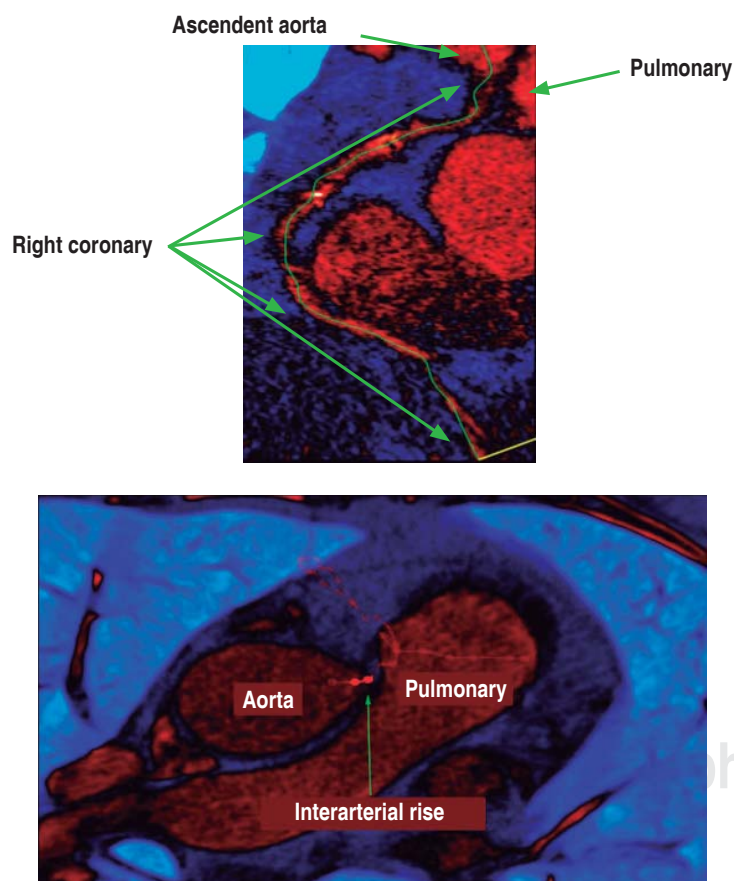
**Figure 3.** Comparative diagram by segments between right coronary angiography and intracoronary OCT. A segment of the artery with significant angiographic lesion that correlates with a lipid plaque with diffuse and undefined edges with disruption and a total length of 21.7 mm.



**Figure 4.** Coronary angiography in left anterior oblique projection at the time of delivery in the right coronary with an Absorb BVS 3.5 x 28 mm (A), then an Absorb BVS 3.5 x 23 mm (B) and control angiography (C).



**Figure 5.** Comparative diagram by segments between right coronary angiography and intracoronary OCT obtained after delivery and post-dilation of both BVS, where appropriate apposition and increase of the luminal diameter intracoronary is observed.



**Figure 6.** Multiplanar reformatted multidetector CT of coronary arteries. Showing the origin of the right coronary artery in the anterolateral region of the ascending aorta following the posterior wall of the aorta with inter-arterial rise.

although not consistently observed in other studies.<sup>10</sup>

The use of BVS has been recently approved in coronary lesions with a length equal to or less than 24 mm, with a minimum diameter of reference vessel greater than 2.5 mm and not more than 3.75 mm. The experience with BVS in arteries with an anomalous origin is very limited,<sup>11</sup> and in Mexico non previously existent until this case.

### Acknowledgements

To the clinical services of Cardiology and Interventional Cardiology of the National Medical Center «20 de Noviembre» for their support, as well as the facilities provided by the institution to carry out this work.

### Conflict of interest statement

None declared.

### Ethical approval

No ethical approval is required. All identifiable patient information has been removed from this manuscript.

### Consent

Written informed consent was obtained from the patient for publication of this case report and any accompanying images. A copy of the written consent is available for review by the editor of this journal.

### REFERENCES

1. Villa A, Sammut E, Nair A, Rajani R, Bonamini R, Chiribiri A. Coronary artery anomalies overview: the normal and the abnormal. *World J Radiol.* 2016; 8 (6): 537-555.
2. Narayanan SR, Al Shamkhani W, Rajappan AK. Anomalous origin of RCA from left coronary sinus presenting as PSVT and recurrent acute coronary syndromes. *Indian Heart J.* 2016; 68: 208-210.
3. Angelini P. Coronary artery anomalies: an entity in search of an identity. *Circulation.* 2007; 115 (10): 1296-1305.
4. Ormiston J, Serruys P. Contemporary reviews in interventional cardiology: bioabsorbable coronary stents. *Circ Cardiovasc Interv.* 2009; 2: 255-260.
5. Lane J, Perkins L, Sheehy A. Lumen gain and restoration of pulsatility after implantation of a bioresorbable

- vascular scaffold in porcine coronary arteries. *JACC Cardiovasc Interv.* 2014; 7: 688-695.
6. Diletti R, Serruys P, Farooq V. ABSORB II randomized controlled trial: a clinical evaluation to compare the safety, efficacy, and performance of the Absorb everolimus-eluting bioresorbable vascular scaffold system against the XIENCE everolimus-eluting coronary stent system in the treatment of subjects with ischemic heart disease caused by de novo native coronary artery lesions: rationale and study design. *Am Heart J.* 2012; 164 (5): 654-663.
  7. Ellis S, Kereiakes D, Metzger C. Everolimus-eluting bioresorbable scaffolds for coronary artery disease. *N Engl J Med.* 2015; 373: 1905-1915.
  8. Puricel S, Arroyo D, Corpataux N. Comparison of everolimus and biolimus-eluting coronary stents with everolimus-eluting bioresorbable vascular scaffolds. *J Am Coll Cardiol.* 2015; 65: 791-801.
  9. Capodanno D, Gori T, Nef H. Percutaneous coronary intervention with everolimus-eluting bioresorbable vascular scaffolds in routine clinical practice: early and midterm outcomes from the European multicentre GHOST-EU registry. *EuroIntervention.* 2015; 10: 1144-1153.
  10. Serruys P, Chevalier B, Dudek D. A bioresorbable everolimus-eluting scaffold versus a metallic everolimus-eluting stent for ischaemic heart disease caused by de-novo native coronary artery lesions (ABSORB II): an interim 1-year analysis of clinical and procedural secondary outcomes from a randomised controlled trial. *Lancet.* 2015; 385: 43-54.
  11. Yew K. Guidezilla guide extension catheter enhances the delivery of bioresorbable vascular scaffold in an anomalous coronary artery. *Int J Cardiol.* 2016; 223: 239-241.

**Correspondence to:**

**Dr. Héctor Hugo Escutia Cuevas**

División de Cardiología. Centro Médico Nacional 20 de Noviembre. ISSSTE. Avenida Félix Cuevas Núm. 540, Col. Del Valle Sur; Delegación Benito Juárez, Ciudad de México. Celular: 55 39386401  
E-mail: perseoyarista@hotmail.com