

## Allergic myocardial ischemia secondary to ibuprofen, Kounis syndrome. Case report

*Isquemia miocárdica alérgica secundaria a ibuprofeno, síndrome de Kounis. Reporte de un caso*

Paúl Santiago Martínez-Torres,\* Armel Hernández-Reyes,\*\*  
Gabriela del Carmen Lozada-Martínez,\*\*\* Yelinnay García-Pérez de Villa Amil,\*\*\*\*  
María Gabriela Villavicencio-Vélez\*\*\*\*\*

### Key words:

Kounis syndrome, myocardial ischemia, drug hypersensitivity, ibuprofen.

### Palabras clave:

Síndrome de Kounis, isquemia miocárdica, hipersensibilidad a las drogas, ibuprofeno.

### ABSTRACT

**Background:** Kounis syndrome was described in 1991 as the simultaneous occurrence of acute coronary events and anaphylactic allergic reactions. Reports of clinical cases and series of small cases of angina triggered by allergic reactions have been reported for many years. It encompasses concepts such as allergic angina and allergic infarction. **Case report:** We report a case of a 47-year-old man with a history of fixed drug eruption for 10 years. The patient attended to the hospital with a moderate-intensity chest pain, electrocardiogram was performed which was compatible with acute coronary syndrome without ST-segment elevation; it progressed favorably with treatment by protocol. The subsequent study showed hypersensitivity to non-steroidal anti-inflammatory drugs and cardiovascular tests was negative, and it was concluded as a case of allergic angina. **Conclusions:** Kounis syndrome is a difficult to diagnose entity that requires a high index of suspicion in the evaluation of patients with chest pain in the Emergency Department.

### RESUMEN

**Antecedentes:** El síndrome de Kounis fue descrito en 1991 como la aparición simultánea de eventos coronarios agudos y reacciones alérgicas anafilácticas. Casos clínicos y pequeñas series de casos de angina generada por reacciones alérgicas han sido reportados en varios años. Engloba conceptos como el de angina alérgica e infarto alérgico. **Caso clínico:** Presentamos un caso clínico de un hombre de 47 años de edad, con antecedentes de eritema fijo medicamentoso desde hace 10 años. Acude al Departamento de Emergencia por presentar dolor torácico de moderada intensidad, se realiza electrocardiograma el cual es compatible con síndrome coronario agudo sin elevación del segmento ST. Evolucionó favorablemente con tratamiento según protocolo. El estudio posterior demostró hipersensibilidad a antiinflamatorios no esteroideos y las pruebas de estratificación de isquemia cardiovascular fueron negativas, por lo que se concluyó como un caso de angina alérgica. **Conclusiones:** El síndrome de Kounis es una entidad de difícil diagnóstico que requiere un alto índice de sospecha en la valoración de pacientes con dolor torácico en el Departamento de Emergencia.

### INTRODUCTION

A simultaneous occurrence of acute coronary events and anaphylactic allergic reactions was described by Kounis and Zavras in 1991. Possible etiologies of Kounis syndrome (KS) have been recognized as food, environmental, and drug reactions associated or not with previous cardiovascular risk factors.<sup>1-3</sup>

According with the 2010 Acute Myocardial Infarction Delay study cut, which includes more

than 120 Spanish hospitals, acute myocardial infarction with transient ST-segment elevation represents 4.6% of all cases that are admitted to the Intensive Care Unit, where the most KS cases are, representing a small part of this etiology.<sup>4</sup>

The KS has been divided into 3 subtypes: Type I (without coronary disease), characterized by chest pain during allergic reactions in patients without risk factors, with secondary electrocardiographic changes and normal

\* Médico tratante de Medicina Interna.  
\*\* Médico tratante de Cardiología.  
\*\*\* Médico General de Atención Primaria.  
\*\*\*\* Médico Familiar.  
\*\*\*\*\* Médico General residente de Emergencia.

Hospital Provincial Puyo, Ministerio de Salud Pública, Ecuador.

Received:  
17/09/2017  
Accepted:  
21/02/2018

cardiac enzymes, or progression to acute myocardial infarction. Type II (with coronary disease): it starts with chest pain during an allergic reaction, in patients with atheromatous disease who present plaque rupture and release of activated mediators, yielding to the development of acute myocardial infarction.<sup>2,5</sup> Type III. Recently described as thrombosis of drug-eluting stent, due to the infiltration of mast cells and eosinophils identified by Giemsa and hematoxylin-eosin staining.<sup>6,7</sup>

Although any drug can trigger an allergic reaction, the most frequently signaled are beta-lactams antibiotics, non-steroidal anti-inflammatory medications (NSAIDs), general anesthetics and iodinated contrast agents.<sup>8</sup>

### CASE REPORT

We present the case of a 47 year-old male patient, public employee, born in Mera, resident in Puyo City (Pastaza-Ecuador), with a history of atopic dermatitis since childhood and sulfonamides drug-related fixed erythema 10 years ago. Three months prior to admission the patient presented acute pharyngitis, which was treated with ibuprofen prescribed by primary care physician. Subsequently, he had pruritus on his elbows and knees with periods of exacerbation and spontaneous remission. Two days prior to admission he reported having suffered generalized headache, so he ingested ibuprofen in an auto-medicated way, after

which he had precordial pain of moderate intensity, that not improved with rest and was accompanied by palpitations. He was admitted to the emergency room, where a blood pressure of 100/60 mmHg, a heart rate of 120 beats per minute and body temperature of 36.2 °C were found. ECG showed sinus rhythm and ischemic changes (*Figure 1*). Cardiac enzymes were normal. Treatment was established by protocol for non-ST elevation acute coronary syndrome (NSTEMACS). During the hospitalization, pruritus at the level of elbows, buttocks and abdomen recurred associated with scaly erythematous lesion converging in plaques. A skin biopsy was performed which reported superficial and deep perivascular dermatitis with eosinophilic infiltrate compatible with drug reaction and atopic dermatitis; allergic test was performed which was positive for NSAIDs. The risk of ischemia subsequent of NSTEMACS was stratified with an ergometric test with Bruce protocol, reaching 98% of the estimated heart rate for the age without presenting symptoms or electrocardiographic alterations. CT scan did not reveal any coronary lesions (*Figure 2*).

It was concluded, in view of NSTEMACS associated to a manifest allergic process, that the patient had a type I of KS. Prednisone was prescribed in tapering doses while loratadine; clopidogrel, bisoprolol, simvastatin, acetylsalicylic acid were suspended. The evolution has been favorable and until now the patient has remained asymptomatic. No

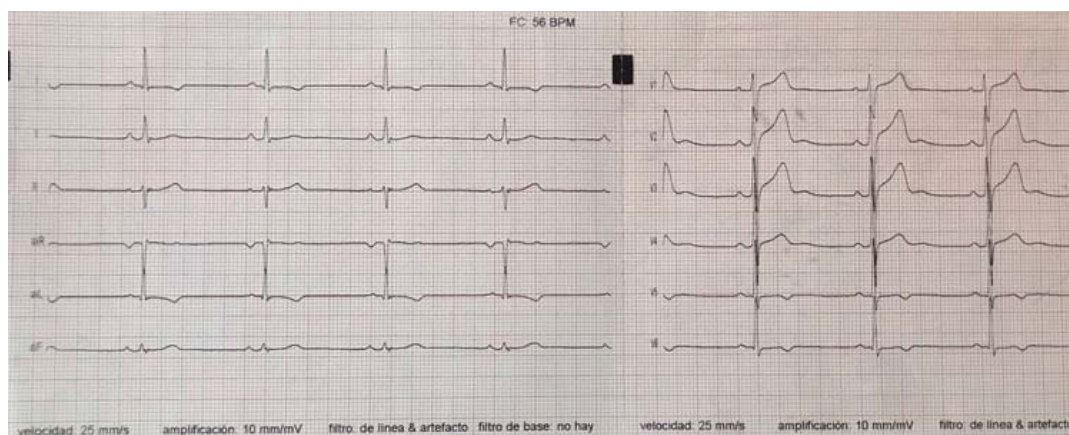


Figure 1. 12-lead electrocardiogram on admission with chest pain, symmetric inverted T wave in DI, aVL, V5 and V6 leads.

significant changes were observed in the control electrocardiogram (Figure 3).

### DISCUSSION

KS is a condition, frequently underdiagnosed and with poorly understood epidemiology. Diagnosis can be done from clinical suspicion,

when allergic signs and symptoms are accompanied with coronary events.

In the analysis of an international database of pharmacovigilance, 51 cases of KS were identified, occurring more often in male subjects (prevalence 63%) between 22 and 46 years. The drugs more commonly found involved were NSAIDs (31 cases reported).<sup>9</sup>

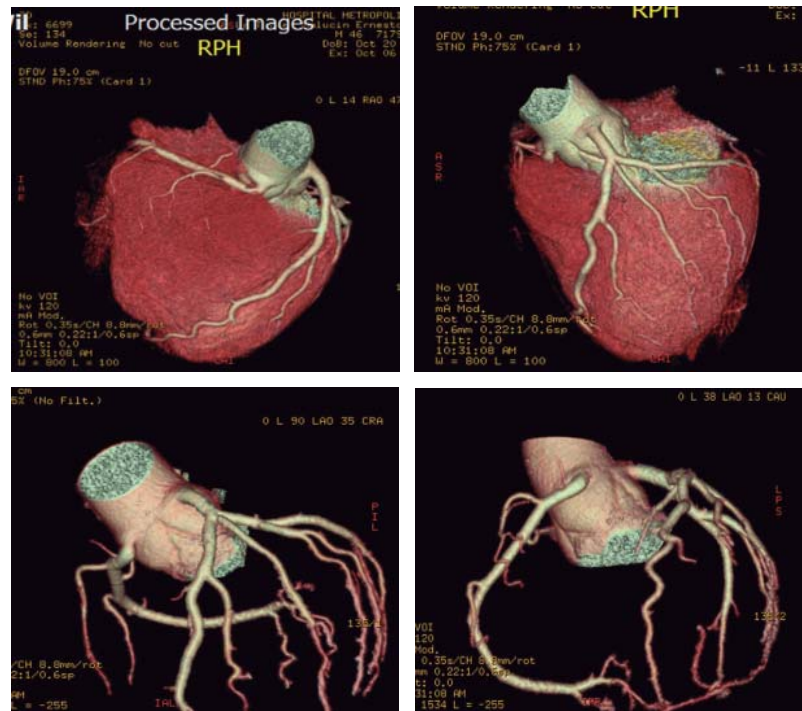


Figure 2.

Reconstruction 3D angiogram of normal coronary arteries calcium score 0.

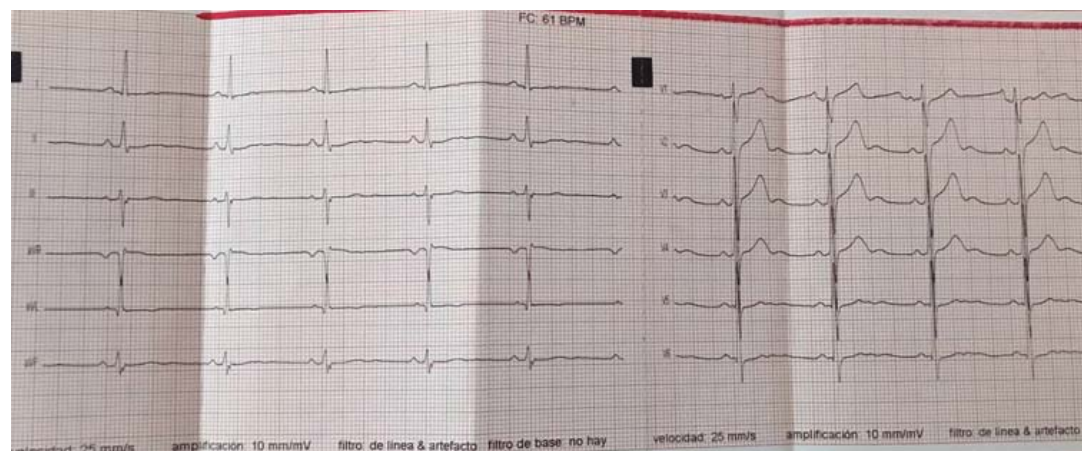


Figure 3. Evolutionary 12-lead electrocardiogram asymptomatic patient, positive T wave in V5 and V6 leads and flat in DI and aVF leads.

The treatment of KS should counteract allergy and cardiac symptoms: corticosteroids with H1 and H2 inhibitors, are the most useful antihistamines since drugs such as vasodilators, nitrates or calcium channels blockers may worsen the condition, reversing their cardiovascular effect and producing hypotension and tachycardia. According to the Galaxy guideline, adrenaline is a drug of first choice in anaphylaxis but its use in Kounis syndrome is risky because it can provoke arrhythmias, prolongation of QT interval, aggravate myocardial ischemia or cause vasospasm. For all these reasons its use is restricted.<sup>8-10</sup>

When we are facing a KS type I, treating the allergic symptoms may be a priority whereas, when treating a patient with previous coronary disease, a simultaneous treatment is necessary. The utility of acetylsalicylic acid is unknown in KS since it can aggravate anaphylaxis or even be a cause of an allergic reaction, but when its use is essential must be administered in the intensive care unit. Patients with KS type II and known allergy to aspirin may be candidates for desensitization.<sup>6</sup>

### CONCLUSIONS

The KS is an underdiagnosed entity due to a lack of knowledge of its pathophysiology. So far, this case is the second reported in Ecuador<sup>11</sup> and the first one associated with NSAIDs. Finally, as in the international literature there is no guide for the management of KS, it has crucial importance that clinicians, cardiologists, emergency room specialists and primary care physicians know how to recognize the association of allergic reactions with acute coronary syndromes, to establish the earliest and more accurate treatment, according to the needs of the patient.

**Conflict of interests:** The authors declare no conflict of interest.

### REFERENCES

1. Kounis NG, Zavras GM. Histamine-induced coronary artery spasm: the concept of allergic angina. *Br J Clin Pract.* 1991; 45 (2): 121-128.
2. Rico CP, Palencia HE, Rodríguez AM. Kounis syndrome. *Med Intensiva.* 2012; 36 (5): 358-364.
3. Kounis NG, Soufras GD, Hahalis G. Anaphylactic Shock: Kounis hypersensitivity-associated syndrome seems to be the primary cause. *N Am J Med Sci.* 2013; 5 (11): 631-636.
4. Latour-Pérez J, Cabello JB. Clinical significance of acute coronary syndrome with transient ST-segment elevation. *Med Intensiva.* 2011; 35 (5): 267-269.
5. Kogias JS, Papadakis EX, Tsatiris CG, Hahalis G, Kounis GN, Mazarakis A et al. Kounis syndrome: a manifestation of drug-eluting stent thrombosis associated with allergic reaction to contrast material. *Int J Cardiol.* 2010; 139 (2): 206-209.
6. Pampín HF, Jorge M, Prado R, Vázquez VR, Luis A. Acute hypersensitivity coronary syndrome: Kounis syndrome. *Galicía Clin.* 2014; 751: 31-32.
7. Kounis NG. Coronary hypersensitivity disorder: the Kounis syndrome. *Clin Ther.* 2013; 35 (5): 563-571.
8. Tavil Y, Turfan M, Türkoğlu S, Abaci A. Kounis syndrome secondary to amoxicillin/clavulanic acid use. *Int J Cardiol.* 2008; 124 (1): e4-7.
9. Lombardi N, Pugi A, Maggini V, Lenti MC, Mugelli A, Cecchi E et al. Underdiagnosis and pharmacovigilance. The case of allergic acute coronary syndrome (Kounis syndrome). *Int J Cardiol.* 2013; 168 (5): 5054-5055.
10. Cardona Dahl V; Grupo de trabajo de la Guía GALAXIA de actuación en anafilaxia. Guideline for the management of anaphylaxis. *Med Clin (Barc).* 2011; 136 (8): 349-355.
11. Narváez N, Poma R, Cobos M, Salazar R, Orbe V. Case report: cardiogenic shock secondary to beta-lactam-induced kounis type I syndrome. *REC-online.* 2016; 2: 1-7.

### Correspondence to:

**Dr. Paúl Santiago Martínez Torres**  
 Paseo de los Cañaris y Hernando Leopulla,  
 010104, Cuenca, Ecuador.  
 Tel: 593 995170339  
 E-mail: poolmartinez04@hotmail.com

[www.medigraphic.org.mx](http://www.medigraphic.org.mx)