

## Long QT syndrome secondary to drug interaction between hydroxychloroquine and amiodarone

*Síndrome de QT largo secundario a la interacción entre hidroxiclороquina y amiodarona*

Tomás Miranda-Aquino,\* Silvia Esmeralda Pérez-Topete,\*\* Williams Ortega-Pantoja,\* Carlos Alejandro Gómez-Vázquez,\* Luis Gilberto Meneses-Pérez,\* Christian González-Padilla,\*\*\* Oscar Sergio Lomelí-Sánchez,\*\*\* Jorge Eduardo Hernández-Del Río,\*\*\* Emma Purón-González\*\*\*\*

### Key words:

Long QT syndrome, hydroxychloroquine, amiodarone, systemic lupus erythematosus.

### Palabras clave:

*Síndrome de QT largo, hidroxiclороquina, amiodarona, lupus eritematoso sistémico.*

\* Cardiology Resident. Hospital Civil Guadalajara «Fray Antonio Alcalde».  
\*\* Rheumatology Resident. Hospital Civil Guadalajara «Fray Antonio Alcalde».  
\*\*\* Cardiologist. Hospital Civil Guadalajara «Fray Antonio Alcalde».  
\*\*\*\* Internal Medicine Resident. Hospital Christus Muguerza Alta Especialidad.

Received:  
24/04/2018  
Accepted:  
12/06/2018

### ABSTRACT

A 67-year-old female patient with a diagnosis of heart failure with preserved ejection fraction secondary to severe mitral regurgitation in treatment with metoprolol, spironolactone, and digoxin. She was diagnosed systemic lupus erythematosus (SLE) because of the presence of arthritis, alopecia, thrombocytopenia, direct positive Coombs +++, positive ANAs 1:1,280 and positive lupus anticoagulant. The rheumatology service indicated hydroxychloroquine 200 mg every 24 hours. She presented atrial fibrillation, and amiodarone was initiated. Two weeks later the patient was admitted because of presyncope, electrocardiogram showed sinus bradycardia with long QT interval. A temporary pacemaker was placed, and hydroxychloroquine and amiodarone suspended. Twenty-four hours later, a new electrocardiogram was taken showing pacemaker rhythm with reduction of the QT interval. After 72 hours the temporary pacemaker was removed and on the fifth day the patient was discharged with an electrocardiogram in sinus rhythm with a corrected QT (Bazett) of 456 milliseconds. The hydroxychloroquine was reinitiated following discharge. She presented another episode of atrial fibrillation, and was treated with amiodarone, hydroxychloroquine was suspended previously, and she did not present prolongation of QT interval. The long QT syndrome was present when amiodarone and hydroxychloroquine interacted.

### RESUMEN

*Paciente femenina de 67 años, con diagnóstico de insuficiencia cardíaca con fracción de expulsión preservada, secundaria a insuficiencia mitral severa, en tratamiento con metoprolol, espironolactona y digoxina. Le fue diagnosticado lupus eritematoso sistémico, debido a la presencia de artritis, alopecia, trombocitopenia, Coombs directo positivo +++, anticuerpos antinucleares positivos 1:1,280 y anticoagulante lúpico positivo. El Servicio de Reumatología indicó hidroxiclороquina 200 mg cada 24 horas. Presentó fibrilación auricular, por lo que se le inició amiodarona. Dos semanas posteriores la paciente es ingresada debido a un episodio de presíncope, se le realizó electrocardiograma que demostró bradicardia sinusal con un intervalo QT prolongado. Se le colocó un marcapasos temporal, además de que se suspendió hidroxiclороquina y amiodarona. Después de 72 horas se retiró el marcapasos, y al quinto día se egresó con un electrocardiograma en ritmo sinusal con el intervalo QT corregido por Bazett de 456 milisegundos. La hidroxiclороquina fue reiniciada al egreso. La paciente presentó otro episodio de fibrilación auricular y fue tratada con amiodarona, previa suspensión de hidroxiclороquina, sin presentar prolongación del intervalo QT. El síndrome de QT largo sólo se presentó con la interacción de amiodarona con hidroxiclороquina.*

### INTRODUCTION

The prolongation of the QT interval is the result of abnormal repolarization, mainly in the third phase of the repolarization of

the ventricular myocardium, resulting in the lengthening of the QT interval in the electrocardiogram.<sup>1</sup>

The QT interval is prolonged when it lasts greater than 470 milliseconds in women and

greater than 450 milliseconds in men.<sup>1</sup> There are many formulas to correct the QT interval but the Bazett formula ( $QTc = QT/\sqrt{RR}$  in seconds), however, it's only accurate when the heart rate is between 60-100 bpm. The Fredericia formula ( $QTc = QT/(RR)^{1/3}$ ) or Framingham's formula ( $QTc = QT + 0.154(1-RR)$ ) are most commonly used for higher or lower heart rates.

Several causes have been described for lengthening the QT interval, for example congenital mutations in the ion channels of the cardiac myocytes, or acquired causes, by drugs or alterations in electrolytes, mainly.<sup>2</sup>

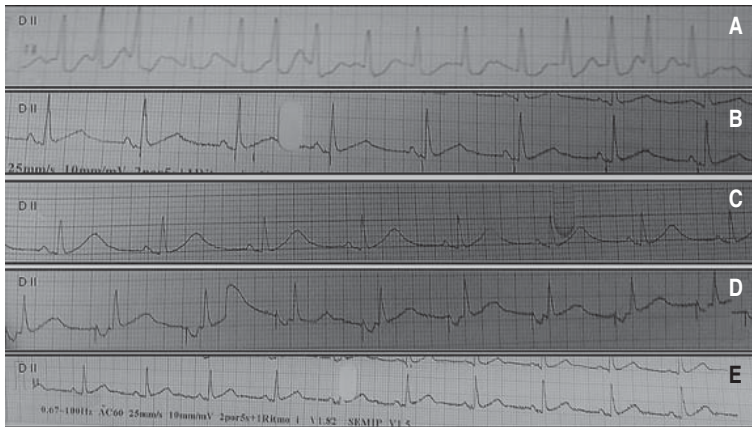
It's a pathology that has been increasing its clinical interest owing to its association with ventricular arrhythmias, such as Torsades de Pointes. The clinical manifestations range from asymptomatic patients to syncope or sudden death secondary to ventricular arrhythmias.<sup>2</sup>

The list of drugs that have been associated with the prolongation of the QT interval is increasing which can be verified in the page [www.qtdrugs.org](http://www.qtdrugs.org), where the list is continuously updated. The following clinical case presented is a long QT syndrome associated with the interaction of hydroxychloroquine and amiodarone. There is sporadic literature linking hydroxychloroquine with long QT syndrome.

### CASE REPORT

A 67-year-old female patient with a diagnosis of heart failure with preserved ejection fraction secondary to severe mitral regurgitation in treatment with metoprolol, spironolactone, and digoxin. The patient was admitted attributable to acute heart failure with acute pulmonary edema and a blood pressure of 80/60 mmHg, heart rate of 110 bpm, respiratory rate of 20 rpm saturating at 80%. For this reason, orotracheal intubation and vasopressor support was initiated. Within the laboratory studies: hemoglobin 11.5 g/dL, leukocytes 10,100/cc with 8,000/cc neutrophils, platelets 12,200/cc, PT 11.5, INR 1.1, PTT 120, glucose 94 mg/dL, urea 76, creatinine 0.9 mg/dL, sodium 141 mmol/L, potassium 4.1 mmol/L, chloride 110 mmol/L, calcium 8.7 mg/dL, troponin I < 0.05 ng/mL, BNP 780 ng/mL. The

patient was admitted to the coronary care unit and a transthoracic echocardiography was performed reporting LVEF 58%, global mobility without alterations, a severe degree of atrial dilatation, severe mitral insufficiency secondary to prolapse of the anterior leaflet. By reason of the prolonged PTT, differential diagnosis was investigated and the diagnosis of systemic lupus erythematosus (SLE) was made owing to the presence of arthritis, alopecia, thrombocytopenia, direct positive Coombs + + +, positive ANAs 1:1,280 and positive lupus anticoagulant. The rheumatology service indicated hydroxychloroquine 200 mg every 24 hours. On the second day of hospitalization the patient had improved without the need of mechanical ventilation or vasopressor support. However, the patient presented atrial fibrillation (*Figure 1A*) and amiodarone 300 mg was administered in bolus and a subsequent dose of 900 mg for 24 hours; the following day the patient was in sinus rhythm (*Figure 1B*). The patient was discharged on the fifth day with furosemide 20 mg qid, amiodarone 200 mg qid, warfarine 2.5 mg qid, hydroxychloroquine 200 mg qid. Two weeks later the patient was admitted because of a new episode of acute heart failure and presyncope. The patient's vital signs were blood pressure of 110/70 mmHg, heart rate of 40 bpm, respiratory rate of 20 rpm and a saturation of 88%. An electrocardiogram was taken (*Figure 1C*) which showed sinus bradycardia with a QT interval corrected by Bazett of 639 milliseconds, Framingham 679 milliseconds, and Friderica 652 milliseconds. Ischemic heart disease and electrolyte alterations were ruled out. Because of the episodes of presyncope, it was classified as symptomatic bradycardia with long QT syndrome. A temporary pacemaker was placed, and hydroxychloroquine and amiodarone suspended because of the suspected drug interaction that led to QT prolongation. 24 hours later a new electrocardiogram was taken (*Figure 1D*) showing pacemaker rhythm with a corrected QT interval (Bazett): 560 milliseconds. After 72 hours the temporary pacemaker was removed and on the fifth day the patient was discharged with an electrocardiogram in sinus rhythm with a corrected QT interval (Bazett): 456



**Figure 1.** Electrocardiograms in the DII lead, 25 mm/second, 10 mm/mV. **A.** Atrial fibrillation rhythm. **B.** Sinus rhythm QTc 460 milliseconds. **C.** Sinus bradycardia, HR 52 bps, QTc Bazett 639 milliseconds, Framingham 679 milliseconds, Friderica 652 milliseconds. **D.** Pacemaker rhythm, QTc Bazzet 560 milliseconds. **E.** Sinus rhythm, QTc Bazett 456 milliseconds.

milliseconds (*Figure 1E*). Hydroxychloroquine was reinitiated following discharge. The patient was offered a mitral valve replacement, but she refused. During the following four months the patient was admitted on multiple occasions for atrial fibrillation and acute heart failure which was treated with amiodarone, and hydroxychloroquine suspension. As previously done, upon discharge the patient reinitiated hydroxychloroquine and metoprolol was given for rate control. Six months later the patient had a surgical mitral valve replacement but unfortunately died in the postoperative, as a result of, vasoplegic shock.

## DISCUSSION

The acquired long QT syndrome is an electrophysiological cardiac disorder, which has mainly been described to be caused by drugs in which the early and late potassium channels are modified in phase three of cardiac repolarization.<sup>3</sup> It has been described that drugs prolong the QT by inhibiting the KCNH2 potassium channel, encoded in the HERG gene.<sup>4</sup> This gene mutation is also observed in long QT syndrome type 2.

In our patient several risk factors for presenting prolongation of the QT interval are present such as female gender, as suggested by

Drici MD et al;<sup>5</sup> they suggest that there may be a greater response to drugs that prolong the QT interval because of sex hormones that can modify the expression of the channels. Another risk factor is that the patient had SLE, it has been suggested that QT prolongation may be secondary to autonomic dysfunction in patients with SLE.<sup>6</sup>

The hydroxychloroquine was used in patients with rheumatic disease since 1955. It is like chloroquine, but with a hydroxyethyl group instead of the chloroquine ethyl group.<sup>7</sup> The use of hydroxychloroquine is increasing, especially since it is well tolerated with less adverse reactions.<sup>7</sup> Its most frequent adverse reactions are gastrointestinal and neurotoxicity; retinal toxicity is rare.<sup>7</sup> A widening of the QRS, prolongation of the QT, ventricular arrhythmias, hypokalemia and hypotension have also been reported.<sup>8</sup> It has been proposed that hydroxychloroquine acts in the activated current of depolarization of the ion channels (I<sub>f</sub>), and in the currents of the calcium ions (I<sub>CaL</sub>).<sup>9</sup> Currently the FDA has an alert for QT interval monitoring in patients under treatment with hydroxychloroquine, especially in those in which they are combined with any other medication known to prolong the QT interval.

Amiodarone is the most widely used antiarrhythmic agent, and its efficacy has been seen in supraventricular and ventricular arrhythmias. The high incidence of prolongation of the QT interval has been reported, however, a very low incidence of ventricular arrhythmias has been reported attributable to amiodarone.<sup>10</sup>

## CONCLUSIONS

In conclusion, prolongation of the QT interval is of great clinical importance, due to its association with ventricular arrhythmias. Both amiodarone and hydroxychloroquine have been described as drugs associated with QT prolongation therefore close electrocardiographic monitoring should be used, especially in susceptible patients.

**Conflict of interest:** the authors declare that there is no conflict of interest.

## REFERENCES

1. Moss AJ. Long QT syndrome. JAMA. 2003; 289 (16): 2041-2044.
2. O'Laughlin JP, Mehta PH, Wong BC. Life threatening severe QTc prolongation in patient with systemic lupus erythematosus due to hydroxychloroquine. Case Rep Cardiol. 2016; 2016: 4626279.
3. Sheehan ET, Frizzell JD, Gabaldon J, West MB. Quinine and the ABCs of long QT: a patient's misfortune with arthritis, (alcoholic) beverages, and cramps. J Gen Intern Med. 2016; 31 (10): 1254-1257.
4. Katchman AN, Koerner J, Tosaka T, Woosley RL, Ebert SN. Comparative evaluation of HERG currents and QT intervals following challenge with suspected torsadogenic and nontorsadogenic drugs. J Pharmacol Exp Ther. 2006; 316 (3): 1098-1106.
5. Drici MD, Clément N. Is gender a risk factor for adverse drug reactions? The example of drug-induced long QT syndrome. Drug Saf. 2001; 24 (8): 575-585.
6. Nomura A, Kishimoto M, Takahashi O, Deshpande GA, Yamaguchi K, Okada M. Prolongation of heart rate-corrected QT interval is a predictor of cardiac autonomic dysfunction in patients with systemic lupus erythematosus. Rheumatol Int. 2014; 34 (5): 643-647.
7. Nord JE, Shah PK, Rinaldi RZ, Weisman MH. Hydroxychloroquine cardiotoxicity in systemic lupus erythematosus: a report of 2 cases and review of the literature. Semin Arthritis Rheum. 2004; 33 (5): 336-351.
8. Chen CY, Wang FL, Lin CC. Chronic hydroxychloroquine use associated with QT prolongation and refractory ventricular arrhythmia. Clin Toxicol (Phila). 2006; 44 (2): 173-175.
9. Capel RA, Herring N, Kalla M, Yavari A, Mirams GR, Douglas G et al. Hydroxychloroquine reduces heart rate by modulating the hyperpolarization-activated current If: Novel electrophysiological insights and therapeutic potential. Heart Rhythm. 2015; 12 (10): 2186-2194.
10. Nafrialdi, Kurniawan TG, Setiawati A, Makmun LH. QT interval prolongation associated with amiodarone use in Cipto Mangunkusumo Hospital, Jakarta. Acta Med Indones. 2014; 46 (4): 292-297.

Correspondence to:

**Tomás Miranda-Aquino**  
Maracaibo 2961, Int. 301,  
Col. Colomos Providencia, 44660,  
Guadalajara, Jalisco, México.  
Tel: 8110622355  
E-mail: tomas\_miranda\_a@hotmail.com