

TAVI in Intermediate-risk patients: a review in purpose of a case

TAVI en pacientes de riesgo intermedio: una revisión a propósito de un caso

Héctor Hugo Escutia-Cuevas,* José Alfredo Merino-Rajme,**
Marco Antonio Alcántara-Meléndez,** Manuel Armando Espinoza-Rueda,*
Ernesto Fernández-Ceseña,** Juan Francisco García-García,**
Julieta Danira Morales-Portano,** Roberto Muratalla-González,*
Bayardo Antonio Ordoñez-Salazar*

Key words:

Aortic valve replacement, TAVR, TAVI, intermediate-risk.

Palabras clave:

Cambio valvular aórtico, TAVR, TAVI, riesgo intermedio.

* Servicio de Cardiología Clínica.
** Servicio de Hemodinámica e Intervencionismo Estructural.
*** Laboratorio de Ecocardiografía.

División de Cardiología y Cirugía Cardiorrástica, Centro Médico Nacional «20 de Noviembre», ISSSTE, Ciudad de México, México.

Received:
18/10/2017
Accepted:
08/06/2018

ABSTRACT

Background: Aortic stenosis is the most common valvular heart disease worldwide. The prognosis is adverse without a valve replacement. Transcatheter aortic valve implantation (TAVI) has proven to be an effective treatment in high-surgical risk patients. Recent trials have highlighted the non-inferiority of TAVI compared with open surgery in patients with intermediate surgical risk. **Case report:** A 76-year-old man with severe aortic stenosis and intermediate surgical risk (STS-PROM 4.8%) who underwent TAVI with no complications. **Results:** Hospital discharge was decided five days after the procedure and continued outpatient follow-up. After two years remains in NYHA functional class I with a normofunctional percutaneous prosthesis. **Conclusion:** As this clinical case shows, TAVI has proven to be an effective treatment in patients with aortic stenosis and intermediate surgical risk. This is the first experience in this type of patients reported in our country.

RESUMEN

Antecedentes: La estenosis aórtica es la valvulopatía más común en todo el mundo. El pronóstico es sombrío sin reemplazo valvular. La implantación valvular aórtica transcáteter (TAVI) ha demostrado ser un tratamiento eficaz en pacientes de alto riesgo quirúrgico. Ensayos muy recientes destacaron la no-inferioridad de TAVI en comparación con la cirugía abierta en pacientes con riesgo quirúrgico intermedio. **Caso clínico:** Se presenta un hombre de 76 años de edad con estenosis aórtica severa y riesgo quirúrgico intermedio (STS-PROM 4.8%), al que se realiza TAVI sin complicaciones. **Resultados:** El alta hospitalaria se decide cinco días después del procedimiento para continuar el seguimiento ambulatorio. Después de dos años, el seguimiento permanece en la clase funcional I de la NYHA con una prótesis percutánea normofuncional. **Conclusión:** Como muestra este caso clínico, TAVI ha demostrado ser un tratamiento eficaz en pacientes de riesgo quirúrgico intermedio. Ésta es la primera experiencia en el uso de esta tecnología en este tipo de pacientes reportada en nuestro país.

INTRODUCTION

Aortic stenosis is the most common valvular heart disease worldwide. About 7% of the population over 65 years-old suffers degenerative aortic stenosis. The prognosis of patients with symptomatic severe aortic stenosis is dismal without valve replacement. Approximately one third of patients over 75 years are not referred for surgery.¹ Severe

symptomatic aortic stenosis (AS) is fatal, the mortality rate is about 50% after two years.² Aortic valve replacement (AVR) is the only treatment that has proven to be helpful strengthening the survival prospects.³ In 2002, Cribier and colleagues performed the first transcatheter aortic valve implantation (TAVI).³ More recently, technology has developed rapidly, by now more than 200,000 transcatheter valves have been implanted

worldwide.⁴ The results of several prospective and randomized multicenter registries and trials⁵⁻¹⁰ have provided definitive data confirming this treatment as an alternative to standard surgical aortic valve replacement (SAVR) for inoperable and high-risk patients. Moreover, other recent trials highlighted the non-inferiority of TAVI compared with open surgery even in patients with intermediate surgical risk,^{11,12} leading an expansion of TAVI to the treatment of an even broader spectrum of patients. Herein we present a clinical case of aortic stenosis and intermediate surgical risk, being the first experience with this technology in this type of patients reported in our country.

CASE REPORT

Male, 73-year-old, history of dyslipidemia and hypertension. Chronic coronary artery disease diagnosed in 2013 and requiring percutaneous coronary intervention and implantation of a zotarolimus-eluting stent in the left anterior descendant artery.

Insidiously started one year after the last coronary angiogram with progressive impairment of functional class. A transthoracic echocardiogram was performed and reported severe aortic stenosis. Initially treated with hydric depletion with loop diuretics and aldosterone receptor antagonist with no improvement despite treatment, being the reason of the patient reference to our institution to assess aortic valve replacement.

Physical examination: blood pressure 120/65 mmHg, heart rate 65 beats/min, respiratory rate 18 breaths/min, temperature 36.5 °C, weight: 78 kg, height 1.65 meters. Jugular plethora grade II, chest auscultation with subscapular and bilateral rales, anterior chest with apex lifting on fifth intercostal space at left midclavicular line, rhythmic cardiac sounds with aortic meso-telesystolic murmur, positive Gallavardin sign, limbs with bilateral ankle oedema, immediate capillary filling and parvus-et-tardus pulse.

Results of laboratory studies: leukocytes 6,500/mm³, Hb 12.3 g/dL, hematocrit 38.2%, platelets 116,000/mm³, neutrophils 4,600/mm³, ureic nitrogen 36 mg/dL, glucose 83 mg/dL, creatinin 0.97 mg/dL, sodium 144 mEq/L, potassium 4.1 mEq/L, chloride 110 mEq/L, trombine time 13.5 secs, trombolastine time 37.9 secs, alanine amine-transferase levels 32 U/L, aspartate amine-transferase 29 U/L, total bilirubin 0.57 mg/dL.

Results of paraclinic studies: 12-lead electrocardiogram (ECG): in sinus rhythm, with posterior right-fascicle hemiblock and non-specific repolarization disorders. Chest X-ray in standard projection with apparent cardiomegaly, increased bilateral vascularity and prominent pulmonary cone (Figure 1A).

Transthoracic and transesophageal echocardiography: showed left ventricular end-diastolic volume of 55 milliliters, systolic volume of 36 milliliters, ejection fraction 68%, with no changes in global or segmental mobility at rest (Figure 2), without thrombi, concentric

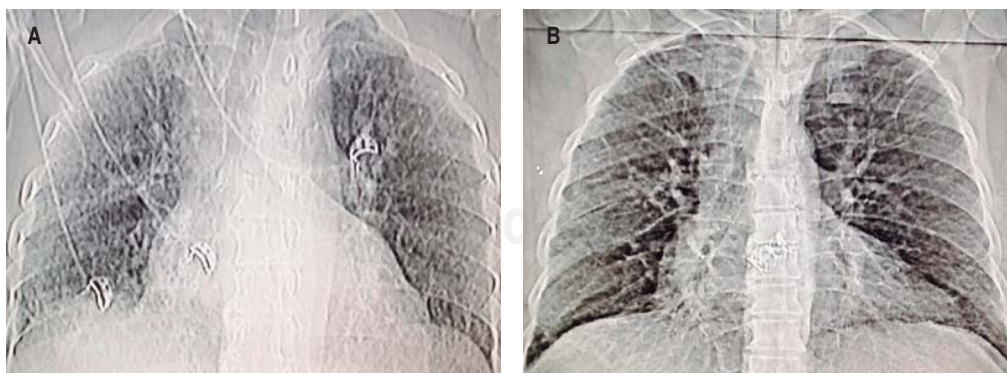


Figure 1. Chest X-ray in anteroposterior projection with cardiomegaly, increased bilateral vascularity and prominent pulmonary cone (A), radiographic outcome after valve implantation (B).

remodeling data; left atrium without thrombi and calculated left atrial volume index (LAVI) of 36 mL/m²; aortic valve trivalve, heavily calcified, with severe stenosis, valve area 0.7 cm², indexed 0.4 cm²/m², mean gradient of 40 mmHg, with no regurgitation (Figure 3). Aorta: aortic annulus 20 mm, aortic root 28 mm. Mitral valve: structurally normal, mild regurgitation. Right ventricle: preserved systolic function, tricuspid annular plane systolic excursion (TAPSE) 22 mm/m², S wave 14 cm/s. Right atrium: without thrombi. Tricuspid valve: structurally normal, no regurgitation, systolic pulmonary artery pressure (SPAP) of 25 mmHg.

Coronary angiogram: no significant stenoses in epicardial vessels (Figure 4).

Femoral angiogram: right common femoral artery with minimum diameter of 7.05 mm, left

femoral with minimum diameter of 6.6 mm, with no angiographic stenoses or tortuosity (Figure 5).

Cardiac computed tomography (cardiac CT): performed in an ECG-gated multi-slice 64-detector equipment. The multiplanar reconstruction in axial plane showed a maximum aortic annulus diameter of 26.6 mm, minimum diameter of 21.6 mm, mean diameter 24.1 mm, annulus perimeter 73.9 mm and annulus area of 42.3 mm² (Figures 6A and 6B). At the level of the coronary cusps it was measured a diameter of 29 mm for the right and non-coronary cusps, 27 mm for the left coronary cusp and aortic root area of 64.6 mm² (Figures 6C and 6D). Right coronary ostia distance of 13.3 mm from the aortic annulus plane, and a 15.3 mm distance from the left main coronary artery ostia (Figures

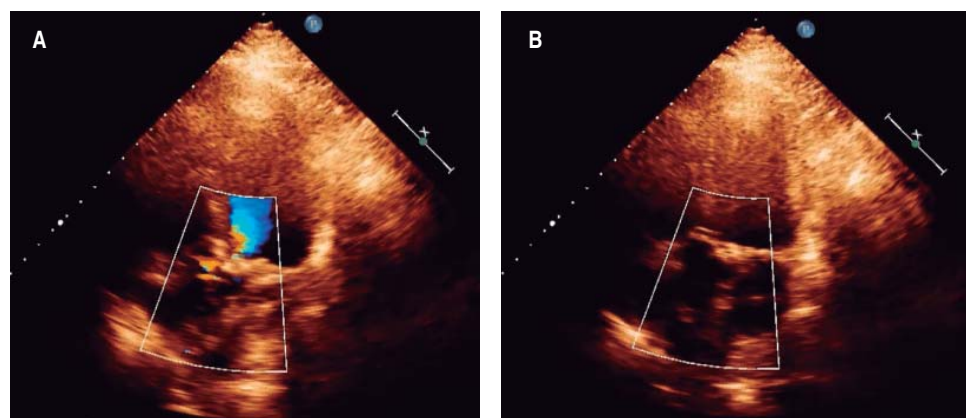


Figure 2. Transthoracic 2D-echocardiogram, four-chamber view and echo-Doppler: showing increased acceleration jet in the left ventricle outflow tract in systole (A) and no regurgitation in diastole (B). See text for further details.

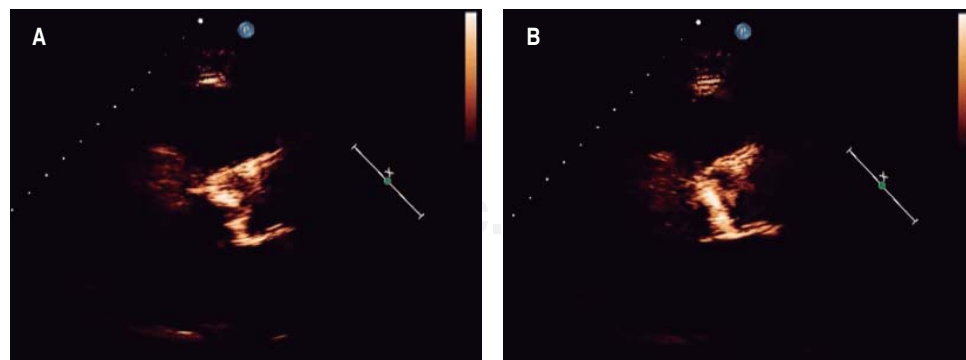


Figure 3. Transthoracic 2D-echocardiogram, long parasternal axis view: showing aortic valve thickened, heavily calcified, with severe stenosis, limited opening in systole (A) and diastole (B). See text for further details.

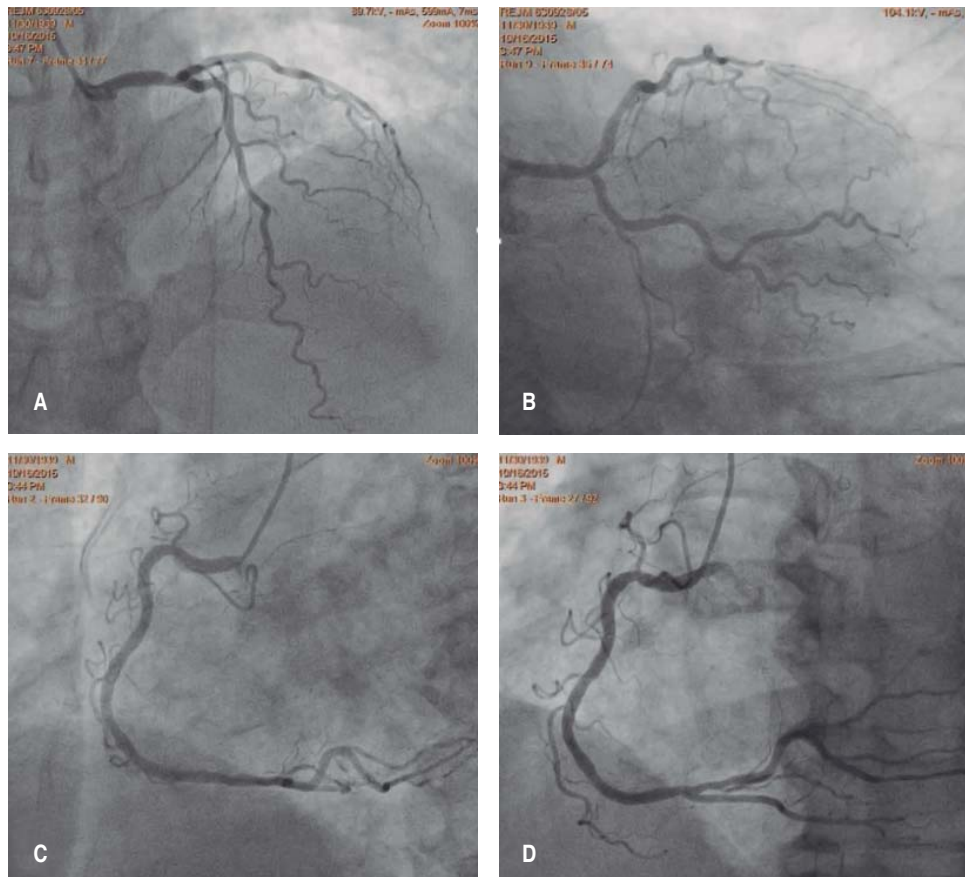


Figure 4. Diagnostic coronary angiogram: without significant angiographic significant stenosis and normal distal flow in both the left coronary system (A and B) and right coronary system (C and D).

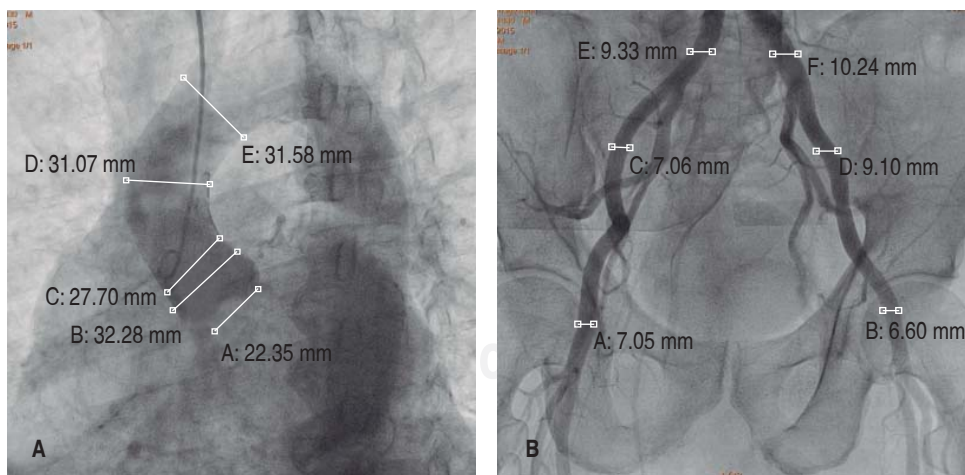


Figure 5. Angiography of aorta in left anterior oblique projection showing radiographic aortic annulus and root diameters (A). Femoral angiogram: showing iliac and femoral vessels without stenosis or tortuosity (B). See text for further details.

7A and 7B). In coronal axis it was measured a 41 degree aortic root angulation (Figure 7C). The 3D-reconstruction showed several calcification in the aortic arch (Figure 7D). Peripheral vessels: Right iliac artery diameter of 11 x 13 mm, left iliac artery 11.8 x 14.8 mm, right common femoral artery 10 x 11 mm and left common femoral artery 9 x 11 mm.

Surgical risks: EuroSCORE II risk of mortality 3.87%, score of the Society of Thoracic Surgeons predictive risk of mortality (STS-PROM) 4.8%. In Heart Team session was proposed to perform TAVI via a transfemoral approach as the best treatment in this patient.

Procedure

Held on in our facilities, with prior informed consent. With modified Seldinger technique are

punctured right and left common femoral artery and right femoral vein, placing a 6 and 7 French (fr) introducers and a temporary pacemaker. The aortic valve was intersected with a 0.035 mm interchange teflonated guidewire, a multipurpose catheter 6 fr was advanced and through in an «Amplatz extra-stiff» guidewire is interchanged and swapped to the left ventricle. In the right femoral artery a 18 fr introducer was placed, advancing the NovaFlex Delivery System (Edwards Lifesciences, Irvine, California) and an Edwards Sapien XT #26 (Edwards Lifesciences, Irvine, California) valve within, after corroborating the proper position (Figure 1B) with fluoroscopy in left anterior oblique projection and pacing at 180 beats per minute the valve is released successfully with mild regurgitation as a result (Figure 8). Transthoracic echocardiography after the procedure shows

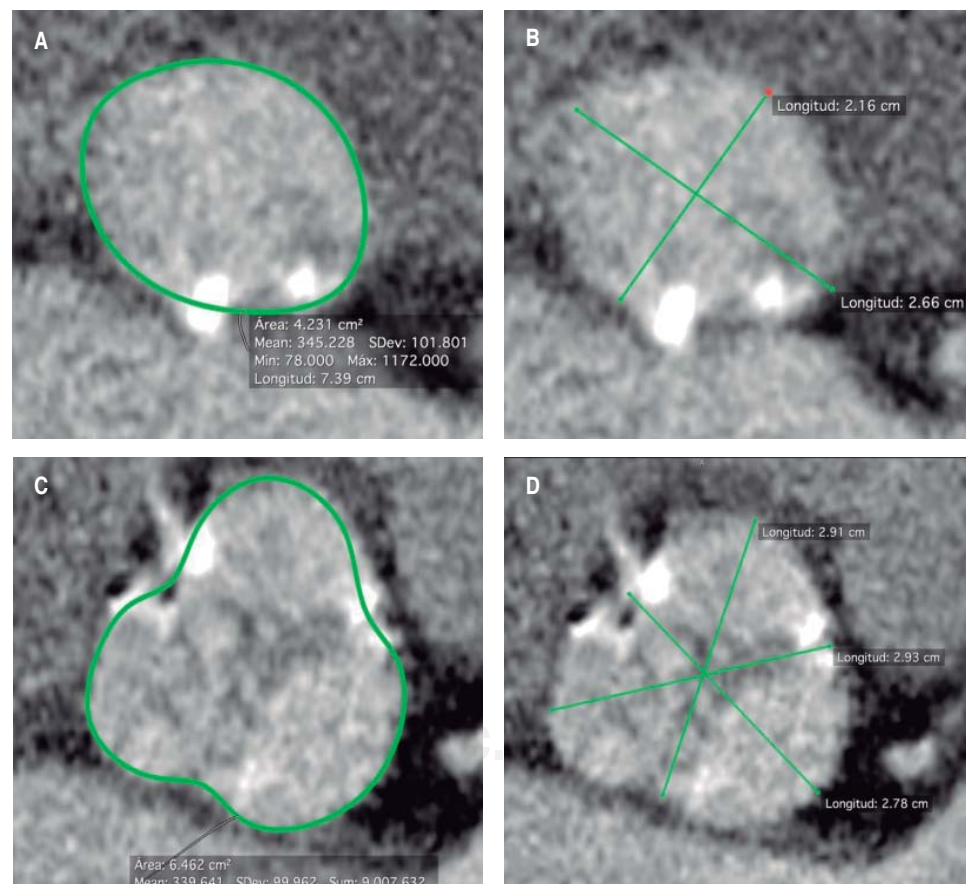


Figure 6. Cardiac computed tomography (cardiac CT) with multiplanar reconstruction in axial plane showing the aortic annulus diameters (A and B) and aortic cusps diameters (C and D). See text for further details.

adequate valve deployment, identifying no paravalvular leak, appropriate opening/closure and mild regurgitation, mean gradient of 6 mmHg and peak velocity 1.7 m/seg. Introducers and delivery system are removed, considering the procedure as successful.

The patient was transferred to an intensive coronary care unit, without immediate complications, with no need of amines or mechanical ventilation. Within 72 hours pacemaker was removed remaining in sinus rhythm and adequate heart rate. The hospital discharge is decided five days after the procedure to continue outpatient follow-up being in NYHA functional class I.

After two-year follow-up the patient remains in NYHA functional class I. Transesophageal echocardiogram shows a non-dilated left

ventricle with ejection fraction of 80%; normo-functional percutaneous aortic prosthesis with peak velocity of 2.2 m/seg, maximum gradient 20 mmHg, mean gradient 10 mmHg, valve area 1.2 cm² and mild posterior paravalvular aortic leak; mitral valve with mild regurgitation.

DISCUSSION

Nowadays TAVI is an accepted alternative to surgery in patients with severe aortic stenosis in high surgical risk. In 2016 and 2017, the first randomized studies were published to address the outcomes in intermediate surgical risk patients and showed that TAVI was not inferior to SAVR.¹¹⁻¹³

In PARTNER 2A, 2,032 intermediate-risk patients with severe aortic stenosis were

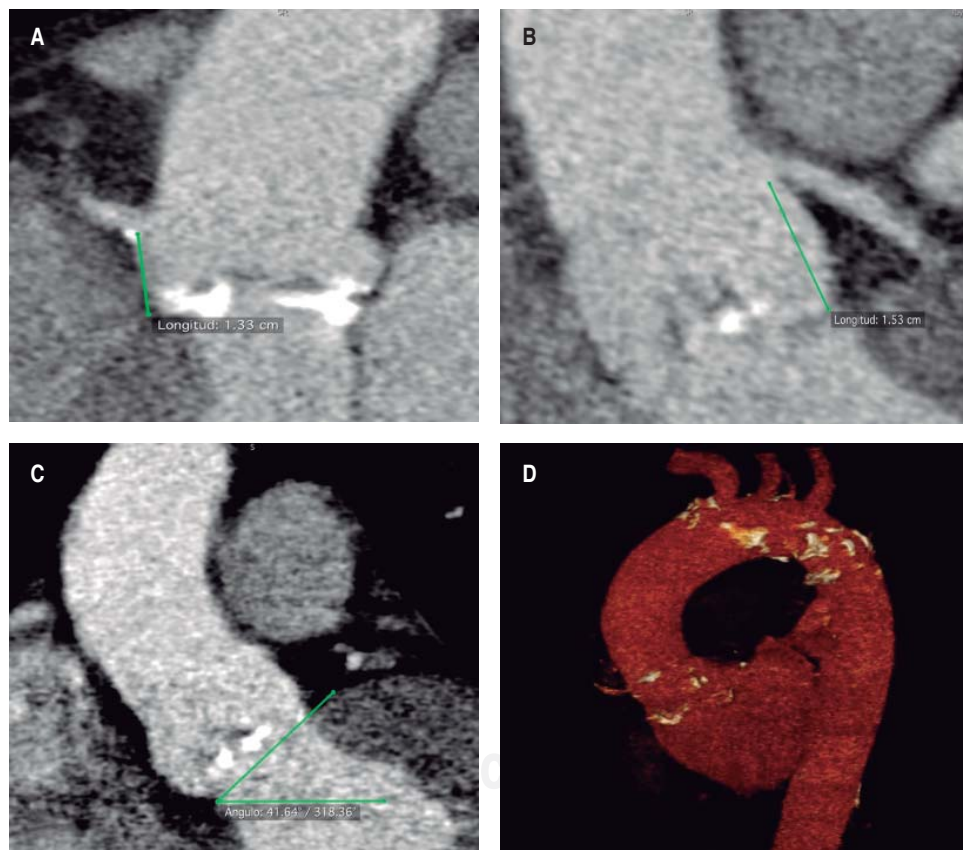


Figure 7. Cardiac CT with multiplanar reconstruction in coronal plane showing right coronary ostia with a distance of 13.3 mm from the aortic annulus plane (A), and a 15.3 mm distance from the left main coronary artery ostia (B), measuring a 41° aortic root angulation (C). The 3D-reconstruction with several calcification in the aortic arch (D). See text for further details.

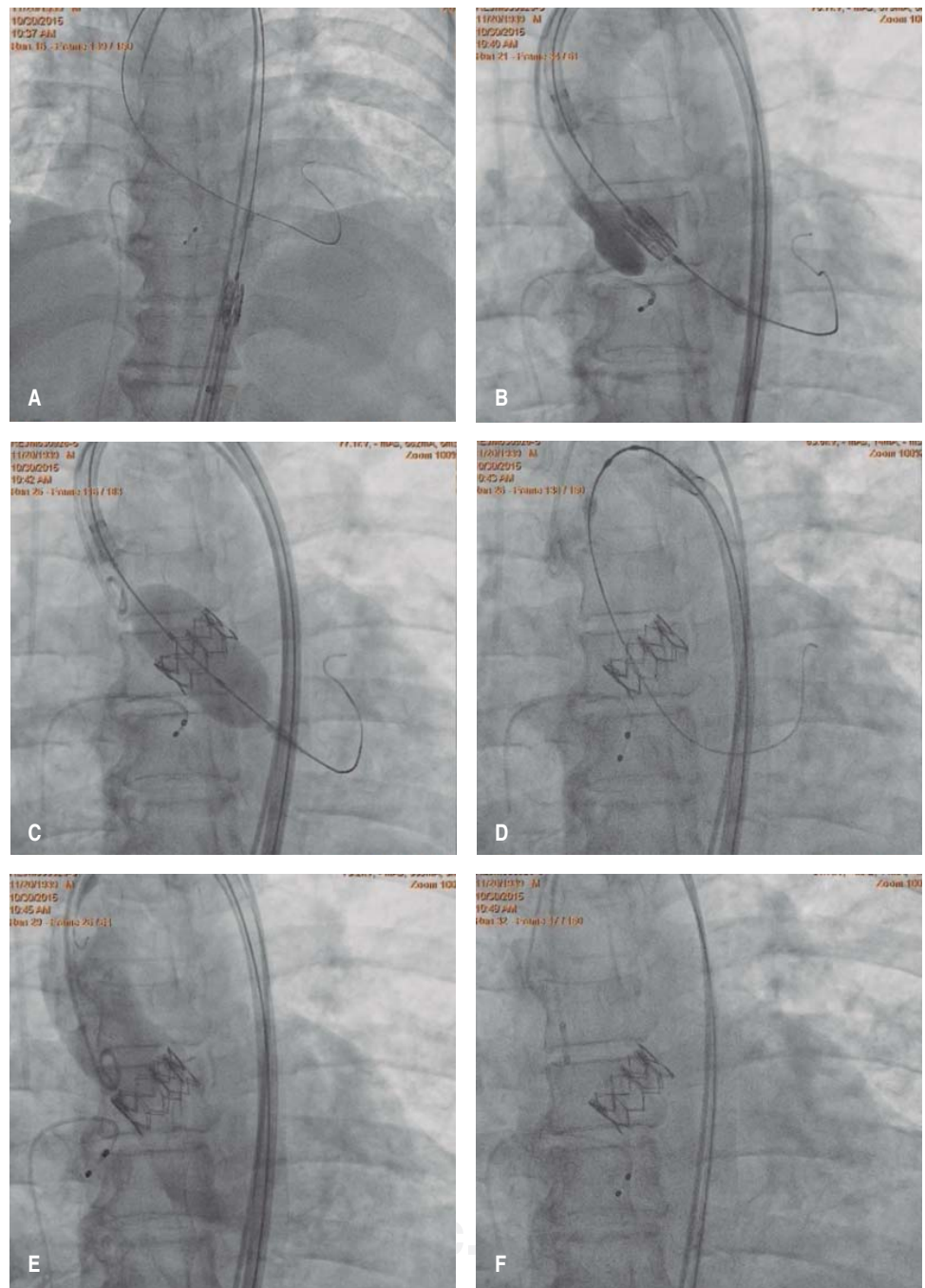

Figure 8. Angiography of aorta in left anterior oblique projection during the TAVI procedure: **A)** The aortic valve is intersected with an «Amplatz extra-stiff» guidewire and is swapped to the left ventricle. **B)** The NovaFlex Delivery System (Edwards Lifesciences, Irvine, California) is advanced with an Edwards Sapien XT #26 (Edwards Lifesciences, Irvine, California) valve, corroborating the proper position. **C)** Balloon valve expansion. **D)** The valve is released successfully. **E)** Resultant mild regurgitation observed in aortography. **F)** Fluoroscopic control after procedure.

randomly assigned to undergo either TAVI with the Edwards SAPIEN XT valve (as this case) or surgical replacement. The primary endpoint was death from any cause or disabling stroke at two years.¹¹ STS risk score was similar in both treatments. After two years the all-cause mortality or disabling stroke was similar in the TAVI group and the SAVR group (19.3% vs. 21.1%, $p = 0.33$ and $p = 0.001$ for non-inferiority). In the transfemoral access cohort, TAVI demonstrated a lower mortality and disabling stroke (hazard ratio = 0.79; 95% CI = 0.62-1.00; $p = 0.05$). TAVI resulted in larger aortic valve areas than did SAVR and also resulted in lower rates of acute kidney injury, severe bleeding, and new-onset atrial fibrillation; SAVR resulted in fewer major vascular complications and less paravalvular aortic leak.

Another study performed a propensity-score analysis including 963 patients treated with SAPIEN-3 TAVI and 747 with SAVR.¹³ For the primary composite endpoint of mortality, stroke, and moderate or severe aortic regurgitation, TAVI was both non-inferior and superior to SAVR. In summary, the propensity score analysis indicated a significant superiority for the composite outcome with TAVI compared with surgery, suggesting that TAVI might be the preferred alternative treatment in intermediate-risk patients.

The SURTAVI trial evaluated the clinical outcomes of 1660 intermediate-risk patients in a randomized trial comparing TAVI using CoreValve (the Evolut-R valve was used in less than 20% of patients) with SAVR.¹² The combined primary endpoint (all-cause mortality or disabling stroke) at 24 months was 12.6% in the TAVI group and 14.0% in the surgery group. SAVR was associated with higher rates of atrial fibrillation, acute kidney injury, and transfusion requirements, whereas residual aortic regurgitation and need for pacemaker implantation were more frequent among TAVI patients. The TAVI resulted in lower mean gradients and larger aortic valve areas than surgery did. Structural valve deterioration at 24 months did not occur in either group. SURTAVI revealed that CoreValve TAVI was not inferior to surgery in patients with intermediate surgical risk.

In the last two years, the PARTNER II and SURTAVI trials demonstrated non-inferiority

of TAVI compared with SAVR in intermediate-risk patients, whereas the NOTION trial and some national observational registries laid the foundation for treatment of low-risk patients. Actually, due to the results of these trials, the 2017 ESC/EACTS Guidelines for the Management of Valvular Heart Disease¹⁴ grants a I-B indication for TAVI in patients at intermediate surgical risk and no other risk factors included in the EuroSCORE II or STS scores (frailty, porcelain aorta, sequelae or chest radiation) if the decision is made by a Heart Team, unlikely the 2017 AHA/ACC Update¹⁵ grants a Ila-BR indication to these patients.

Confirming this, Auffret et al analyzed temporal trends of TAVI in France from 2010 to 2015 and underlined the tendency to treat lower-risk patients, with a reduction in median logistic EuroSCORE from 20.3% (interquartile range, 12.1-30.8%) to 13.6% (interquartile range, 9-21%) over the study period.¹⁶

However, whilst these results are ostensibly encouraging, important caveats remain. In both trials, the mean age of patients was > 80 years and a significant proportion were considered to be frail. As such, external generalisability may be limited when encompassing younger cohorts. In view of this, and the fact that valve durability beyond five years remains largely untested, guidelines continue to favour AVR in patients aged < 75 years.¹⁷

In the moment when this procedure was performed the only existent evidence was the PARTNER II trial and the decision was made by a Heart Team consensus because of the intermediate surgical risk (STS-PROM 4.8%) without any other risk factor and without Cardiac CT contraindication. An Edwards Sapien XT #26 (Edwards Lifesciences, Irvine California) valve was implanted with optimal clinical and echocardiographic outcomes after two-year follow-up.

As in our case, consistent postoperative management strategy is essential. Early discharge (within 24-72 hours) after TAVI is not associated with an increased risk of rehospitalization or sudden cardiac death^{18,19} suggesting that 24-hour continuous electrocardiographic monitoring (instead of 72 hours as recommended in European Society of Cardiology guidelines) may be sufficient

in patients with no conduction abnormalities immediately following the procedure.²⁰

Finally, early mobilization after the procedure promotes rapid return to baseline status, minimizes nosocomial complications, and decreases length of stay in the frail elderly. Early discharge after TAVI, therefore, seems to be a reasonable option in patients who do not experience procedure-related complications.

CONCLUSIONS

Transcatheter aortic valve implantation has established as an effective interventional strategy for severe AS in those patients with high-surgical risk. A combination of increased procedural familiarity and progression in device technology has enabled improvements in complication rates, morbidity and mortality. This has led to a commensurate expansion in the use of TAVI, including in patients at intermediate surgical risk or even low risk. A lack of conclusive evidence relating to this issue can present challenges in the decision-making process. Ongoing and upcoming large-scale clinical trials are anticipated to provide more definitive evidence, and may herald the emergence of a new era in the field of TAVI in Mexico.

Acknowledgements

To the clinical services of Cardiology and Interventional Cardiology of the National Medical Center «20 de Noviembre» for their support, as well as the facilities provided by the institution to carry out this work.

Conflict of interest statement: none declared.

Ethical approval: no ethical approval is required. All identifiable patient information has been removed from this manuscript.

Consent: written informed consent was obtained from the patient for publication of this case report and any accompanying images.

REFERENCES

1. lung B, Cachier A, Baron G, Messika-Zeitoun D, Delahaye F, Tornos P et al. Decision-making in elderly patients with severe aortic stenosis: why are so many denied surgery? *Eur Heart J*. 2005; 26 (24): 2714-2720.
2. lung B, Baron G, Butchart EG, Delahaye F, Gohlke-Bärwolf C, Levang OW et al. A prospective survey of patients with valvular heart disease in Europe: The Euro Heart Survey on Valvular Heart Disease. *Eur Heart J*. 2003; 24 (13): 1231-1243.
3. Cribier A, Eltchaninoff H, Bash A, Borenstein N, Tron C, Bauer F et al. Percutaneous transcatheter implantation of an aortic valve prosthesis for calcific aortic stenosis: first human case description. *Circulation*. 2002; 106 (24): 3006-3008.
4. Jansen F, Werner N. Interventional treatment of the aortic valve : Current evidence. *Herz*. 2017; 42 (6): 548-553.
5. Rodés-Cabau J, Webb JG, Cheung A, Ye J, Dumont E, Feindel CM et al. Transcatheter aortic valve implantation for the treatment of severe symptomatic aortic stenosis in patients at very high or prohibitive surgical risk: acute and late outcomes of the multicenter Canadian experience. *J Am Coll Cardiol*. 2010; 55 (11): 1080-1090.
6. Tamburino C, Capodanno D, Ramondo A, Petronio AS, Ettori F, Santoro G et al. Incidence and predictors of early and late mortality after transcatheter aortic valve implantation in 663 patients with severe aortic stenosis. *Circulation*. 2011; 123 (3): 299-308.
7. Thomas M, Schymik G, Walther T, Himbert D, Lefèvre T, Treede H et al. Thirty-day results of the SAPIEN aortic Bioprosthesis European Outcome (SOURCE) Registry: A European registry of transcatheter aortic valve implantation using the Edwards SAPIEN valve. *Circulation*. 2010; 122 (1): 62-69.
8. Piazza N, Grube E, Gerckens U, den Heijer P, Linke A, Luha O et al. Procedural and 30-day outcomes following transcatheter aortic valve implantation using the third generation (18 Fr) corevalve revalving system: results from the multicentre, expanded evaluation registry 1-year following CE mark approval. *EuroIntervention*. 2008; 4 (2): 242-249.
9. Leon MB, Smith CR, Mack M, Miller DC, Moses JW, Svensson LG et al. Transcatheter aortic-valve implantation for aortic stenosis in patients who cannot undergo surgery. *N Engl J Med*. 2010; 363 (17): 1597-1607.
10. Smith CR, Leon MB, Mack MJ, Miller DC, Moses JW, Svensson LG et al. Transcatheter versus surgical aortic-valve replacement in high-risk patients. *N Engl J Med*. 2011; 364 (23): 2187-2198.
11. Leon MB, Smith CR, Mack MJ, Makkar RR, Svensson LG, Kodali SK, Thourani VH et al. Transcatheter or surgical aortic-valve replacement in intermediate-risk patients. *N Engl J Med*. 2016; 374 (17): 1609-1620.
12. Reardon MJ, Van Mieghem NM, Popma JJ, Kleiman NS, Søndergaard L, Mumtaz M et al. Surgical or transcatheter aortic-valve replacement in intermediate-risk patients. *N Engl J Med*. 2017; 376 (14): 1321-1331.
13. Thourani VH, Kodali S, Makkar RR, Herrmann HC, Williams M, Babaliaros V et al. Transcatheter aortic valve replacement versus surgical valve replacement in intermediate-risk patients: a propensity score analysis. *Lancet*. 2016; 387 (10034): 2218-2225.
14. Baumgartner H, Falk V, Bax JJ, De Bonis M, Hamm C, Holm PJ et al. 2017 ESC/EACTS Guidelines for the management of valvular heart disease. *Eur Heart J*. 2017; 38 (36): 2739-2791.

15. Nishimura RA, Otto CM, Bonow RO, Carabello BA, Erwin JP 3rd, Fleisher LA et al. 2017 AHA/ACC Focused Update of the 2014 AHA/ACC Guideline for the Management of Patients With Valvular Heart Disease: A Report of the American College of Cardiology/American Heart Association Task Force on Clinical Practice Guidelines. *J Am Coll Cardiol*. 2017; 70 (2): 252-289.
16. Auffret V, Lefevre T, Van Belle E, Eltchaninoff H, Iung B, Koning R et al. Temporal Trends in Transcatheter Aortic Valve Replacement in France: FRANCE 2 to FRANCE TAVI. *J Am Coll Cardiol*. 2017; 70 (1): 42-55.
17. Ali N, Patel PA, Lindsay SJ. Recent developments and controversies in transcatheter aortic valve implantation. *Eur J Heart Fail*. 2018; 20 (4): 642-650.
18. Barbanti M, Capranzano P, Ohno Y, Attizzani GF, Gulino S, Immè S, Cannata S et al. Early discharge after transfemoral transcatheter aortic valve implantation. *Heart*. 2015; 101 (18): 1485-1490.
19. Urena M, Hayek S, Cheema AN, Serra V, Amat-Santos IJ, Nombela-Franco L et al. Arrhythmia burden in elderly patients with severe aortic stenosis as determined by continuous electrocardiographic recording: toward a better understanding of arrhythmic events after transcatheter aortic valve replacement. *Circulation*. 2015; 131 (5): 469-477.
20. Barbanti M, Gulino S, Costa G, Tamburino C. Pathophysiology, incidence and predictors of conduction disturbances during Transcatheter Aortic Valve Implantation. *Expert Rev Med Devices*. 2017; 14 (2): 135-147.

Correspondence to:

Dr. Héctor Hugo Escutia Cuevas
División de Cardiología. Centro Médico
Nacional «20 de Noviembre». ISSSTE.
Av. Coyoacán Núm. 1617,
Col. Del Valle Sur, 03100,
Del. Benito Juárez,
Ciudad de México. México.
Celular: 55 39386401
E-mail: perseoyarista@hotmail.com