

Vol. 30 No. 2  
April-June 2019

# Sinus of Valsalva aneurysm that fistulizes into the right atrium

*Aneurisma del seno de Valsalva que fistuliza en la aurícula derecha*

María Fernanda Rabascall Cobos,\* Ernesto Peñaherrera\*\*

**Keywords:**

Valsalva sinus aneurysm, cardiac insufficiency, cardiovascular diagnostic techniques, echocardiography.

**Palabras clave:***Aneurisma del seno de Valsalva, insuficiencia cardiaca, técnicas de diagnóstico cardiovascular, ecocardiografía.***ABSTRACT**

The Valsalva sinus aneurysm is a rare entity in the general population, with an incidence between 0.14 and 3.5% in open-heart surgeries, with a wide clinical spectrum and both electrical and mechanical complications. We present the case of a patient with an aneurysm of the right sinus of Valsalva that fistulized to the right atrium and was complicated with heart failure. The echocardiographic images that were useful to establish the diagnosis and the therapeutic measures are shown, as well as a review of the topic.

**RESUMEN**

*El aneurisma del seno de Valsalva es una entidad rara en la población general, con una incidencia entre 0.14 y 3.5% en cirugías de corazón abierto, con un amplio espectro clínico y complicaciones tanto eléctricas como mecánicas. Se presenta el caso de un paciente con aneurisma del seno de Valsalva derecho fistulizado hacia aurícula derecha complicado con insuficiencia cardiaca. Se muestran las imágenes ecocardiográficas que fueron útiles para establecer el diagnóstico y las medidas terapéuticas, además de una revisión del tema.*

**INTRODUCTION**

The Valsalva aneurysm was described in 1839<sup>1,2</sup> all presented in Valsalva sinuses of the aortic valve and not in the pulmonary artery. It is a rare entity, with an incidence between 0.14 and 3.5% in open heart surgeries.<sup>1</sup>

They are dilatations of the sinus due to a weakness of the middle layer of the aortic wall.<sup>3</sup> This fragility of the aortic wall is explained due to a defective union of the exit tract, valvular ring and anterior wall of the aorta.<sup>4</sup> They may be congenital or acquired. Those of acquired type are due to degenerative, infectious, traumatic causes, connective tissue diseases such as Marfan syndrome or Ehlers-Danlos syndrome, although in these pathologies rupture is extremely rare.<sup>5</sup> These aneurysms progressively dilate until they rupture towards the 4 cavities of the heart,<sup>6</sup> less frequently they break into the pulmonary artery, pericardium, vena cava, pleural cavity. They are associated with other congenital anomalies such as the interatrial or interventricular

septum defect, bicuspid aortic valve, aortic insufficiency, coarctation of the aorta, patent ductus arteriosus, quadricuspid pulmonary valve, pulmonary stenosis, anomalies of the origin of the coronary arteries.

The factors that contribute to the formation and rupture of the Valsalva sinus aneurysms are: low implantation of the valvular annulus, defective development of the conal septum or of the endocardial bearings of the aortic and pulmonary valves and the high pressure of the aorta.

Clinical spectrum is very wide. We can find asymptomatic patients in the case that the aneurysm is intact and the Valsalva sinus aneurysm is an incidental diagnosis, or symptomatic patients with mechanical complications such as fistulized Valsalva sinus aneurysm, heart failure, infectious endocarditis, open rupture to pericardium, acute myocardial infarction and electrical complications such as complete atrioventricular block, these last three causes can lead to sudden death.<sup>1,2</sup>

We report a case of a patient with a right sinus of Valsalva aneurysm that fistulized to

\* Médica Cardióloga con Subespecialidad en Ecocardiografía y Ecoestrés. Departamento de Ecocardiografía.  
\*\* Jefe del Servicio de Cardiología.

Hospital Luis Vernaza.

Received:  
17/01/2019

Accepted:  
11/04/2019

the right atrium with surgical repair being the treatment of choice.

The clinical history of our patient that denies data such as cardiac surgery, fever or sudden episode of chest pain inclines us to think that it is a problem acquired with a gradual and progressive perforation with surgical repair being the treatment of choice.

### CLINICAL CASE

We present the case of a 44-year-old male patient, resident in Manta-Ecuador, tobacco user, without past cardiovascular diseases. Past medical history: hepatic cirrhosis diagnosed 8 years ago without treatment and non-dialytic chronic renal failure (6 months). He entered our institution due to a history of 6 months characterized by dyspnea of medium to minimal efforts, ascites, oedema in the lower extremities and palpitations. He had symptomatic right heart failure due to dyspnea, ascites and oedema in the lower extremities. Blood pressure at admission was 90/60 mmHg, tachyarrhythmic, with a heart rate of 100 beats per minute, and a respiratory rate of 24 breaths per minute.

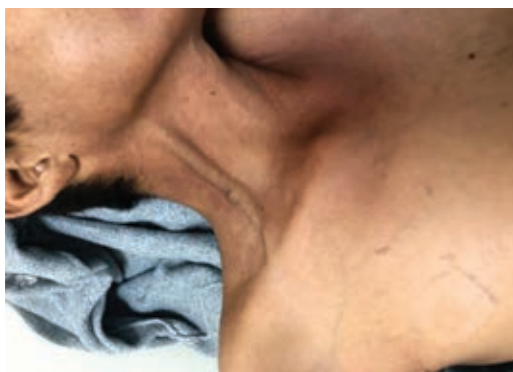

Figure 1: Jugular Ingurgitation III/III.

Physical examination revealed elevated jugular venous pressure, jugular vein III/III (Figure 1), bilateral rales, continuous pansystolic murmur in the base and mesocardium, painful hepatomegaly, hepatojugular reflux, ascites, and oedema in the lower extremities 5/6. A chest X-ray was performed that showed an increase in cardiac silhouette at the expense of right cavities. Hemogram, anemia, impaired renal, hepatic and ionogram function, natriuretic peptide and elevated C-reactive protein. An electrocardiogram was performed showing atrial fibrillation of moderate ventricular response, hypertrophy of the right ventricle with disorders of ventricular repolarization (Figure 2). A transthoracic echocardiogram showed a left ventricle with increased ventricular volumes, with moderate systolic dysfunction, a dilated and hypokinetic right ventricle with a TAPSE of 12 mm and a tissue S wave of 4 cm, flattening of the interventricular septum (SIV), overload to right ventricle due to left-to-right shunt with a pulmonary artery systolic pressure

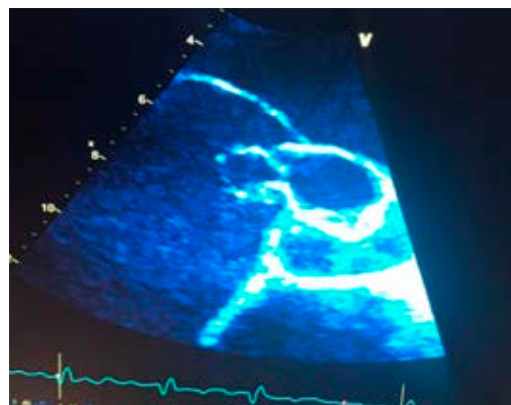


Figure 3: Color Doppler echocardiogram: Short axis: Valsalva sinus aneurysm that communicates with the right atrium.

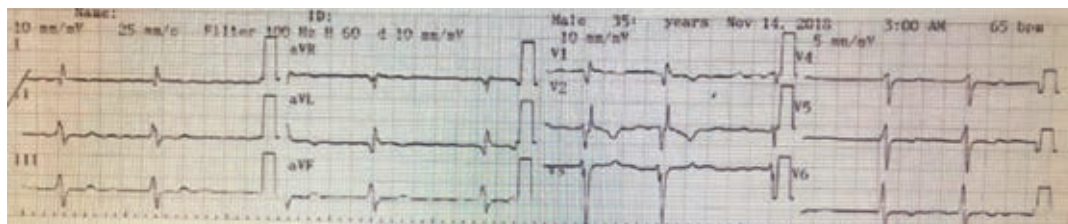


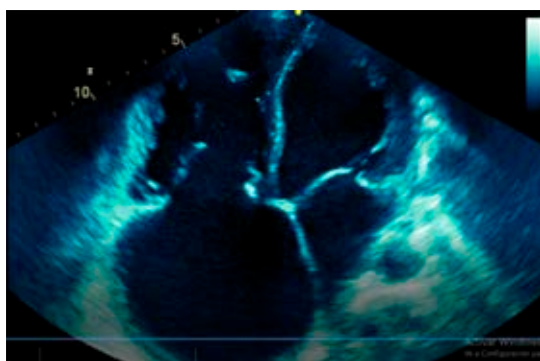
Figure 2: EKG: Atrial fibrillation of moderate ventricular response (FAMRV).

(PSAP) of 48mmHg, acceleration time (TAC) 65 m. In the short axis at the level of the great vessels an annular, very well defined image was observed floating inside the right atrium (AD) (Figures 3 and 4). With the transesophageal echocardiogram a right sinus of Valsalva aneurysm that fistulized to the right atrium (Sakakibara type IIIa classification) was observed. With color Doppler and continuous Doppler it was observed a continuous, turbulent, high-velocity flow between the fistulized aneurysm and right atrium (Figure 5) with a gradient of 60 mmHg. This flow begins in the systole and extends until the diastole, differentiating itself from the tricuspid regurgitation flow. Left and right cardiac catheterization was performed observing normal coronary arteries and without significant lesions, passage of contrast from the aorta to the right atrium through what looks

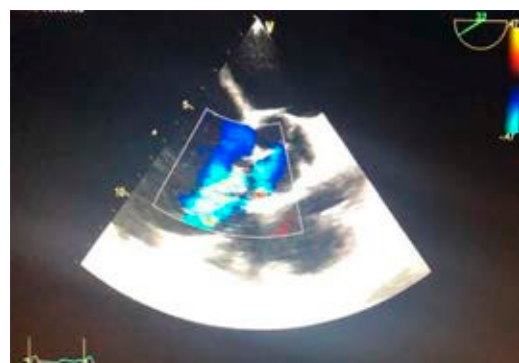
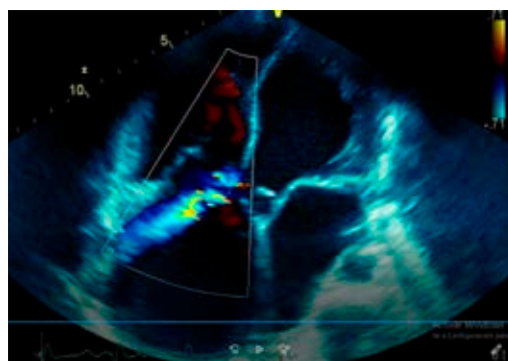
like a fistula between the right Valsalva sinus and the right atrium (Figure 6), with a broad trajectory of about 6-8 mm, severely dilated right atrium, increased right cavity pressures, right atrial pressure (DBP): 25 mmHg, right ventricular pressure (PVD): 49/0-6, moderate pulmonary hypertension PSAP 52/30, PAMP 40, pulmonary vascular resistance (PVR): 82 dynes, systemic vascular resistance (SVR): 648 dynes, pulmonary vascular resistances are slightly increased, with a cardiac output (CO) of 6.7 L/min/m<sup>2</sup> and a cardiac index (CI): 4.7 L/min/m<sup>2</sup>, increased by the great hyperflow caused by the left-right fistula.

### Treatment

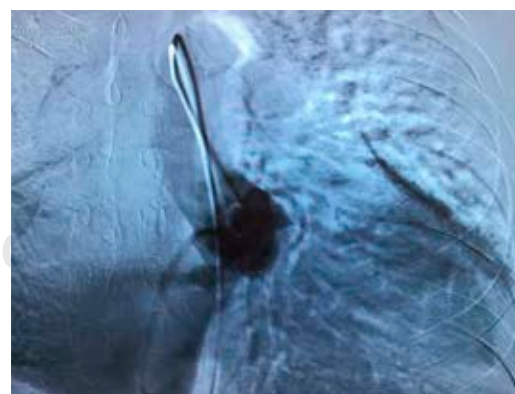Pharmacological treatment was initiated with diuretics such as intravenous furosemide and



**Figure 4:** Color Doppler echocardiogram: Apical 4 chambers: Dilation of right cavities. With color Doppler, a communication is observed between the ruptured right Valsalva sinus aneurysm and the right atrium.



**Figure 5:** Ecotransesophageal: Short axis. With color Doppler, a communication is observed between the ruptured right Valsalva sinus aneurysm and the right atrium.



**Figure 6:** Catheter: Contrast step from the sinus of Valsalva right fistulized towards the right atrium.

water restriction to achieve a negative balance and inotropic drugs such as dobutamine to maintain anterograde perfusion. This case is presented to the medical-surgical staff and they decided to perform surgery to repair Valsalva's right sinus. The patient underwent surgery, during the procedure right aortoatrial fistula was observed from the right aortic sinus infra ostial coronary. A fistulamarsupialization was performed with right atriotomy, fistula closure, atriography, aortorrhaphy, electrical and pharmacological cardioversion due to ventricular fibrillation and transient pacemaker due to extreme bradycardia secondary to the pharmacological effect of amiodarone. A transthoracic control echocardiogram was performed, which revealed the absence of residual or new aortoatrial fistula. The patient responds favorably being discharged and control by external consultation.

### DISCUSSION

Valsalva sinus aneurysms can develop in any of the 3 sinuses, being the most frequent in the right one (67.5-93.4%), then the non-coronary (25-29%) and the last place the left (1-8%).<sup>7</sup> Aneurysms of the right sinus rupture more frequently to the right ventricle (60%), right atrium (29%), left atrium (6%), left ventricle (4%) or pericardium (1%).<sup>8</sup>

It is known to be five times more frequent in Asian countries than in Western countries.<sup>9</sup> The male gender is the most affected with 65% to 80% of cases and a male / female ratio of 4: 1.<sup>10</sup>

According to the study group of De Baakey et al., the anomalies of the sinus of Valsalva can be classified into three groups:<sup>11</sup>

1. Aneurysm of the sinus.
2. Aneurysm with fistula.
3. Fistula.

In our case, the presence of an aneurysm with a fistula was documented to the right atrium, belonging to group 2.

The diagnosis can be made by color-Doppler echocardiography and transesophageal echocardiogram. Those studies give sufficient information to make the diagnosis.<sup>12</sup> It is also necessary to perform the catheterization

because they have other cardiac anomalies. In our case, the transthoracic echocardiogram allowed us to observe the rupture of the sinus of Valsalva in the first instance, so it was necessary to complete the approach with a transesophageal echocardiogram and aortogram.

If there is a rupture, the supraventricular arrhythmias can be found on the electrocardiogram, especially atrial fibrillation, electrical axis displaced to the right, right ventricular hypertrophy. When aneurysm occurs without rupture, the electrocardiogram is usually normal unless the atrioventricular node or any of its branches is compressed, and we can find complete atrioventricular block or other atrioventricular conduction abnormalities.<sup>13</sup> In the case of our patient, we found by electrocardiogram, atrial fibrillation rhythm, right ventricular hypertrophy data and ventricular repolarization disorders.

The natural evolution of the aneurysm may be rupture to a cavity, usually right, causing a left-to-right shunt. The physiopathological and clinical consequences will depend on how fast the rupture occurs, the magnitude of the shunt and the receiving cavity. When the rupture occurs abruptly and the shunt is important, it generates rapid onset of pulmonary congestion, severe and progressive heart failure,<sup>12</sup> of poor prognosis if left to its evolution. If the rupture is slow and the shunt is small, it can go unnoticed for a long time, with bacterial endocarditis being the complication of greatest risk in this phase. When a ruptured or intact aneurysm penetrates the base of the interventricular septum, a complete heart block occurs and causes syncope or death.

Our patient presented signs of hemodynamic overload of the right cavities from a clinical, electrocardiographic and echocardiographic point of view.

In 1962, Sakakibara and Konno established the classification of the Valsalva aneurysms, which is still valid. They classified them into 4 types according to the coronary sinus affected and the area where they fistulized, with 3 subdivisions being type III (Table 1).<sup>13</sup>

The case corresponds to a Valsalva type IIIa aneurysm of this classification



Table 1: Classification of sinus aneurysms of Valsalva.<sup>13</sup>

Type I: Connects the right SV and the RV exit tract below the pulmonary valve
Type II: Connects the right SV and RV in the supraventricular crista
Type III a: Connects the right SV and the AD
Type III v: Connects the posterior area of the right SV and the RV
Type III a + v: Connect the right SV and both, AD and VD
Type IV: Connects the non-coronary SV and the right atrium

SV = Sinus of Valsalva, AD = Right atrium, VD = Right ventricle.

The absolute indications for surgery in unruptured aneurysms are obstruction of the outflow of the right ventricle, infection, arrhythmias or obstruction of a coronary artery.<sup>14</sup> The closure of the fistula is recommended even in asymptomatic patient, due to relatively few complications related to the procedure and the risk of complications such as heart failure, bacterial endocarditis, pulmonary vascular disease, formation of other aneurysms and spontaneous rupture, are greater if such surgery is not performed.<sup>14</sup>

In addition, repair surgery entails immediate results and reduces the risk of the aforementioned complications, improving the life expectative of patients.<sup>15</sup>

Open surgery is the most used technique, although there are successful reports of percutaneous closure.<sup>16</sup> Surgical correction is usually simple, and it can be done almost always through an aortic approach, with a mortality lower than 1% and with a survival at 5 and 10 years of 97 and 90%, respectively.<sup>15</sup> It has been suggested that perioperative mortality increases from 4 to 5 times in cases of infection or endocarditis.<sup>10,17</sup> Special mention is made of patients with large fistulas in whom the function of the aortic valve has been compromised or fistulas that are located near the coronary ostium which the procedure is more difficult, since coronary or valvular surgery techniques should be associated.

Recurrence of a fistula, after corrective surgery, is rare, reporting around 3% according to the series of Van JA and collaborators.<sup>18</sup>

## CONCLUSION

The present case allows us to observe the clinical evolution and the importance of an

early diagnosis in a patient with aneurysm of the right sinus that is perforated to the right atrium presenting heart failure and intense continuous heart murmur.

The final diagnosis is heart failure due to overload of the right atrium secondary a left to right shunt. The transthoracic and the transesophageal echocardiograms are decisive in the diagnosis. The treatment for Valsalva sinus aneurysms that fistulize to another receiving chamber is surgical correction because it has excellent results and low mortality.

## BIBLIOGRAPHY

- Alva C, Vásquez C. Congenital aneurysm of the sinus of Valsalva. *Revisión Rev Mex Cardiol*. 2010; 21: 104-110.
- Serrano EA, Basso GH, Flórez CE, Como JH. surgery of the sinus of Valsalva. *Rev Fed Arg Cardiol*. 2007; 36: 40-41.
- Edwards JE, Burchell HB. The pathological anatomy of deficiencies between the aortic root and the heart including aortic sinus aneurysm. *Thorax*. 1957; 12: 125.
- Sakakibara S, Konno S. Congenital aneurysm of the sinus of Valsalva. *Am J Cardiol*. 1963; 12: 100.
- Guo DW, Cheng TO, Lin ML, GUZQ. Aneurysm of the Sinus of Valsalva: A roentgenology study of 165 Chinese patients. *Am Heart J*. 1987; 114: 1169-1177.
- Munk MD, Gatzoulis MA, King DE, Webb GD. Cardiac tamponade and death from intrapericardial of sinus of Valsalva aneurysm. *Eur J Cardio Thorac Surg* 1999; 15: 100-102.
- Chu SH, Hung CR, How SS, Chang H, Wang SS, Tsai CH. Ruptured aneurysms of the sinus of Valsalva in Oriental patients. *J Thorac Cardiovasc Surg*. 1990; 99: 288-298.
- Galicia-Tornell MM, Marín-Solís B, Mercado-Astorga O, Espinoza-Anguiano S, Martínez-Martínez M, Villalpando-Mendoza E. Aneurysm of the Sinus of Valsalva. Case report and literature review. *Cirug*. 2009; 77: 473-477.
- Abbott M. Clinical and developmental study of a case with ruptured aneurysm of the right anterior aortic sinus of Valsalva: Contributions to medical and biological research, Vol 2. New York. Hoeber 1919; 899.
- Kanzaki Y, Terasaki F, Fuji S, Kashiya T, Kaibe S, Doi Y. A sinus of Valsalva-right atrium fistula without aneurysm formation. *Inter Med*. 2010; 49: 749-751.
- Sakakibara S, Konno S. Congenital aneurysm of the sinus of Valsalva. Anatomy and classification. *Am Heart J* 1962; 3: 405-422.
- Baur LH, Vliegen HW, Van der Wall EE, Hazckamp M, et al. Imaging of an aneurysm of the sinus of Valsalva with transesophageal echocardiography, contrast angiography and MRI. *Intern J Cardiac Imag* 2000; 16: 34-41.
- Gorocito M, Accerboni G, Cabales A y col. Endocarditis infecciosa asociada con ruptura de un aneurisma del seno de Valsalva. *Rev Argent Cardiol* 2002; 70: 211-213.

14. Takach TJ, Reul GJ, Duncan JM. Sinus of Valsalva aneurysm or fistula: management and outcome. *Ann Thorac Surg.* 1999; 68 (5): 1573-1577.
15. Ibrahim KS, Waqfi NR, Jarrah MI. Sinus of Valsalva aneurysm with fistula to the right atrium presented as acute heart failure in a young man. *Am J Case Rep.* 2013; 14: 398-400.
16. Zhao SH, Yan CW, Zhu XY, Li JJ, Xu NX, Jiang SL. Transcatheter occlusion of the ruptured sinus of Valsalva aneurysm with an Amplatzer duct occluder. *Int J Cardiol.* 2003; 129 (1): 81-85.
17. Ott DA. Aneurysm of the sinus of Valsalva. *Semin Thorac Cardiovasc Surg Pediatr Card Surg Ann.* 2006; 165-176.
18. Van Son JA, Danielson GK, Schaff HV, Orszulak TA, Edwards WD, Seward JB. Long-term outcome of surgical repair of ruptured sinus of Valsalva aneurysm. *Circulation.* 1994; 90: 20-29.

**Correspondence to:**

**MF Rabascall Cobos**

Loja 700 y Escobedo. Guayaquil, Ecuador.

**E-mail:** mfrabascall@gmail.com

[www.medigraphic.org.mx](http://www.medigraphic.org.mx)