



Distal transradial access for coronary angiography and percutaneous coronary intervention: an observational study in a Latin-American center

Acceso transradial distal para la angiografía coronaria y la intervención coronaria percutánea: un estudio observacional en un centro latinoamericano

Héctor Hugo Escutia-Cuevas,* Marco Antonio Alcántara-Meléndez,*
Jorge Torres-Sánchez,* Roberto Muratalla-González,* Arnoldo Santos Jiménez-Valverde,*
Gregorio Zaragoza-Rodríguez,* Antonio Vargas-Cruz*

Keywords:

Distal transradial access, coronary angiography, percutaneous coronary intervention.

Palabras clave:

Acceso transradial distal, angiografía coronaria, intervención coronaria percutánea.

* Department of Interventional Cardiology, National Medical Center November 20. Mexico City, Mexico.

Received:
16/12/2019
Accepted:
08/04/2020

ABSTRACT

Introduction: The distal radial technique which consists of canalizing the radial artery through the anatomical snuffbox has recently emerged as an alternative arterial access for diagnostic and therapeutic coronary catheterization. This study aimed to evaluate the feasibility and safety of the distal transradial approach (dTRA) as a default route for coronary angiography (CAG) and percutaneous coronary intervention (PCI) in a Latin-American center. **Material and methods:** Between November 2017 and December 2018, 100 consecutive patients were enrolled in this single-center observational study. The distal radial artery was punctured with a 20, 21 or 22-gauge puncture needle, using a transfixion or anterior wall technique by four expert radial approach operators, 32% of the procedures were PCI. **Results:** The arterial crossover was presented in 19% of patients. The median puncture time and fluoroscopic time were 6.36 minutes and 16 minutes, respectively. Haemostasis median time was 180 minutes. A total of 12 puncture site complications occurred, including 11 minor hematomas and one major hematoma. No distal radial artery occlusion, perforation, pseudoaneurysm, or arteriovenous fistula occurred. **Conclusions:** Even the crossover and complications in our center dTRA is feasible and safe. In a near future this procedure could be a default route for elective CAG and interventions. Large randomized studies should be performed to support it.

RESUMEN

Introducción: La técnica de acceso transradial distal que consiste en canalizar la arteria radial a través de la tabaquera anatómica, ha surgido recientemente como una vía arterial alternativa para el cateterismo coronario diagnóstico y terapéutico. Este estudio tuvo como objetivo evaluar la viabilidad y seguridad del abordaje transradial distal (ATRD) como un acceso predeterminado para la angiografía coronaria (AC) y la intervención coronaria percutánea (ICP) en un centro latinoamericano. **Material y métodos:** Entre noviembre de 2017 y diciembre de 2018, se inscribieron 100 pacientes consecutivos en este estudio observacional de un solo centro. La arteria radial distal se perforó con una aguja de punción de calibre 20, 21 o 22, utilizando una técnica de transfixión o pared anterior, por cuatro operadores expertos en el abordaje radial, 32% de los procedimientos fueron de ICP. **Resultados:** El crossover arterial se presentó en 19% de los pacientes. El tiempo medio de punción y el tiempo de fluoroscopia fueron 6.36 minutos y 16 minutos, respectivamente. El tiempo medio de hemostasia fue de 180 minutos. Se produjo un total de 12 complicaciones en el sitio de la punción, incluidos 11 hematomas menores y un hematoma mayor. No se produjo oclusión de la arteria radial distal, perforación, pseudoaneurisma o fistula arteriovenosa. **Conclusiones:** El ATRD es factible y seguro pese a las complicaciones observadas y a futuro, quizá sea la técnica electiva en los procedimientos invasivos arteriales electivos. Estudios aleatorizados más amplios se necesitan para respaldar esta técnica.

INTRODUCTION

Conventional transradial intervention is now considered the first intention technique for coronary access.^{1,2} The principal advantages are the increase in safety due to the reduction of major bleeding complications, as well as an increase in the patient's comfort due to the immediate post-procedure mobilization.³

The safety of conventional transradial catheterization is mainly determined by the favourable anatomical relationship between the radial artery and the adjacent structures.^{4,5} No important vein or nerve is located near the artery, which minimizes the chances of damaging these structures.^{6,7} Due to the superficial trajectory of the radial artery, hemostasis can be easily performed with local compression. Due to adequate collateral blood flow from the ulnar artery or the interosseous artery, the hand perfusion is not in risk even an acute radial artery occlusion.^{8,9}

Among the expected complications and limitations for future interventions the most important is the radial artery occlusion, which is estimated to occur in 10% of patients undergoing transradial intervention and it has been considered the «Achilles heel» of transradial intervention for patients who eventually require new coronary procedures due to the complexity of their cardiac disease. This complication is originated in the sheath insertion site due to endothelial damage, blood flow cessation, and secondary thrombosis, and has an early occurrence after transradial catheterization.^{10,11}

The distal radial technique, which consists of canalizing the radial artery through the anatomical structure called snuffbox (anatomical snuffbox, radial fossa, fovea radialis), has recently emerged as an alternative arterial intervention for diagnostic and therapeutic coronary catheterization, allowing the conservation of the radial artery for classical transradial intervention in patients who, according to the complexity of their heart disease, require new coronary interventions.¹²

The radial fossa is a hollow space on the radial side of the wrist that becomes evident when the thumb is extended; it is limited by the extensor pollicis longus tendon of the

thumb, the extensor pollicis brevis and the abductor pollicis longus tendons of the thumb. The radial artery crosses the surface formed by the scaphoid and trapezium (*Figure 1*).¹³ Distal artery access from the radial fossa was first described by Babunashvili and collaborators in 2011 with the aim of permeabilize the ipsilateral radial arteries with retrograde occlusion.¹⁴ If the artery is well developed, this artery can be used as the entry site for 4, 5, 6, 7 or even 8 Fr catheters and sheaths.¹⁵

Another important characteristic of this technique is a proximal puncture of the short artery of the thumb and distally to the branch that irrigates the superficial palmar arch. This is because an occlusion at this site maintains anterograde flow towards the superficial palmar arch. This reduces the risk of development of retrograde thrombus in the proximal radial artery located in the forearm, a frequent finding in patients who develop radial artery occlusion due to traumatic punctures or traumatic hemostasis at the traditional radial puncture site. Flow towards the thumb is maintained by the superficial palmar arch, preventing ischemia and disability of the hand.¹⁶⁻¹⁹

The transradial distal technique intervention has been performed in Mexico since 2017. We

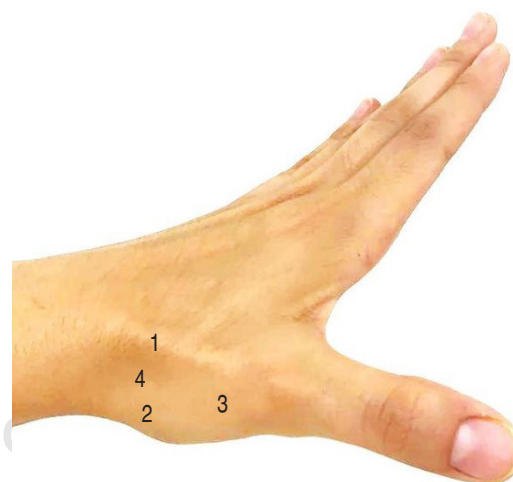


Figure 1: Dorsal view of the radial zone of the left wrist with anatomical references. 1 = extensor pollicis longus muscle tendon of the thumb; 2 = extensor pollicis brevis muscle tendon of the thumb; 3 = head of the first metacarpal; 4 = anatomical snuffbox.

have performed the present registry to describe the characteristics, complications, and benefits of this procedure on a consecutive series of patients in a Latin-American center.

MATERIAL AND METHODS

Study type and design

This is a prospective, observational, single-center study carried out at the National Medical Center November 20 in Mexico City. The protocol was reviewed and authorized by the local Safety, Statistics, and Bioethics Committees (Folio 34.2018) and registered in ClinicalTrials.gov (NCT03948165). Patient selection, procedures, follow-up, and data capturing were performed by the authors.

Prior assessment

Distal transradial access was performed on patients above 18 years of age, undergoing diagnostic and/or therapeutic coronary angiography, with palpable pulse at the level of the radial fossa, and these patients were also subjected to the following tests: Allen maneuver and Barbeau maneuver; a positive Allen test was an indication to perform the transradial access, while a type D Barbeau test was a contraindication for it. Also, all patients with the following conditions were excluded: cardiogenic shock within the previous 48 hours, anticoagulant contraindication, uncontrolled arterial hypertension, peripheral arterial disease, proximal radial artery diameter by duplex ultrasound < 1.8 mm, radial access used within the previous 6 weeks, proximal radial artery occlusion, and refusal of consent.

Preparation and medications

With prior consent signed by the patient and/or responsible person. The puncture site was infiltrated with 2% lidocaine (2-3 mL). 5,000 IU unfractionated heparin was administered intravenously after insertion of the distal radial sheath, and in case of requiring percutaneous coronary intervention, a dose of 80-110 IU/kg/hour was completed. In case of long procedures, activated clotting time (ACT)

control was required, with values between 300-350 seconds. The following vasodilators were used initially as intra-arterial bolus: 200 μ g of nitroglycerin (which was excluded in the case of hypotension) and 250 μ g of levosimendan. After radial sheath removal by patent hemostasis, the heparin infusion was continued in case of evidence of intracoronary thrombus.

Distal radial artery cannulation

In the case of access through the left distal radial artery, the left arm was brought comfortably towards the patient's right side allowing a natural working position for the operator; and if access is through the right distal radial artery, this additional comparative position change was not necessary. Left or right, the hand and wrist were placed in hyperextension, exposing the radial fossa. The distal radial artery was punctured with specialized equipment, with a 20, 21 or 22-gauge puncture needle using a transfixion or anterior wall technique. A 0.025 inch, 46 cm hydrophilic guidewire was introduced in the system, followed by the 5, 6, 7 Fr hydrophilic arterial sheath or 5, 6 or 7 Fr Glidesheath Slender introducer (Terumo IS, Tokyo, Japan), after a small cut in the skin.

For the convenience of the operator, initial access is right distal transradial, in the case of not being able to achieve this access the first alternative was to migrate to a left distal transradial access; the causes associated with this were:

- Right radial artery occlusion.
- Underdeveloped right radial artery.
- Extreme right radial tortuosity.
- Sclerosis or calcifications.
- Lusoria artery.
- Previous failed attempt on right radial artery.
- Presence of arteriovenous short circuit in left arm.
- Previous use or foreseen future use of right radial artery for bypass graft.
- Patients with surgical revascularization who require left internal mammary artery graft angiography.
- Patient preference.
- Right-handed patients due to temporary post-procedure disability caused by the hemostasis process.

Coronary artery cannulation

Specialized 5Fr, 6Fr or 7Fr guide catheters or diagnostic catheters were used with appropriate curve according to the case, in order to provide maximum support during coronary angiography or angioplasty.

Table 1: Clinical characteristics of patients (N = 100).

Age	65.06 ± 24.5
Diabetes mellitus	43
Hypertension	73
Dyslipidemia	45
Prior coronary angioplasty	8
Active smoking	19
Clinical indication	
Stable chronic angina	54
Unstable angina	1
Myocardial infarction	9
Mitral valve disease	12
Aortic valve disease	15
Interatrial septal defect	5
Endocarditis	2
Pulmonary hypertension	2

The qualitative variables were expressed as n (%), while the quantitative variables were expressed as n (± 2 SD).

Table 2: Anatomical characteristics of the distal radial artery (N = 100).

Palpable proximal radial pulse	100
Palpable radial pulse in anatomical snuffbox	100
Allen test (seconds)	2.06 ± 0.5
Barbeau test	
A	88
B	11
C	1
D	0
Pre-procedure duplex ultrasound	
Proximal radial artery diameter (mm)	2.5 ± 0.7
Peak systolic velocity (cm/s)	33 ± 3.2
Peak diastolic velocity (cm/s)	11.45 ± 2.65
Distal radial artery diameter (mm)	2.28 ± 0.7

The qualitative variables were expressed as n (%), while the quantitative variables were expressed as n (± 2 SD).

Sheath removal, patent hemostasis, and hospital discharge

In all cases, the arterial sheath is removed after the removal of the diagnostic or guide catheter. Patent hemostasis is performed obtaining the pulse oximeter oscillatory curve by placing the external pneumatic compression band, adjusting the radial compression system in air millilitres (modified Barbeau maneuver). If there are no complications after the procedure, hospital discharge will be evaluated after 24 hours.

Statistical analysis

Non-probability sampling was performed according to the above-mentioned selection criteria. The descriptive analysis was carried out with measures of central and dispersion tendency according to the normality test. The categorical variables were reported as n (%) and the quantitative variables in interquartile ranges P50 (P25-P75) or as standard deviation (n [± 2 SD]). The Statistics Program SPSS 24.0 for Windows was used.

RESULTS

In the period between November 2017 and December 2018 a total of 100 patients were assigned for distal transradial access. Among the clinical characteristics of the population (Table 1), the following stand out: the mean age was 65 years, with a 43% of diabetes mellitus, 73% hypertension, 45% dyslipidemia, 10% smokers, and 8% prior history of coronary angioplasty. The main indication for coronary angiography was stable chronic angina in 54%, followed by aortic valve disease (15%) and mitral valve disease (12%).

The anatomical characteristic of the radial artery (Table 2) in which the distal and proximal radial pulse were palpable was found in all the patients. The Allen test was positive in every case. The Barbeau test was type A in 88%, type B in 11%, and only one patient was type C.

For service logistics details the radial artery ultrasound was not performed on all the patients, but with a 30% sample an average proximal radial artery diameter of 2.5 ± 0.7

Table 3: Procedure characteristics (N = 100).

Ultrasound-guided puncture	11
Time to obtain the arterial access (seconds)	382 (46-5400)
Obtained access	
R-dTRA	74
L-dTRA	26
Arterial sheath	
5 Fr	9
6 Fr	39
Glidesheath Slender 6 Fr	40
Glidesheath Slender 7 Fr	12
Hydrophilic	98
Non-hydrophilic	2
Coronary guidewire	
Hydrophilic	76
Non-hydrophilic	24
Intermediate 0.014"	22
Floppy 0.014"	1
Extra support 0.014"	2
Arterial access crossover	19
Ipsilateral radial	6
Contralateral radial	2
Contralateral distal radial	1
Femoral	10
Number of catheters used	1.38 (1-3)
Maximum width used (Fr)	7
Diagnostic procedures	68
Interventional procedures	32
Fluoroscopy time (min)	16 (1-118)
Total radiation (air kerma) (mGy)	1798.12 (250-11989)

The qualitative variables were expressed as n (%), while the quantitative variables were expressed as P50 (P25-P75).

Abbreviations: R-dTRA = right distal radial artery, L-dTRA = left distal radial artery, Fr = French.

mm and an average distal radial artery diameter of 2.28 ± 0.7 mm were obtained, with a 0.22 mm difference. The average peak systolic velocity was 33 ± 3.2 cm/s and the average peak diastolic velocity was 11.45 cm/s.

Ultrasonographic guide was used to perform the distal radial arterial puncture in 11% of the cases, highlighting its use in the first quarter of cases (Table 3). Of the one hundred patients who underwent distal radial access, 74% were on the right hand and 26% on the left hand. In most patients, 6 Fr Slender sheaths (Terumo IS, Tokyo, Japan) were used (40%), followed by 6 Fr sheaths

(39%), 7 Fr Glidesheath Slender (12%), and 5 Fr Glidesheath Slender (9%). A hydrophilic sheath was used in 98% of the cases. The guidewire used to place the distal radial sheath was 0.025" hydrophilic in 76% of patients, and in the rest (24%) predominantly intermediate 0.014" coronary guidewires were used. Once distal transradial access was obtained and successfully cannulated with the arterial sheath, the need for arterial access crossover was presented in up to 19% of patients mainly due to radial artery vasospasm development, and therefore the most common crossover was to femoral artery access (10%) followed by ipsilateral radial artery (6%), contralateral radial artery (2%), and only one case to the contralateral distal radial artery. In most cases a single diagnostic catheter was used (68%), where 7 Fr was the maximum size used. Regarding the performed coronary procedure it was mostly a diagnostic coronary angiography, with only a 10% of coronary angioplasty, including resolution with dual coronary cannulation for chronic total occlusion in four patients and rotational atherectomy in one case. The average fluoroscopy time was 16 minutes mainly due to the complex coronary intervention including the resolution of total chronic coronary occlusions. The pneumatic compression device was the most used (98%) and the average air volume of the pneumatic band was 16.9 mL (Table 4). The total hemostasis time was standardized to 3 hours. Immediately after finishing the procedure the proximal radial arterial pulse was present in 94% of cases. Hematoma occurred in 12% mainly of low grade, ecchymosis occurred in 16% also in low grade. There was pain at the radial puncture site immediately after the procedure in 47 patients, but it was low scale (1 to 3), and it decreased in the following 24 hours in 39%, remaining in low scale (Table 5). Twenty four hours after the procedure, presence of palpable pulse on the intervened distal radial artery was reported in 65% of patients, and in the proximal radial artery in 89% of patients. Hematoma developed after 24 hours of the procedure in 7% of patients, and ecchymosis in 18%, both were of low grade.

DISCUSSION

This single-center, prospective and observational registry presents an experience in a Latin-

American center, as well as it shows the feasibility of coronary intervention by a distal transradial access.

A registry conducted by Jon-Won Lee shows that the procedure is safe and effective in diagnostic and therapeutic coronary catheterization with success rates of 95.5% for arterial puncture, 100% for coronary angiography and 98.9% for coronary angioplasty, with a time to obtain arterial access of 3.0 ± 2.8 minutes.

Complications were considered minor in 7.4%, with hematoma development in 1% and a single case of arterial dissection, observing adequate flow after one month follow-up; no radial artery occlusion, perforation, pseudoaneurysm or arteriovenous fistula were observed.²⁰ This study²⁰ also reports the first experience of a high-concentration centre and the results are comparable to those observed in our series, in which the most frequent

Table 4: Immediate post-procedure variables.

Hemostatic device	
Pneumatic band	98
Compression bandage	2
Air volume (mL) in hemostatic device	16.9 (12-20)
Total radial hemostasis time (min)	180 (160-200)
Complications	
Hematoma	12
Grade I	6
Grade II	3
Grade III	2
Grade IV	1
Grade V	0
Ecchymosis	16
Grade I	6
Grade II	7
Grade III	2
Grade IV	1
Grade V	0
Radial pain	47
Numeric analog scale	1.47 (1-3)

The qualitative variables were expressed as n (%), while the quantitative variables were expressed as P50 (P25-P75).

Table 5: 24-hour post-procedure variables.

Pulse present in distal radial artery	65
Pulse present in proximal radial artery	89
Hematoma	10
Grade I	7
Grade II	2
Grade III	1
Grade IV	0
Grade V	0
Ecchymosis	18
Grade I	11
Grade II	4
Grade III	2
Grade IV	1
Grade V	0
Radial pain	39
Numeric analog scale	1.37 (1-5)

The qualitative variables were expressed as n (%), while the quantitative variables were expressed as P50 (P25-P75).

complication was low grade hematoma in 9% and high grade hematoma in 3%.

Within a one-year period, successful distal radial artery canalization was achieved 100 times. Although in the first cases the vascular ultrasound was used to support the puncture it was only used in the first patients, being part of the learning curve, likewise observing a drastic reduction in the time necessary to achieve a successful vascular access from 9 minutes in the first case to 34 seconds in the latter cases. This effect can be observed also in other series.^{20,21}

The distal radial artery occlusion (RAO) rate was not observed in this study, despite the fact that the diameter of the distal radial artery is smaller than that of the forearm radial artery. Such a low RAO rate may be attributed to the anatomical configuration of the puncture site and due to the time of evaluation. This specific anatomical configuration can naturally limit the vascular compression needed to achieve hemostasis using hemostatic devices.

Further, echo-guided puncture was conducted in 11% of the patients in this study, it was largely applied for patients with small radial size and poor radial pulsation either from the beginning

or after a failed initial attempt. Although the success of puncture is mainly affected by operator expertise, frequent use of sonography may contribute to higher success rate of puncture and consequently may avoid multiple puncture attempts, which lead to a potential risk for RAO due to subsequent hematoma formation and/or radial artery dissection.

The main cause for access crossover was the development of radial artery vasospasm, femoral artery was the second access option and the ipsilateral radial artery was the third option. Although the 6 Fr Glidesheath Slender (Terumo IS, Tokyo, Japan) was the most used radial sheath, 5 and 6 Fr hydrophilic sheaths were also used. Diagnostic coronary procedure was the most performed. However, it was possible to perform complex coronary intervention including chronic total occlusions and rotational atherectomy (1.75 mm olive), procedures that have scarcely been reported through this access.

Neuropathy (numbness in the fingers) was observed in two patients (2%), a rate similar to that reported in a recent study.⁶ Although the advantages of the dTRA in terms of vascular complications are clear, this specific issue should be noted. The branch of the superficial radial nerve is located in the snuffbox and can induce damage to the nerve, which rarely occurs in the forearm radial artery.

The refinement and development of distal transradial access can offer advantages to patients in the outcomes of angiography and coronary intervention, maintaining the convenience for the operator and decreasing the complications associated with the procedure.⁸ Thus, a new possibility is opened up for vascular access which will benefit patients who require repeated arterial access throughout the course of their cardiovascular pathology.

CONCLUSIONS

Although it is a prospective observational study, it can be concluded that distal transradial access is feasible. With experienced operators and the appropriate materials it offers a safe arterial canalization for coronary angiography and percutaneous intervention. A randomized clinical trial must be carried out

to demonstrate its relative safety compared with other arterial accesses.

ACKNOWLEDGMENTS

We are grateful to the clinical services of Cardiology, Coronary Intensive Care Unit and Interventional Cardiology of the National Medical Center November 20 for their support, as well as the facilities provided by the institution to carry out this work.

Funding sources: This research received no grants from any funding agency in the public, commercial, or not-for-profit sectors.

Conflict of interest: The authors declare no conflicts of interest associated with the present study.

REFERENCES

1. Kiemeneij F, Laarman GJ. Percutaneous transradial artery approach for coronary stent implantation. *Cathet Cardiovasc Diagn.* 1993; 30 (2): 173-178.
2. Kiemeneij F, Laarman GJ, Odekerken D, Slagboom T, van der Wieken R. A randomized comparison of percutaneous transluminal coronary angioplasty by the radial, brachial and femoral approaches: the access study. *J Am Coll Cardiol.* 1997; 29 (6): 1269-1275.
3. Agostoni P, Biondi-Zoccai GG, De Benedictis ML, Rigattieri S, Turri M, Anselmi M et al. Radial versus femoral approach for percutaneous coronary diagnostic and interventional procedures: systematic overview and meta-analysis of randomized trials. *J Am Coll Cardiol.* 2004; 44 (2): 349-356.
4. Bedford RF, Wollman H. Complications of percutaneous radial-artery cannulation: an objective prospective study in man. *Anesthesiology.* 1973; 38 (3): 228-236.
5. Campeau L. Percutaneous radial artery approach for coronary angiography. *Cathet Cardiovasc Diagn.* 1989; 16 (1): 3-7.
6. Mizuguchi Y, Izumikawa T, Hashimoto S, Yamada T, Taniguchi N, Nakajima S et al. Efficacy and safety of the distal transradial approach in coronary angiography and percutaneous coronary intervention: a Japanese multicenter experience. *Cardiovasc Interv Ther.* 2020; 35 (2): 162-167. doi: 10.1007/s12928-019-00590-0.
7. Lotan C, Hasin Y, Mosseri M, Rozenman Y, Admon D, Nassar H et al. Transradial approach for coronary angiography and angioplasty. *Am J Cardiol.* 1995; 76 (3): 164-167.
8. Corcos T. Distal radial access for coronary angiography and percutaneous coronary intervention: A state-of-the-art review. *Catheter Cardiovasc Interv.* 2019; 93 (4): 639-644.
9. Valgimigli M, Gagnor A, Calabró P, Frigoli E, Leonardi S, Zaro T et al. Radial versus femoral access in patients with acute coronary syndromes undergoing invasive

- management: a randomised multicentre trial. *Lancet*. 2015; 385 (9986): 2465-2476.
10. Avdikos G, Karatasakis A, Tsoumeleas A, Lazaris E, Ziakas A, Koutouzis M. Radial artery occlusion after transradial coronary catheterization. *Cardiovasc Diagn Ther*. 2017; 7 (3): 305-316.
 11. Aoi S, Htun WW, Freeo S et al. Distal transradial artery access in the anatomical snuffbox for coronary angiography as an alternative access site for faster hemostasis. *Catheter Cardiovasc Interv*. 2019; 94 (5): 651-657.
 12. Hamon M, Pristipino C, Di Mario C, Nolan J, Ludwig J, Tubaro M et al. Consensus document on the radial approach in percutaneous cardiovascular interventions: position paper by the European Association of Percutaneous Cardiovascular Interventions and Working Groups on Acute Cardiac Care and Thrombosis of the European Society of Cardiology. *EuroIntervention*. 2013; 8 (11): 1242-1251.
 13. Jolly SS, Yusuf S, Cairns J, Niemelä K, Xavier D, Widimsky P et al. Radial versus femoral access for coronary angiography and intervention in patients with acute coronary syndromes (RIVAL): a randomised, parallel group, multicentre trial. *Lancet*. 2011; 377 (9775): 1409-1420.
 14. Davies RE, Gilchrist IC. Dorsal (distal) transradial access for coronary angiography and intervention. *Interv Cardiol Clin*. 2019; 8 (2): 111-119.
 15. Shah RM, Patel D, Abbate A, Cowley MJ, Jovin IS. Comparison of transradial coronary procedures via right radial versus left radial artery approach: a metaanalysis. *Catheter Cardiovasc Interv*. 2016; 88 (7): 1027-1033.
 16. Cerda A, Del Sol M. Anatomical snuffbox and its clinical significance. A literature review. *Int J Morphol*. 2015; 33 (4): 1355-1360.
 17. Babunashvili A, Dundua D. Recanalization and reuse of early occluded radial artery within 6 days after previous transradial diagnostic procedure. *Catheter Cardiovasc Interv*. 2011; 77 (4): 530-536.
 18. Kaledin AL, Kochanov IN, Seletski SS, Arkharov IV, Burak T, Kozlov KL. Peculiarities of arterial access in endovascular surgery in elderly patients. *Adv Gerontol*. 2014; 27 (1): 115-119.
 19. McNamara MG, Butler TE, Sanders WE, Pederson WC. Ischaemia of the index finger and thumb secondary to thrombosis of the radial artery in the anatomical snuffbox. *J Hand Surg Br*. 1998; 23 (1): 28-32.
 20. Lee JW, Park SW, Son JW, Ahn SC, Lee SH. Real-world experience of the left distal transradial approach for coronary angiography and percutaneous coronary intervention: a prospective observational study (LeDRA). *EuroIntervention*. 2018; 14 (9): e995-e1003.
 21. Kiemeneij F. Left distal transradial access in the anatomical snuffbox for coronary angiography (ldTRA) and interventions (ldTRI). *EuroIntervention*. 2017; 13: 851-857.

Correspondence to:

Héctor Hugo Escutia-Cuevas

Av. Coyoacán 1617, Interior APH7,
Col. Del Valle Sur, 03104,

Benito Juárez, Mexico City, Mexico.

E-mail: perseoyarista@hotmail.com