

IMAGES IN CARDIAC SURGERY

Degenerative mitral valve disease: Sometimes you can take a rain check!

Ovidio A. García-Villarreal.

Mexican College of Cardiovascular and Thoracic Surgery. Monterrey, Nuevo Leon, MEXICO.

Cir Card Mex 2022; 7(3): 60.

© 2022 by the Sociedad Mexicana de Cirugía Cardíaca, A.C.

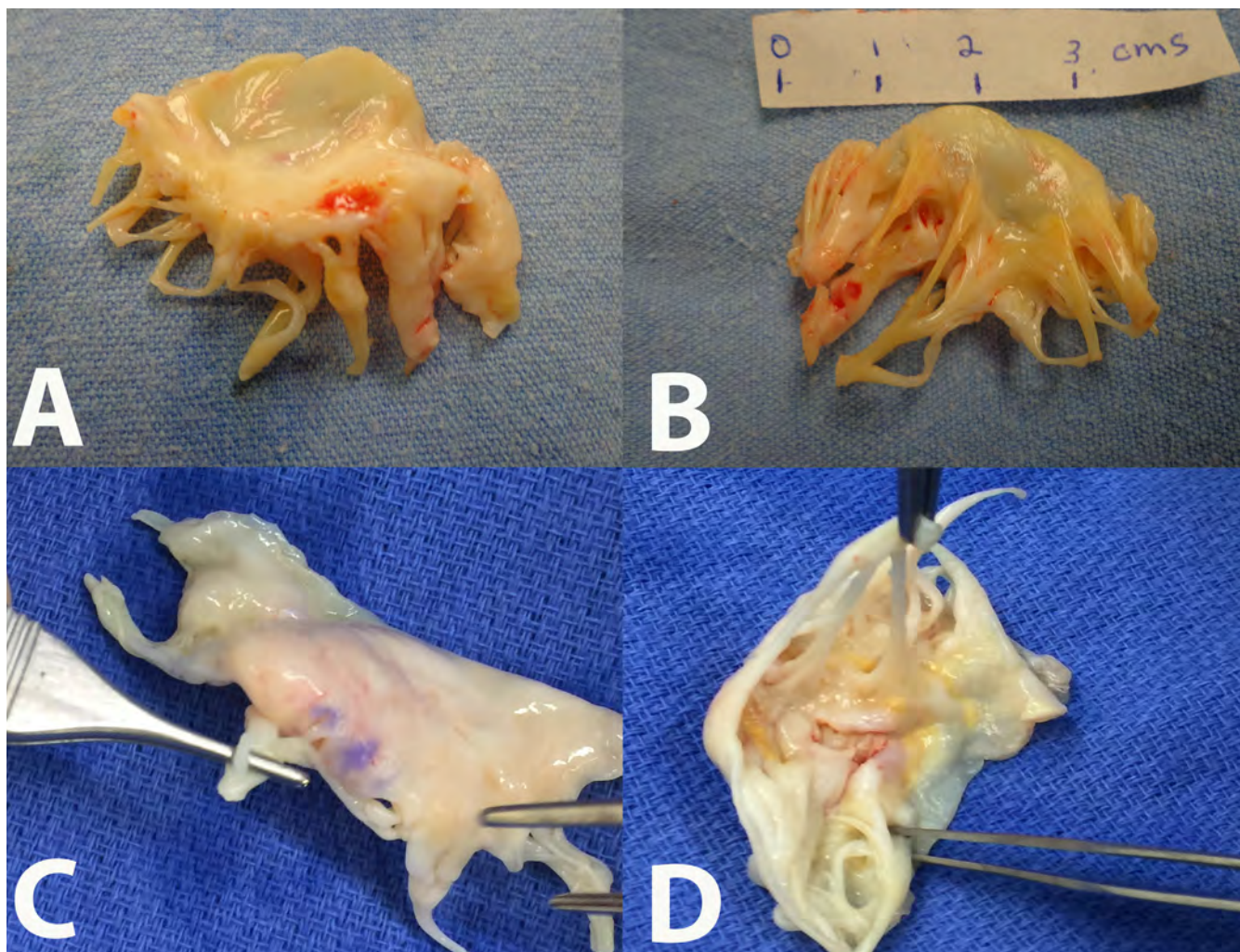


Figure 1. A, B, C, D. All these surgical specimens of the anterior mitral leaflet represent cases of degenerative mitral valve disease. As it can be seen, not always is so easy to take a decision in favor of mitral valve repair. In all cases, some chordal fusion, thickening, even also some calcified areas make the repair very difficult and uncertain.

Corresponding author: Dr. Ovidio A. García-Villarreal
email: ovidiocardiotor@gmail.com