



January-March 2024  
Vol. 2, no. 1 / pp. 54-59

Received: October 12, 2023  
Accepted: October 24, 2023

doi: 10.35366/114913

# Parkinson disease spine instrumentation, a chronicle of a death foretold

## *Instrumentación en enfermedad de Parkinson, crónica de una muerte anunciada*

Fernando José Rodas Montenegro,<sup>\*,‡</sup> César Alan Moreno Villegas,<sup>\*,§</sup>  
Leonel Ramírez Abrego,<sup>\*,¶</sup> Francisco Javier Sánchez García,<sup>\*,||</sup>  
Jorge Alberto De Haro Estrada,<sup>\*,\*\*</sup> Alejandro Tejera Morett,<sup>\*,##</sup>  
Francisco Cruz López,<sup>\*,§§</sup> Hernan Michael Dittmar Johnson<sup>\*,¶¶</sup>

### Keywords:

Parkinson disease surgical  
complication, proximal  
junctional failure, proximal  
junctional kyphosis.

### Palabras clave:

complicaciones quirúrgicas  
en enfermedad de Parkinson,  
cifosis en segmento de  
unión proximal, falla en  
segmento de unión proximal.

### ABSTRACT

A 75-year-old male with a history of medically controlled arterial hypertension (AH) and Parkinson disease (PD), reporting degenerative lumbar scoliosis and lumbar stenosis. Underwent for coronal deformity correction and lumbar stenosis decompression. An immediate successful radiological and clinical outcome, but six weeks after surgical intervention, patient with thoracic pain, X-rays showed a fracture of the upper instrumented vertebra. Due to multimorbidity we decided conservative treatment, expecting consolidation. Nevertheless, after five months of conservative treatment without bone consolidation, he underwent a re-intervention, making a transition from a rigid to a semi-rigid spine instrumentation. The purpose of this article is to show how challenging is a combination of PD with degenerative spine disease.

### RESUMEN

*Paciente masculino con escoliosis lumbar degenerativa acompañado de enfermedad de Parkinson (EP). Se instrumenta únicamente los niveles necesarios para corrección de la deformidad coronal, como descompresión de los niveles con estenosis. A pesar de un control radiológico inmediato satisfactorio, en los días posteriores el paciente se aqueja de dolor a nivel de la columna torácica. Rayos X de seguimiento evidencian fractura de la vértebra más cefálica instrumentada. Debido a múltiples comorbilidades, se decide manejo conservador, esperando consolidación del segmento lesionado. Sin embargo, a pesar del tratamiento médico, es llevado cinco meses postoperatorio a sala de operaciones para prolongación de la instrumentación, realizando una transición de una fijación rígida a una semirrígida. El objetivo de la publicación es poner en contexto acerca de la dificultad que conlleva el manejo de un paciente que padezca EP combinado con algún padecimiento degenerativo de la columna.*

\* Fellowship in Spine Surgery,  
Re-espalda. Hospital Puerta de  
Hierro Andares, Universidad  
Autónoma de Guadalajara  
Zapopan, Jalisco, México.

ORCID:

‡ 0009-0006-3571-6000

§ 0000-0001-5093-319X

¶ 0000-0003-2350-1329

|| 0000-0003-2033-9688

\*\* 0000-0001-9707-1208

## 0000-0003-4214-6254

§§ 0000-0002-7390-6212

¶¶ 0000-0002-8024-7032

### Correspondence:

Fernando José Rodas Montenegro  
E-mail: fjrodmont@gmail.com

**How to cite:** Rodas MFJ, Moreno VCA, Ramírez AL, Sánchez GFJ, De Haro EJA, Tejera MA, et al. Parkinson disease spine instrumentation, a chronicle of a death foretold. *Cir Columna*. 2024; 2 (1): 54-59. <https://dx.doi.org/10.35366/114913>



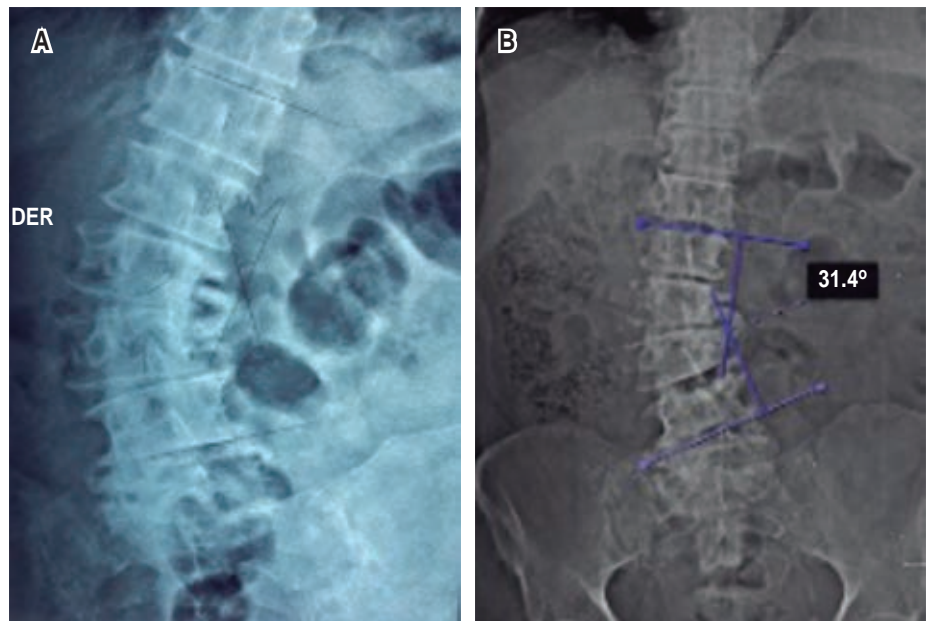
## INTRODUCTION

PD is the second most common neurodegenerative condition, with an estimated prevalence of 0.3%.<sup>1,2</sup> Postural deformities are common in this disease, being two types the most important: 1) sagittal plane (camptocormia and antecollis), and 2) coronal plane (Pisa syndrome and scoliosis). Coronal deformity has a coronal deviation of the trunk, that resolves after being in supine.<sup>3</sup> Those types of deformities could have myelopathy or radiculopathy.<sup>1</sup> Degenerative spondyloarthropathy, thoracolumbar scoliosis and cervical deformity, are the most common degenerative spine problems in PD.<sup>4</sup> Consider that PD patients are susceptible to osteoporosis, due to: 1) low bone mechanic stress due to low mobility, 2) vitamin D deficiency, 3) low body weight, and 4) hyperhomocysteinemia.<sup>5,6</sup> But, which is the appropriate asses of a degenerative spine disease with PD? Do we have to fix it or not? Well, depends on each case. First, analyzed the severity of PD by a modified scale of Hoehn and Yahr,<sup>7,8</sup> and then determined the best option.

## CASE PRESENTATION

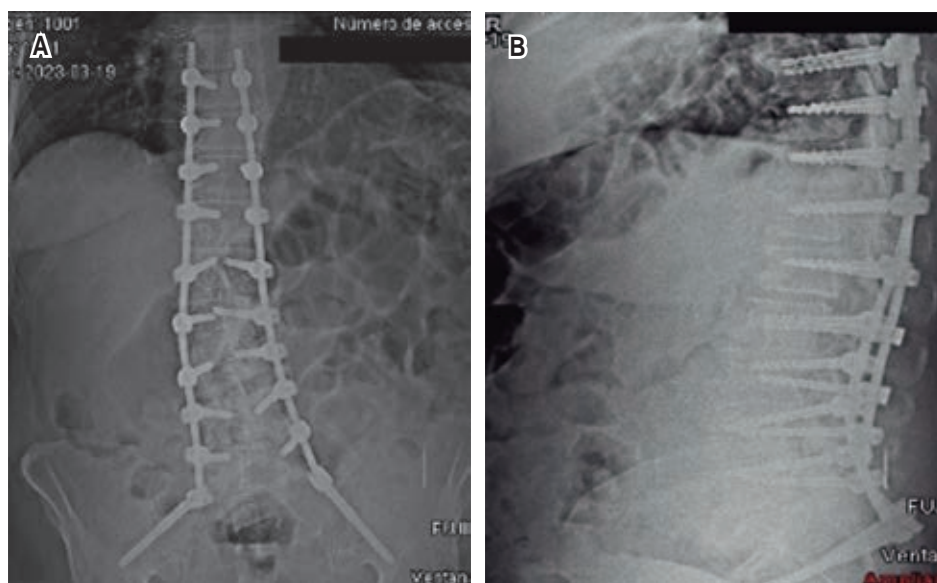
A 75-year-old male with a history of medically controlled AH and PD, with low-back-pain radiating to both limbs, predominantly to the left. Tendency to a positive balance gait and left coronal deviation.

X-rays showed a degenerative lumbar scoliosis with 40° of Cobb angle (*Figure 1*). Underwent a posterior spine fusion from T9 to iliac bones, plus lumbar stenosis decompression. Postoperative X-rays and clinical evaluation were successful (*Figure 2*). After six weeks, he was in great pain localized in thoracic spine due to movement, and X-ray control showed a fracture of the upper instrumented vertebra (UIV) with regional kyphosis angle (RKA) of 30.6° (*Figure 3*). Due to multimorbidity, treatment choice was conservative with analgesic medication and Taylor Brace. After three months, still with thoracic pain. Supine X-ray with RKA of 23.2°, and standing X-ray RKA of 46.3° (*Figure 4*); patient did not agree for a revision surgery, so we continued with conservative treatment. Four months after surgery was performed a computed tomography (CT), with a 75% lysis of T9 and inferior platform of T8 affected (*Figure 5*). After five months from the first surgery, patient accepted a revision surgery. Extension of instrumentation was performed by the following way: removed of T9 screws, transpedicular screws were placed in T7, T6 and T5; transverse process hooks were used in T4 and T3. Due to a bone cavity, a vertebroplasty was performed in T9 for anterior stability. The length of the previous rod was extended, using an end-to-end connector to the most cephalad segment where transpedicular screws were placed, and a reinforcement rod to the vertebroplasty using a side-to-side connector between T9 to T3 (*Figure 6*).

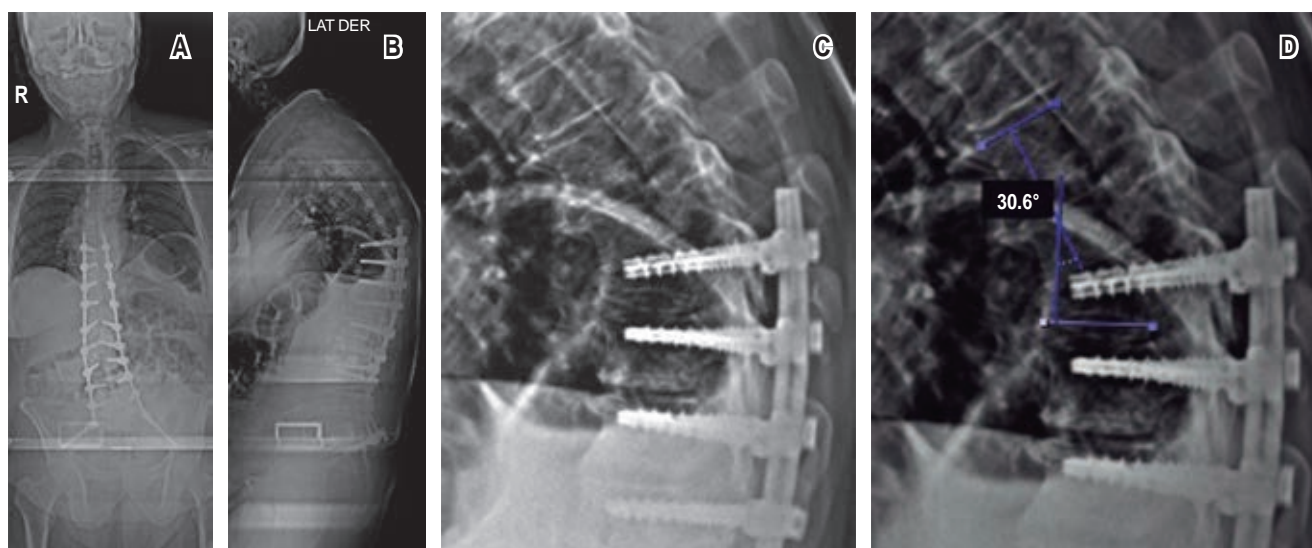


**Figure 1:**

**A)** AP X-ray with degenerative lumbar scoliosis a L4 apex and 40° Cobb angle, L3-L4 and L4-L5 laterolisthesis. **B)** Axial traction X-ray, showing reduction of scoliosis up to 31.4°.



**Figure 2:**  
Immediate post-operative  
X-ray control.



**Figure 3:** Six weeks post-operative X-ray control. **A)** Coronal adequate correction. **B)** Kyphosis cephalad to the upper instrumented vertebra. **C and D)** Evidence of fracture of T9, with a regional kyphosis angle of 30.6°.

After six weeks of surgical treatment, patient with an adequate clinical and radiological outcome.

### DISCUSSION

Process of selecting an adequate option is complex, as it is to determine up to the level to fuse. Satisfactory surgical outcome is about 63 and 45% required a re-intervention.<sup>1</sup> As is known, kyphosis and instability

progression of the adjacent segment, is the path for a failed treatment.<sup>9</sup> Thoracic spine is divided in two parts, a rigid (T1-T7) and a semi-rigid (T8-T12), so stopping in a semi-mobile segment could affect the development of the fusion. Most common post-surgical complications of thoracic fusion are the Proximal junctional kyphosis (PJK) and the proximal junctional failure (PJF), risks factors that influenced on this are osteoporosis and neuromuscular disorder (both in this



case).<sup>10,11</sup> Prevalence of PJK after and adult deformity spine surgery (ADS) is about 17-39%.<sup>12,13</sup> Decision making of instrumentation extension is complex, since is not only one more surgery, but establish the level and type of construction. Vertebroplasty for PJK prevention has an unconcluded evidence.<sup>14,15</sup> The construction option selected for treatment of the PJF was to prevent a posterior PJK. Using a double rod on the unstable segment plus an anterior support with vertebroplasty,

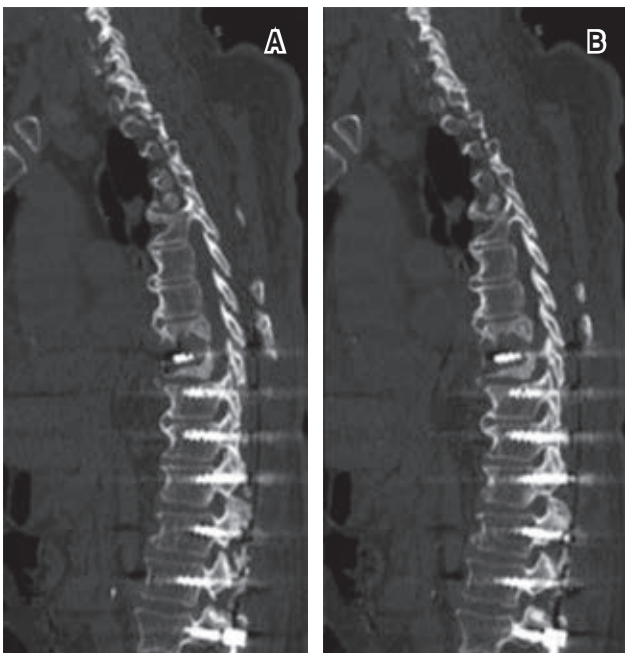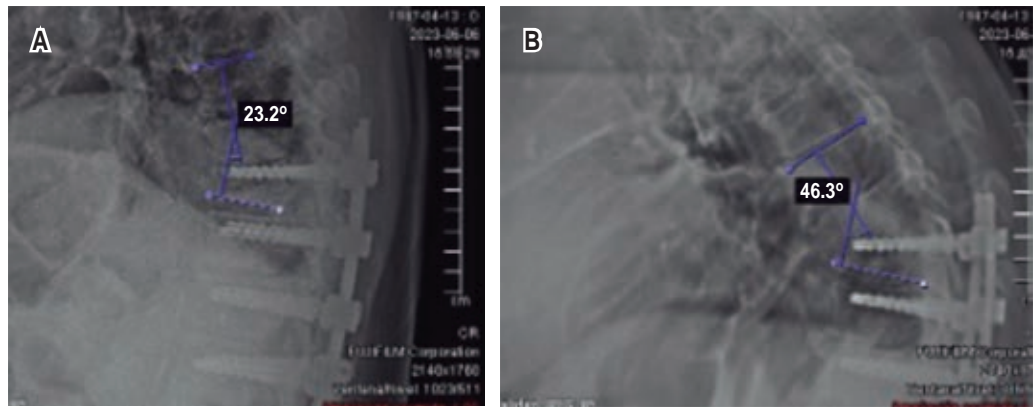
and then a semi-rigid transition to the upper level using the transverse process hooks.<sup>16-18</sup> We also recommend the algorithm proposed by Schroeder, to treat spinal deformation with PD.<sup>19,20</sup>

### CONCLUSIONS

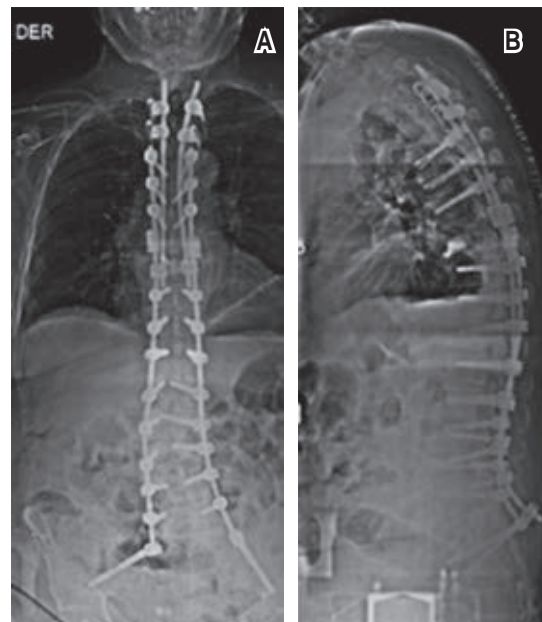
Decision making to treat spine degenerative condition with PD is complicated, nevertheless, it is well known

**Figure 4:**

**A)** Supine X-ray regional kyphosis angle of 23.2°. **B)** Standing X-ray regional kyphosis angle of 46.3°.



**Figure 5: A)** Right foraminial view. **B)** Left foraminial view. On both sides, evidence of a bone cavity localized in the upper instrumented vertebra, included lysis of the inferior platform of T8.



**Figure 6:** Immediate post-operative control X-ray. **A)** Coronal view. **B)** Sagittal view. Both views showing a prolonged rod to the upper transpedicular screw, using an end-to-end connector. While an anterior reinforcement with vertebroplasty and a rod connecting T9 to T3, using a side-to-side connector.

that a multidisciplinary team must be involved. Combination of both types of illness (degenerative spine condition and PD) and a PJF complication, semi-rigid construction transition and vertebroplasty reinforcement gave an adequate stability to the spine in this case.

## REFERENCES

- Sarkiss CA, Fogg GA, Skovrlj B, Cho SK, Caridi JM. To operate or not?: a literature review of surgical outcomes in 95 patients with Parkinson's disease undergoing spine surgery. *Clin Neurol Neurosurg* [Internet]. 2015; 134: 122-125. Available in: <http://dx.doi.org/10.1016/j.clineuro.2015.04.022>
- Hayes MT. Parkinson's disease and parkinsonism. *Am J Med* [Internet]. 2019; 132: 802-807. Available in: <http://dx.doi.org/10.1016/j.amjmed.2019.03.001>
- Doherty KM, van de Warrenburg BP, Peralta MC, Silveira-Moriyama L, Azulay J-P, Gershanik OS, et al. Postural deformities in Parkinson's disease. *Lancet Neurol* [Internet]. 2011; 10: 538-549. Available in: [http://dx.doi.org/10.1016/s1474-4422\(11\)70067-9](http://dx.doi.org/10.1016/s1474-4422(11)70067-9)
- Watanabe G, Palmisciano P, Conching A, Ogasawara C, Ramanathan V, Alfawares Y, et al. Degenerative spine surgery in patients with Parkinson disease: a systematic review. *World Neurosurg* [Internet]. 2023; 169: 94-109.e2. Available in: <http://dx.doi.org/10.1016/j.wneu.2022.10.065>
- van den Bos F, Speelman AD, Samson M, Munneke M, Bloem BR, Verhaar HJJ. Parkinson's disease and osteoporosis. *Age Ageing* [Internet]. 2013; 42: 156-162. Available in: <http://dx.doi.org/10.1093/ageing/afs161>
- Behl T, Arora A, Singla RK, Sehgal A, Makeen HA, Albratty M, et al. Understanding the role of "sunshine vitamin D" in Parkinson's disease: A review. *Front Pharmacol* [Internet]. 2022; 13: 993033. Available in: <http://dx.doi.org/10.3389/fphar.2022.993033>
- Puvanesarajah V, Jain A, Qureshi R, Carstensen SE, Tyger R, Hassanzadeh H. Elective thoracolumbar spine fusion surgery in patients with Parkinson disease. *World Neurosurg* [Internet]. 2016; 96: 267-271. Available in: <http://dx.doi.org/10.1016/j.wneu.2016.09.014>
- Galeoto G, Berardi A, Colalelli F, Pelosin E, Mezzarobba S, Avanzino L, et al. Correlation between Quality of Life and severity of Parkinson's Disease by assessing an optimal cut-off point on the Parkinson's disease questionnaire (PDQ-39) as related to the Hoehn & Yahr (H&Y) scale. *Clin Ter* [Internet]. 2022; 173: 243-248. Available in: [https://www.clinicaterapeutica.it/2022/173/3/12\\_GALEOTO.pdf](https://www.clinicaterapeutica.it/2022/173/3/12_GALEOTO.pdf)
- Babat LB, McLain RF, Bingaman W, Kalfas I, Young P, Rufo-Smith C. Spinal surgery in patients with Parkinson's disease: Construct failure and progressive deformity. *Spine (Phila Pa 1976)* [Internet]. 2004; 29: 2006-2012. Available in: <http://dx.doi.org/10.1097/01.brs.0000138306.02425.21>
- Prablek M, McGinnis J, Winocour SJ, Reece EM, Kakarla UK, Raber M, et al. Failures in thoracic spinal fusions and their management. *Semin Plast Surg* [Internet]. 2021; 35: 020-024. Available in: <http://dx.doi.org/10.1055/s-0041-1723832>
- Han X, Ren J. Risk factors for proximal junctional kyphosis in adult spinal deformity after correction surgery: A systematic review and meta-analysis. *Acta Orthop Traumatol Turc* [Internet]. 2022; 56: 158-165. Available in: <http://dx.doi.org/10.5152/j.aott.2022.21255>
- Yoshida G, Ushirozako H, Hasegawa T, Yamato Y, Kobayashi S, Yasuda T, et al. Preoperative and postoperative sitting radiographs for adult spinal deformity surgery: Upper instrumented vertebra selection using sitting C2 plumb line distance to prevent proximal junctional kyphosis. *Spine (Phila Pa 1976)* [Internet]. 2020; 45: E950-E958. Available in: <http://dx.doi.org/10.1097/brs.00000000000003452>
- Shlobin NA, Le N, Scheer JK, Tan LA. State of the evidence for proximal junctional kyphosis prevention in adult spinal deformity surgery: a systematic review of current literature. *World Neurosurg* [Internet]. 2022; 161: 179-189.e1. Available in: <http://dx.doi.org/10.1016/j.wneu.2022.02.063>
- Rahmani R, Sanda M, Sheffels E, Singleton A, Stegelmann SD, Kane B, et al. The efficacy of prophylactic vertebroplasty for preventing proximal junctional complications after spinal fusion: a systematic review. *Spine J* [Internet]. 2022; 22: 2050-2058. Available in: <http://dx.doi.org/10.1016/j.spinee.2022.07.104>
- Han S, Hyun SJ, Kim KJ, Jahng TA, Jeon SI, Wui SH, et al. Effect of vertebroplasty at the upper instrumented vertebra and upper instrumented vertebra +1 for prevention of proximal junctional failure in adult spinal deformity surgery: A comparative matched-cohort study. *World Neurosurg* [Internet]. 2019; 124: e436-e444. Available in: <http://dx.doi.org/10.1016/j.wneu.2018.12.113>
- Lange T, Schmoelz W, Gosheger G, Eichinger M, Heinrichs CH, Boevingloh AS, et al. Is a gradual reduction of stiffness on top of posterior instrumentation possible with a suitable proximal implant? A biomechanical study. *Spine J* [Internet]. 2017; 17: 1148-1155. Available in: <http://dx.doi.org/10.1016/j.spinee.2017.03.021>
- Dubousset J, Diebo BG. Proximal junctional kyphosis in modern spine surgery: Why is it so common? *Spine Surg Relat Res* [Internet]. 2023; 7: 120-128. Available in: <http://dx.doi.org/10.22603/ssrr.2022-0100>
- Doodkorte RJP, Vercoulen TFG, Roth AK, de Bie RA, Willems PC. Instrumentation techniques to prevent proximal junctional kyphosis and proximal junctional failure in adult spinal deformity correction—a systematic review of biomechanical studies. *Spine J*

- [Internet]. 2021; 21: 842-854. Available in: <http://dx.doi.org/10.1016/j.spinee.2021.01.011>
19. Vercoulen TFG, Doodkorte RJP, Roth A, de Bie R, Willems PC. Instrumentation techniques to prevent proximal junctional kyphosis and proximal junctional failure in adult spinal deformity correction: a systematic review of clinical studies. *Global Spine J* [Internet]. 2022; 12: 1282-1296. Available in: <http://dx.doi.org/10.1177/21925682211034500>
  20. Schroeder JE, Hughes A, Sama A, Weinstein J, Kaplan L, Cammisa FP, et al. Lumbar spine surgery in patients with Parkinson disease. *J Bone Joint Surg Am* [Internet]. 2015; 97: 1661-1666. Available in: <http://dx.doi.org/10.2106/jbjs.n.01049>

**Conflict of interest:** the authors have no conflict of interest.