

Laparoscopic repair of a diaphragmatic hernia after laparoscopic omental flap harvest for the treatment of sternal reconstruction

Reparación laparoscópica de hernia diafragmática post-avance laparoscópico de colgajo de epiplón para reconstrucción esternal

Dr. Morris E Franklin, Dr. César Gálvez Hernández, Dr. Jorge M Treviño, Dr. Oscar Villegas Cabello, Dr. Luis Salgado Cruz, Dra. Dulce Salazar López

Abstract

Background: The use of omentum to cover sternal dehiscence historically has required a formal laparotomy. The laparoscopic approach to harvest omentum has the potential to decrease the physiological stress of laparotomy and its complications. This technique was first reported by Saltz in 1993. On the other hand, in 1995, Marks published the first case of successful laparoscopic repair of a diaphragmatic hernia. Since then, other reports have appeared in the surgical literature that support the safety, feasibility, and advantages of laparoscopic repair compared with conventional surgery.

Description: A 75-year-old male patient with a history of coronary artery bypass grafting procedure. His sternotomy got infected and underwent surgical debridement producing a chest wall defect. Two months later, he underwent a laparoscopic omental flap harvest for coverage of the thoracic defect. Seven months later, he developed a diaphragmatic hernia containing most of the stomach inside the thorax. He was operated laparoscopically, reducing the hernia sac, closing the diaphragmatic defect, and reinforcing it with a Surgisis® mesh. His postoperative course showed no complications and was discharged in good condition.

Discussion: To our knowledge, this is the first reported case of a laparoscopic repair of a diaphragmatic hernia occurring as a late complication of laparoscopic omental flap harvest for sternal recon-

Resumen

Antecedentes: El uso de epiplón para cubrir dehiscencias esternales históricamente ha requerido de una laparotomía. El abordaje laparoscópico para avanzar colgajos de epiplón tiene el potencial de disminuir el estrés fisiológico de una laparotomía y sus complicaciones. Dicha técnica fue realizada por primera vez por Saltz en 1993. Por otra parte, en 1995, Marks publicó el primer caso de una reparación laparoscópica de hernia diafragmática. Desde entonces, varios reportes apoyan la seguridad y ventajas de tal abordaje sobre la cirugía convencional.

Descripción: Paciente masculino de 75 años postoperado de revascularización miocárdica. Se infectó su esternotomía y se desbridó produciéndose un defecto esternal. Fue sometido a avance laparoscópico de colgajo de epiplón para cubrir dicho defecto. Siete meses después desarrolla una hernia diafragmática con la mayor parte del estómago localizado en el tórax. Se intervino por vía laparoscópica, se redujo el contenido herniario, se cerró el defecto de forma primaria y se reforzó con una malla de Surgisis®. La evolución postquirúrgica del paciente fue satisfactoria y fue dado de alta en buenas condiciones.

Discusión: A nuestro saber, es el primer caso reportado de reparación laparoscópica de hernia diafragmática que ocurre como complicación tardía de un avance laparoscópico de colgajo de epiplón. Los

Texas Endosurgery Institute, San Antonio, Texas, USA.

Trabajo presentado en la modalidad de video en el XIV Congreso Internacional de Cirugía Endoscópica de la AMCE en Mayo del 2005 en Puerto Vallarta, Jalisco, México.

Recibido para publicación: 6 diciembre 2005

Aceptado para publicación: 24 mayo 2006

Correspondencia: Dr. César Antonio Gálvez Hernández. Escuela de Graduados en Medicina del TEC de Monterrey, Postgrado en Cirugía General. Avenida Ignacio Morones Prieto Núm. 3000 Poniente. Colonia Los Doctores. Monterrey, Nuevo León, México. 64710.

Teléfono: (81) 83471010, Ext. 8303 y 8308. Fax: (81) 83898384.

Correo electrónico: cgalvezhdez@gmail.com

struction. Our results show that this procedure is safe and without short-term complications.

Key words: Laparoscopic, diaphragmatic, hernia, omental, flap, harvest, sternal, reconstruction.

Cir Gen 2006;28:257-261

resultados tempranos muestran que el procedimiento es seguro y sin complicaciones a corto plazo.

Palabras clave: Laparoscópica, diafragmática, hernia, epiplón, colgajo, avance, esternal, reconstrucción.

Cir Gen 2006;28:257-261

Background

The use of omentum to cover sternal dehiscence has been employed for many years. Jobet and Lambel first described the clinical use of the omentum in 1826 for the treatment of intestinal wounds.¹

Harvesting omentum for coverage of a sternal wound historically has required a formal laparotomy, which is associated with significant morbidity, especially pulmonary associated problems in patients who already have a significant limitation in their respiratory function. However, the use of laparoscopy to harvest omentum has the potential to decrease the physiological stress of laparotomy and its potential complications, thus making the omental flap option better for seriously ill patients. The laparoscopic omental harvest was first reported by Saltz in 1993.²

In 1886, Riolfi reported the first successful repair of a diaphragmatic hernia.³ Many years later, in 1995, Marks et al. published what is probably the first case of successful laparoscopic repair of a diaphragmatic laceration.⁴ Since then, other reports have appeared in the surgical literature that support the safety, feasibility, and advantages of laparoscopic repair as compared to conventional surgery.⁵⁻¹¹

To our knowledge, there has been no case report of a diaphragmatic hernia occurring as a late complication of laparoscopic omental flap harvest. We present the case of a laparoscopically repaired diaphragmatic hernia after laparoscopic omental flap harvest for reconstruction of a complex sternal wound.

Case report

A 75-year-old man with a medical history of coronary artery disease and diabetes mellitus underwent a coronary artery bypass grafting procedure. He was discharged without complications. Four weeks later he developed a sternal wound infection. After surgical debridement, the patient still had a large chest wall defect. Two months later the patient underwent a laparoscopic omental flap harvest for coverage of the chest wall defect. This required delivery of the omentum to the chest through the diaphragm, maintaining its vascular supply. The omentum was covered by a skin graft. His postoperative course showed no complications and he was discharged in good condition. Seven months later he complained about not gaining weight. His clinical evaluation included an abdominal CT scan that demonstrated a diaphragmatic hernia containing most of the stomach in the anterior chest. Laparoscopic repair of the diaphragmatic hernia was planned.

In the operating room, the patient was placed supine on a split-leg table with his arms extended (Lloyd-Davies). The operating surgeon stood between the legs and assistants stood on each side of the patient. A 5-mm trocar was placed in the right upper quadrant, two 5-mm trocars in the epigastrium and a 5-mm and 10-mm trocars in the left upper quadrant. Initial inspection of the esophageal hiatus and left hemidiaphragm confirmed the findings of the abdominal CT scan. The diaphragmatic defect was 5 cm anterior and lateral to the esophageal hiatus, in the left hemidiaphragm (**Figure 1**). Blunt laparoscopic graspers were used to reduce the stomach into the abdominal cavity. Dense adhesions between the stomach and the hernia sac were divided. The hernia sac was excised partially. There were no lung injuries and no changes in the ventilatory parameters intraoperatively. The hernia defect measured 9 x 6 cm (**Figure 2**). It was closed primarily with interrupted 2-0 non-absorbable sutures placed laparoscopically (**Figure 3**) and reinforced with a Surgisis® mesh (Cook Medical, Bloomington, IN). The mesh was secured with staples (Endostapler, Ethicon, Cincinnati, Ohio) (**Figure 4**).

Next, a plastic surgeon excised the redundant anterior thoracic wall skin (approximately 400 cm²) and closed the wound primarily. The total blood loss was 10 cm³ and the operative time was 118 minutes. The patient was extubated in the OR and transferred to the ICU for hemodynamic monitoring. The postoperative course was favorable. He was discharged on the fourth postoperative day. At a one-year follow-up examination, he is still asymptomatic and with good cosmetic results.

Discussion

Infection and dehiscence of a median sternotomy wound is an uncommon but potentially devastating complication of open heart surgery. Rates of sternal infection after cardiac surgery range from 0.4 to 5.0%.¹² Multiple management options have been proposed to deal with this serious and challenging complication. Conservative surgical strategies include debridement followed by delayed primary closure or closure by secondary intention.¹³ Flap closure has shown an increased success of primary therapy.¹⁴ The most important advantage of using autologous tissue flaps is the presence of healthy, well vascularized tissue, mobilized from an area away from the infected wound that will assist in the control of local infection, promote wound healing, and provide adequate coverage of the mediastinal organs.¹⁵⁻¹⁷

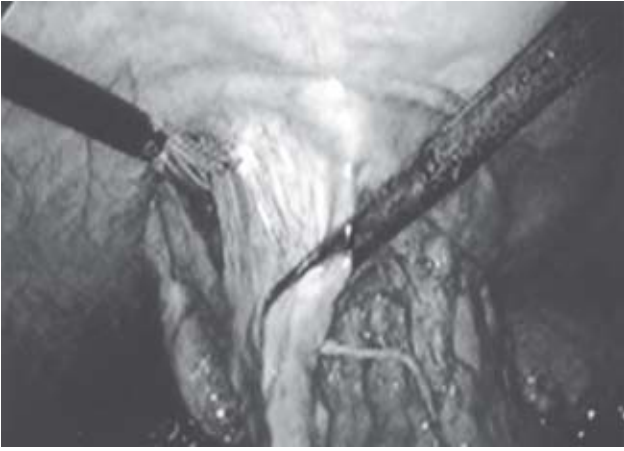

Fig. 1. Diaphragmatic defect.

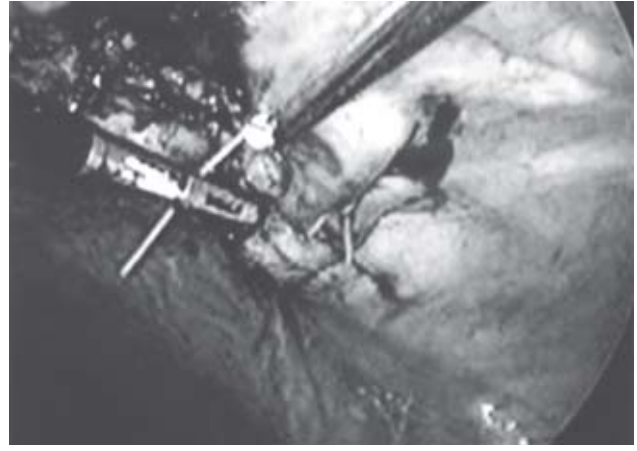


Fig. 3. Sutures placed laparoscopically.

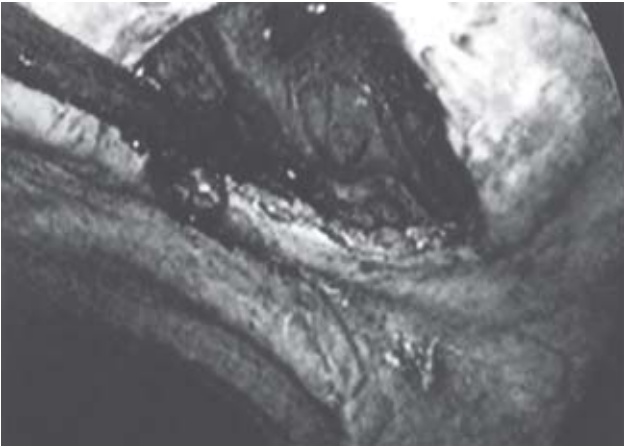


Fig. 2. Hernia defect.




Fig. 4. Mesh secured with staples.

The omentum has the capability of adapting to large wounds, contains a rich vascular and lymphatic supply and has angiogenic activity that may stimulate vascularization in ischemic tissues.¹⁸ Lee et al., in 1976, proposed the transposition of the omentum to eliminate mediastinal open space in cases of infected sternotomy wounds, with good results.¹⁹

Franklin et al., in 2003, published the largest series of laparoscopically harvested omental flaps for complex, postsurgical mediastinal wounds. Results indicated that the procedure was safe and efficacious.²⁰

Our case is the first one to report a diaphragmatic hernia occurring as a late complication of laparoscopic omental flap harvest for reconstruction of a complex sternal wound. The treatment consisted of a laparoscopic hernia reduction, primary closure of the defect and placement of a prosthetic mesh as reinforcement. Early results show that this is a safe procedure and has virtually no complications in a short-term follow-up.

The vast majority of reports describing the laparoscopic repair of diaphragmatic injuries are in the acute

setting (< 24 hrs). Few reports address the laparoscopic repair of chronic diaphragmatic hernias.^{21,22}

Dissection planes are often difficult to discern when repairing a chronic diaphragmatic hernia. As time passes, they increase in size, their edges fibrose circumferentially, and become fixed. The majority will require a prosthetic mesh to provide an adequate tension-free closure (**Table I**). This is in contrast to most acute diaphragmatic injuries that are easily amendable to primary repair.

Because of their clinical rarity, prospective and retrospective studies comparing conventional open with laparoscopic chronic diaphragmatic hernia repairs have not been performed. There have been no recurrences reported in the surgical literature in the laparoscopic group, but long-term follow-up is needed.

Patient demographics, hernia characteristics and perioperative outcomes for the reported cases of laparoscopic repair of chronic diaphragmatic hernias are summarized in **tables I and II**.

The laparoscopic approach for the treatment of this

Table I.
Laparoscopic repair of chronic diaphragmatic hernias.

| Author | Etiology | Location/Size (cm) | Evolution (time) | Type of repair |
|-----------------------------|------------------|--------------------|------------------|---------------------------------|
| Campos 1991 ²³ | blunt/iatrogenic | left diaphragm/7.5 | 21 y | PTFE mesh |
| Rasiah 1995 ⁵ | blunt/crush | left diaphragm/5 | 5 wk | Primary repair |
| Slim 1998 ²⁴ | blunt/MVA | left diaphragm/12 | 13 mo | Polypropylene mesh |
| Domene 1998 ¹⁰ | blunt/MVA | left diaphragm/12 | 12 mo | Primary repair |
| Heniford 1999 ²¹ | penetrating | left diaphragm/6 | 23 mo | PTFE mesh |
| Cueto 2001 ²² | MVA | left diaphragm/8 | 8 mo | Primary closure + PTFE mesh |
| | MVA | left diaphragm/NA | 6 wk | PTFE mesh |
| Franklin 2005 | iatrogenic | left diaphragm/9 | 9 mo | Primary closure + Surgisis mesh |

PTFE, polytetrafluoroethylene; **MVA**, motor vehicle accident; **NA**, Non-available; **cm**, centimeters; **wk**, weeks; **mo**, months; **y**, years.

Table II.
Laparoscopic repair of chronic diaphragmatic hernias.

| Author | Operative time (min) | Length of Stay (d) | Perioperative Complications | Follow-up |
|-----------------------------|----------------------|--------------------|-----------------------------|-----------|
| Campos 1991 ²³ | NA | 1 | None | 1 wk |
| Rasiah 1995 ⁵ | 90 | 2 | None | 18 mo |
| Slim 1998 ²⁴ | NA | 7 | None | 3 mo |
| Domene 1998 ¹⁰ | NA | 5 | None | NA |
| Heniford 1999 ²¹ | 160 | 2 | None | 6 mo |
| Cueto 2001 ²² | NA | 3 | None | 26 mo |
| | NA | 4 | None | 16 mo |
| Franklin 2005 | 118 | 4 | None | 1 y |

NA, Non-available; **min**, minutes; **d**, days; **wk**, weeks; **mo**, months; **y**, years.

problem seems to be safe and effective. Our patient benefited from this approach with an early discharge from the hospital and a rapid return to daily activities.

References

- Fix RJ, Vasconez LO. Use of the omentum in chest wall reconstruction. *Surg Clin North Am* 1989; 69: 1029-1046.
- Saltz R, Stowers R, Smith M, Gadacz TR. Laparoscopically harvested omental free flap to cover a large soft tissue defect. *Ann Surg* 1993; 217: 542-546.
- Martin I, O'Rourke N, Gotley D, Smithers M. Laparoscopy in the management of diaphragmatic rupture due to blunt trauma. *Aust NZ Surg* 1998; 68: 584-586.
- Marks JM, Ramey RL, Baringer DC, Aszodi A, Ponsky JL. Laparoscopic repair of a diaphragmatic laceration. *Surg Laparosc Endosc* 1995; 5: 415-418.
- Rasiah KK, Crowe PJ. Laparoscopic repair of a traumatic diaphragmatic hernia. *J Laparoendosc Surg* 1995; 5: 405-407.
- Hortsmann O, Neufanq T, Post S, Stephan H, Becker H. Laparoscopic diagnosis and therapy of closed traumatic diaphragmatic rupture. *Chirurg* 1996; 67: 744-747.
- Rosati C. Acute traumatic injury of the diaphragm. *Chest Surg Clin N Am* 1998; 8: 371-379.
- Domene CE, Volpe P, Santo MA, et al. Laparoscopic repair of chronic traumatic diaphragmatic hernia: case report and review of the literature. *Rev Hosp Clin Fac Med Sao Paulo* 1997; 52:271-275.
- González-Rapado L, Collera-Rodríguez SA, Pérez-Esteban M, Alfonso O, Ramírez-Barba EJ. Diaphragmatic hernia caused by penetrating injury: emergency laparoscopic reconstruction. *Rev Gastroenterol Mex* 1997; 62: 281-283.
- Domene CE, Volpe P, Santo MA, Omari P, Szachnowicz S, Pennotti HW. Laparoscopic treatment of traumatic diaphragmatic hernia. *J Laparoendosc Surg Adv Tech A* 1998; 8: 225-229.
- Adamthwaite DN. Traumatic diaphragmatic hernia: a new indication for laparoscopy. *Br J Surg* 1984; 71: 315.
- Brown RE, McCall TE, Neumeister MW. Use of free-tissue transfer in the treatment of median sternotomy wound infections: retrospective review. *J Reconstr Microsurg* 1999; 15: 171-175.
- Johnson JA, Gall WE, Gundersen AE, Cogbill TH. Delayed primary closure after sternal wound infection. *Ann Thorac Surg* 1989; 47: 270-273.
- Nahai F, Rand RP, Hester TR, Bostwick J 3rd, Jurkiewicz MJ. Primary treatment of the infected sternotomy wound with muscle flaps: a review of 211 consecutive cases. *Plast Reconstr Surg* 1989; 84: 434-441.
- Cohen M, Silverman NA, Goldfaden DM, Levitsky S. Reconstruction of infected median sternotomy wounds. *Arch Surg* 1987; 22: 323-327.
- Jeevanandam V, Smith CR, Rose EA, Malm JR, Hugo NE. Single-stage management of sternal wound infections. *J Thorac Cardiovasc Surg* 1990; 99: 256-262.
- Castello JR, Centella T, Garro L, et al. Muscle flap reconstruction for the treatment of major sternal wound infections after cardiac surgery: a 10-year analysis. *Scand J Plast Reconstr Surg Hand Surg* 1999; 33: 17-24.
- Cartier R, Brunette I, Hashimoto K, Bourne WM, Schaff HV. Angiogenic factor: a possible mechanism for neovasculariza-

- tion produced by omental pedicles. *J Thorac Cardiovasc Surg* 1990; 99: 264-268.
19. Lee AB Jr, Schimert G, Shaktin S, Seigel JH. Total excision of the sternum and thoracic pedicle transposition of the greater omentum; useful stratagems in managing severe mediastinal infection following open heart surgery. *Surgery* 1976; 80: 433-436.
 20. Salameh JR, Chock DA, Gonazalez JJ, Koneru S, Glass JL, Franklin ME Jr. Laparoscopic harvest of omental flaps for reconstruction of complex mediastinal wounds. *J Soc Laparoendosc Surg* 2003; 7: 317-322.
 21. Shah S, Matthews BD, Sing RF, Heniford T. Laparoscopic repair of a chronic diaphragmatic hernia. *Surg Laparosc Endosc Percutan Tech* 2000; 10: 182-186.
 22. Cueto J, Vázquez-Frías JA, Nevarez R, Poggi L, Zundel N. Laparoscopic repair of traumatic diaphragmatic hernia. *Surg Laparosc Endosc Percutan Tech* 2001; 11: 209-212.
 23. Campos LI, Sipes EK. Laparoscopic repair of diaphragmatic hernia. *J Laparoendosc Surg* 1991; 1: 369-73.
 24. Slim K, Bousquet J, Chipponi J. Laparoscopic repair of missed blunt diaphragmatic rupture using a prosthesis. *Surg Endosc* 1998; 12: 1358-60.

