

# A natural biomembrane as a new proposal for the treatment of pressure ulcers

*Biomembrana natural como uma nova proposta de tratamento para as úlceras de pressão*

Marco Andrey Cipriani Frade<sup>a</sup>, Adriana Martinelli Salathiel<sup>a</sup>, Eduardo Lopez Mazzucato<sup>a</sup>,  
Joaquim Coutinho Netto<sup>b</sup>, Norma Tiraboschi Foss<sup>a</sup>

<sup>a</sup>Divisão de Dermatologia, Departamento de Clínica Médica. <sup>b</sup>Departamento de Bioquímica. Faculdade de Medicina de Ribeirão Preto. SP. Brasil.

## Correspondence:

Marco Andrey Cipriani Frade  
Hospital das clínicas. Faculdade de Medicina de Ribeirão Preto-USP  
Av. Bandeirantes nº 3900, Monte Alegre.  
14049900 Ribeirão Preto-USP. Brasil.  
Tel.: (+55) 16 602 24 47  
Fax.: (+55) 16 633 02 36  
e-mail: mandrey@fmrp.usp.br

## Summary

*Pressure ulcer is a common syndrome of difficult treatment among bedridden individuals, with clinical and socioeconomic repercussions. A recently developed natural biomembrane (NBM) as a therapeutic option for leg ulcers with debriding and neo-angiogenic properties encouraged us to apply it as a treatment for pressure ulcers. The authors report the results obtained with the NBM dressing on alternate days and followed up two cases for 6 months: a 76-year-old woman with sepsis and malnutrition and a sacral ulcer (15 x 13 cm wide x 1.5 cm deep) and a 77-year-old man with sequel of a brain vascular accident and two 3 cm deep sacral ulcers of 5.6 x 6.4 cm (left) and 6.6 x 8 cm (right). NBM promoted rapid debridement, an important granulogenic stimulus and full healing within less than 6 months in both cases. Thus, the natural biomembrane showed outstanding debriding and neo-angiogenic properties in the treatment of pressure ulcers, representing an effective, practical and low cost dressing.*

(Cipriani Frade MA, Coutinho Netto J, S. Martinelli Salathiel A, Tiraboschi Foss N. A natural biomembrane as a new proposal for the treatment of pressure ulcers. Med Cutan Iber Lat Am 2006;34:137-142)

**Key Words:** pressure ulcers, healing, biomembrane, latex, dressing, treatment.

## Resumo

Úlceras de pressão é uma síndrome de difícil tratamento entre pacientes acamados com repercussões clínicas e socioeconômicas importantes. O recente desenvolvimento da biomembrana natural como opção terapêutica para úlceras de perna com suas atividades desbridante e neoangiogênica motivaram a sua utilização em úlceras de pressão. Os autores relatam os resultados obtidos com curativos de biomembrana natural em dias alternados e seguimento de dois casos clínicos por 6 meses: Uma paciente com 76 anos com sepse e desnutrida com úlcera sacral medindo 15 x 13 cm de tamanho e 1.5 cm de profundidade e um paciente de 77 anos, com seqüelas de acidente vascular encefálico com duas úlceras sacrais de 3 cm de profundidade medindo 5.6 x 6.4 cm (esquerda) e 6.6 x 8 cm (direita). Desde os primeiros curativos, a biomembrana promoveu rápido desbridamento e um importante estímulo granulogênico, cicatrizando completamente as feridas com menos de 6 meses em ambos os casos. Assim, a biomembrana natural evidenciou propriedades desbridante e neoangiogênica no tratamento das úlceras de pressão, representando um curativo eficaz, prático e de baixo custo.

**Palavras-chave:** úlcera de pressão, cicatrização, biomembrana, látex, curativo, tratamento.

Pressure ulcers are defined as skin or soft part lesions of ischemic etiology, secondary to an increase of external pressure, which are usually present on bone prominences such as trochanters, heels, sacrum, and malleoli. The main factors associated with the occurrence of pressure ulcers are prolonged surgeries, fecal or urinary incontinence, reduced concentrations of serum proteins such as albumin, sensory disorders, skin maceration, diabetes mellitus, and impaired mobility[1,2].

It is estimated that 17% of hospitalized patients present or will be susceptible to the development of pressure ulcers[3]. Keller et al[1] have reported that 3% to 22% of hospitalized patients develop pressure sores, mainly patients admitted to neurology units, where the incidence ranges from 5 to 50%. Seventy percent of these sores develop during the first two weeks

of hospitalization[1]. The time of healing of those ulcers is very variable according to the location and size of the ulcers, of the patient's clinical conditions and your base disease besides the cares in your attendance as frequency of the decubitus change, hygiene and cares with the patient's skin, needing taken multiprofessional care specialized during the hospitalization and in the owder-high. Ulcers involve increased hospital costs because they require prolonged hospitalization and treatment for pain, and lead to complications such as infections and amputations[4].

The wound healing process is constituted of a sequence of complex biological events that involve cellular and molecular processes, as the migration, inflammation, angiogenesis, synthesis and deposition of collagen and reepithelialization[5].

Firstly, the early inflammatory phase of the process of wound healing is being carried out mainly by neutrophils and macrophages. Also important during this phase is the increased vascular permeability needed for the cells and nutrients to reach the site of lesion[6].

In the next healing phase there is the phenomenon of tissue formation, mainly characterized by an increase of granulation tissue and re-epithelialization[6,7].

Finally, in the tissue-remodeling phase, in spite new collagen to continue being deposited, a resorption occurs due to increased degradation of old collagen by collagenases; macrophages begin to disappear, angiogenesis and fibroblast proliferation decrease. The extracellular matrix is also remodeled by metalloproteinases[6]. All these phenomena happen trying to reconstitute the cutaneous integrity, in other words, the scar.

Several types of treatment are available for pressure ulcers, such as hydrocolloids, silver sulfadiazine, and activate charcoal, among others, always in combination with prevention methods. However, despite the advances in new therapies for the treatment of these ulcers, few substances are able to accelerate the healing process beyond normal limits.

Since 1994 the activities of the biomembrane of latex from rubber tree *Hevea brasiliensis* ha been studied at University of São Paulo[8]. This is the latex biopolymer with protein fraction that induce the angiogenesis and the vascular permeability showed by chicken embryo chorioallantoic membrane (CAM) model and by rabbit intradermal injection and Evan's blue quantification respectively[9].

Frade et al observed clear clinical and histopathological signs of stimulation of granulation starting on the 15th day of treatment with the biomembrane, with a marked reduction of symptoms, including disappearance of pain, as well as closure of the lesion during the fourth month of treatment[8]. Additionally, it was found that the biomembrane elicited greater debridement of the wound and higher expression of vascular endothelial growth factor, indicating stimulation of neo-angiogenesis it also provided a harmonious induction and organization of cicatricial tissue in view of the observed dynamic profile of induced nitric oxide synthase and expression of transforming growth factor beta 1 [unpublished data, 2003].

With the increased life expectancy and the increased incidence of chronic-degenerative diseases in the world population, there is also an increase in the incidence of pressure ulcers and of their clinical, psychic and socioeconomic repercussions. Thus, in view of the benefits of the natural biomembrane as a dressing for leg ulcers, it is relevant to assess its use for the treatment of pressure ulcers. On this basis, the objective of the present report is to describe two clinical cases treated with the biomembrane at the Clinical University Hospital of FMRP-USP.

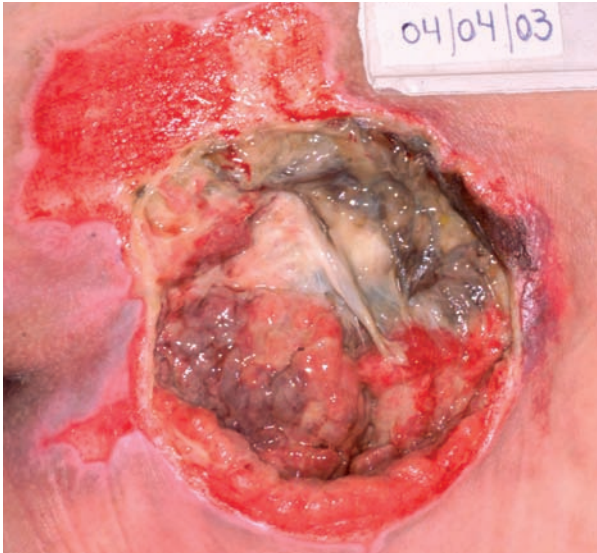
## Patients and Methods

### Case 1

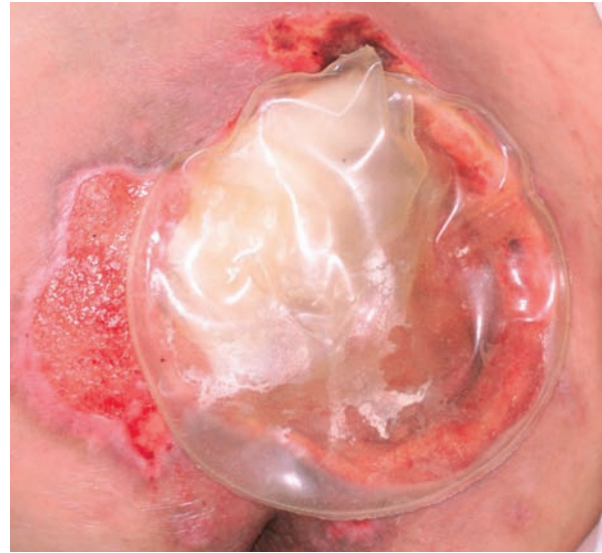A 76-year-old white Brazilian woman was submitted to appendectomy and to left salpingectomy, developing uremia and sepsis, as well as severe malnutrition and pressure ulcers in the heel and sacrum within 15 days. The patient was transferred to the University Hospital of FMRP-USP, where her pressure ulcers were treated by surgical debridement and daily dressings with 1% silver sulfadiazine during a 4-month period of hospitalization. Examination showed that the sacral wound was necrotic and, after the last debridement, had produced an ulcerated area measuring 15 x 13 cm in transverse and longitudinal diameter, respectively, and 1.5 cm in depth (Figure 1).

### Case 2

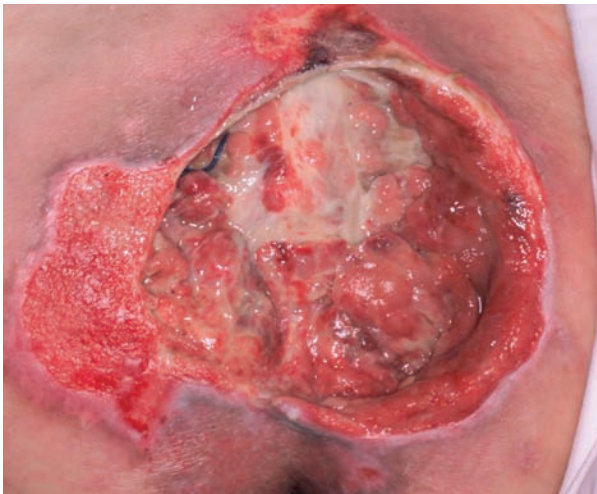A 77-year-old black Brazilian man had developed a non-secretory pituitary macroadenoma 8 years ago, with development of systemic arterial hypertension, adrenal insufficiency and obesity. His medical history revealed chronic obstructive pulmonary disease, repeated pneumonias and glaucoma. He was a chronic user of prednisone, 5 mg/day, thyroxine, 75 mg/day, and doxazosine, 4 mg/day. Admitted to the Intensive Care Center of our Institution 70 days before due to a brain vascular accident, he developed urinary incontinence, bilateral reduction of muscular strength, as well as two intercommunicating sacral ulcers



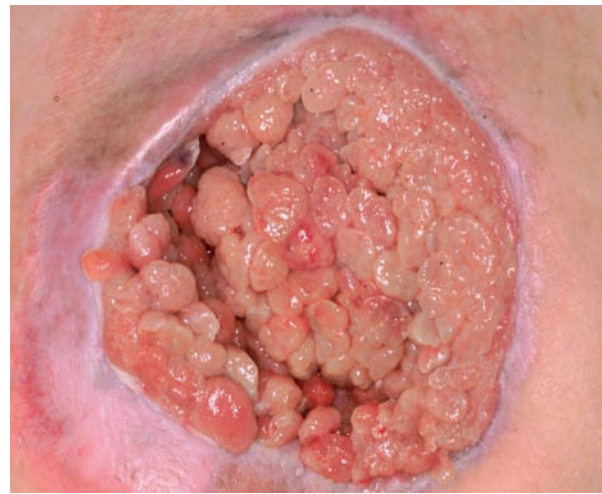**Figure 1.** Initial clinical aspect of the ulcerated sacral lesion with fibrin and necrosis.



**Figure 2.** Application of a natural biomembrane dressing.



**Figure 3.** Ulcer showing a reduction of fibrinous-necrotic tissue.



**Figure 4.** Filling of the cavity with exuberant granulation tissue reaching the skin margin after two months of treatment

measuring 5.6 x 6.4 cm on the left and 6.6 x 8.0 cm on the right (Figure 8), both about 3 cm deep. The ulcers had a clean bottom and no necrosis or signs of infection and were submitted to various anti-sore treatments without a satisfactory response.

### Dressing protocol

The dressings were applied on alternative days and consisted of cleaning of the ulcers with 0.9% physiological saline, lightly drying and application of the biomembrane covering the entire bottom of the wound, followed by the application of gauze

and bandages. Care was taken to avoid contact of the biomembrane with healthy skin and to guarantee its permanent contact with the bottom of the ulcer.

## Results

Regarding patient 1, after one week of treatment with biomembrane dressings there was a reduction of fibrinous-necrotic tissue and stimulation of granulation (Figure 3). After two months of treatment, with the patients being already at home, intense proliferation of granulation tissue occurred, filling the cavity and reducing the diameters of the lesion (Figures 5 and 5). After 5 months the wound showed organization of the granulation tissue and measured 3.7 x 5.5 cm (Figure 6), being further reduced to 1.0 x 3.0 cm at the beginning of the 6<sup>th</sup> month (Figure 7), and being fully healed at the end of the 6<sup>th</sup> month.

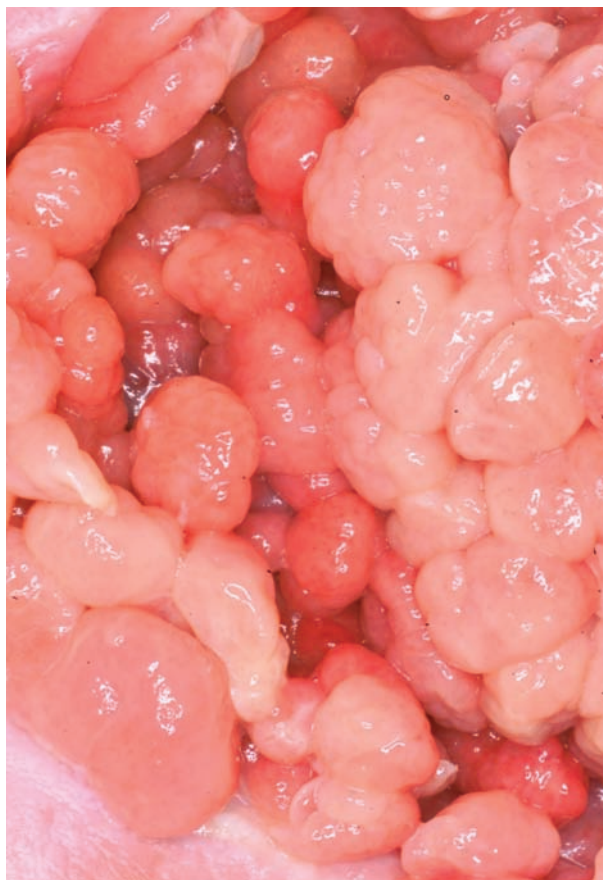When treatment was started in patient 2, a stimulation of granulation was observed, as well as re-epithelialization within 2 months (Figure 9) and full wound healing by the 4<sup>th</sup> month of treatment (Figure 10).

In both cases healing occurred with complete filling of the cavities, with the formation of flat and esthetic scars.

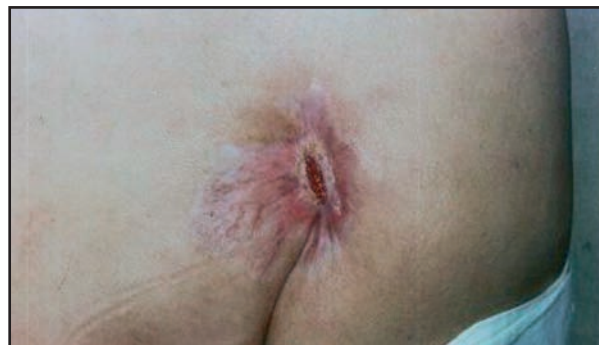The laboratory data for cases 1 and 2 obtained before treatment with the biomembrane are listed in table 1.

## Comment

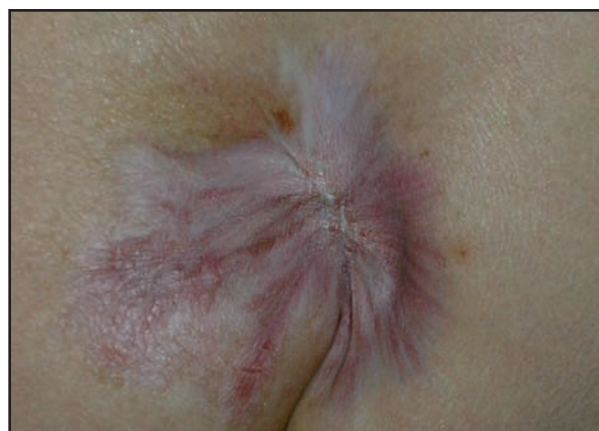The authors report two cases of pressure ulcers of chronic evolution that had not responded to various treatments until they were submitted to dressings with the biomembrane.



**Figure 5.** Close up view of granulation tissue.



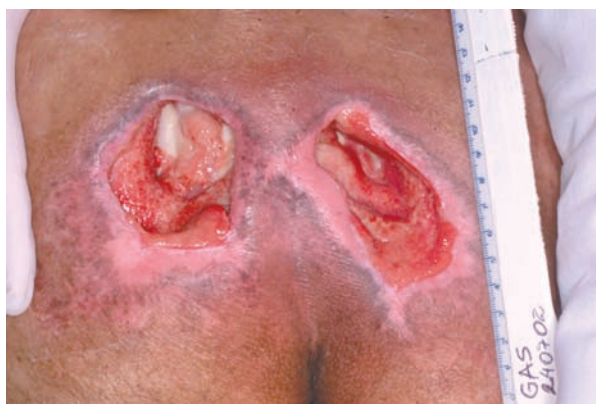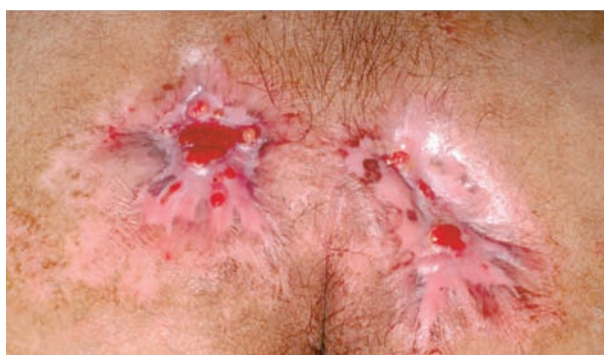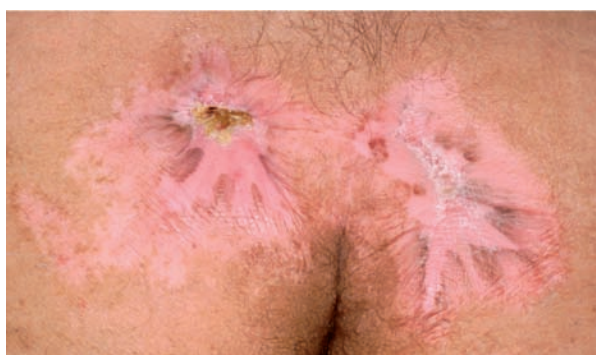**Figure 6.** Reduced ulcer size after 5 months of treatment.



**Figure 7.** Scar level with the skin and total re-epithelialization of the ulcer after 6 months of treatment..

**Table 1.** Exams performed before treatment with the natural biomembrane

Exam	Case 1	Case 2
Hemoglobin (mg/dl)	7.4	9.8
Hematocrit (mg/dl)	21	29.1
Total proteins (mg/dl)	5.4	5.0
Albumin (mg/dl)	2.1	2.3
Creatinine (mg/dl)	1.2	1.4

**Figure 8.** Initial clinical aspect of the sacral ulcers**Figure 9.** Filling with granulation tissue accompanied by re-epithelialization of the ulcers after two months of treatment with the natural biomembrane.**Figure 10.** Full ulcer healing without retraction or bulging after 4 months of treatment with the natural biomembrane.

The natural biomembrane favored intense exudation at the beginning of treatment, an event that appears to be related to its action on vascular permeability, facilitating rapid wound debridement, as visualized by the reduction of necrosis and fibrin (Figure 2).

Frade and collaborators[8,10,11,12] have reported that the natural biomembrane has debriding and neo-angiogenic properties that respect the natural healing process.

In both cases reported here, exuberant formation of granulation tissue was observed since the beginning of treatment with the biomembrane, an important fact for the phases of tissue formation and remodeling. The granulation tissue was more exuberant in these patient ones than in other treated ulcers with the biomembrana as venous ulcers[8] and in the diabetic patients[12], filling the entire cavity space, thus preventing the occurrence of bulging and dysmorphic scars which might favor the occurrence of future ulcerations at the same sites.

It is also important to emphasize the practical aspect of the natural biomembrane dressings, which can be easily applied both in the hospital and at home. An intense exudate production occurs at the beginning of treatment, promoting constant hydration of the wound, an important feature during the inflammatory and tissue formation phases. Also, the membrane does not adhere to the ulcerated bed, permitting painless and non-traumatic changes of dressings.

We conclude that the natural biomembrane stands out of the other dressings for your important properties regarding debridement and tissue formation, mainly granulogenesis, during the process of wound healing and represents an effective dressing of easy manipulation, with no risk of transmission of infectious-parasitic diseases, and of low cost for the treatment of pressure. In addition, it promotes flat and more esthetic scars.

## Acknowledgments

We would like to thank the photographic section of *FMRP-USP* and the foundation *FAEPA –Clinical Hospital of Faculty of Medicine of Ribeirão Preto –University of São Paulo* by financial supporting.

## References

- 1 Keller BPJA, Wille J, van Ramshorst B, van der Werken C. Pressure ulcers in intensive care patients: a review of risks and prevention. *Intensive Care Med* 2002;28:1378-88.
- 2 Schoonhoven L, Haalboom JRE, Bousema MT, Algra A, Grobbee DE, Grypdonck MH, Buskens E. Prospective cohort study of routine use of risk assessment scales for prediction of pressure ulcers. *BMJ* 2002;325:797.
- 3 Ferreira LM, Calil JA. Etiopatogenia e tratamento das úlceras por pressão. *Rev Diagnos Tratamento* 2001;6:36-40.
- 4 Young ZF, Evans A, Davis J. Nosocomial pressure ulcer prevention: A successful project. *J Nurs Adm* 2003;33:380-3.
- 5 Clark, R.A.F. Wound repair overview and general considerations. In: *The molecular and Cellular biology of wound repair*. Second edition, Plenum Press, New York, p. 95-141,1996.
- 6 Karukonda SR, Flynn TC, Boh EE, Mcburney EI, Russo GG, Millikan LE. The effects of drugs on wound healing. *Int J Dermatol* 2000;39:250-7.
- 7 Arnold F, West D. Angiogenesis in wound healing. *Pharmac Ther* 1991;52:407-22.
- 8 Frade MAC, Valverde RV, Violante MR, Coutinho-Netto J, Foss NT. Chronic phlebopatic skin ulcer: a therapeutic proposal. *Int J Dermatol* 2001;40:238-40.
- 9 Mendonça, RJ. Caracterização biológica de uma fração angiogênica do látex natural da seringueira *Hevea brasiliensis*. Dissertação de Mestrado – FMRP-USP,2004.
- 10 Frade MAC, Cursi IB, Andrade F, Coutinho-Netto J, Foss NT. Induction of leg wound healing by natural latex biomembrane. *Ann Dermatol Vénéreologie*, 2002;129:Suppl1: S823.
- 11 Frade MAC, Cursi IB, Andrade FF, Coutinho-Netto J, Foss NT. Stimulation of diabetic wound healing by natural latex biomembrane dressing. *Ann Dermatol Vénéreologie* 2002;129:Suppl1:S823.
12. Frade, MAC, Cursi IB, Andrade FF, Barbeta FM, Coutinho-Netto J, Foss NT. Management of diabetic skin wounds with natural latex biomembrane. *Med Cutan Iber Lat Am* 2004;32:157-62.