

# Generalized pustular psoriasis: treatment with etanercept

## *Psoriasis pustulosa generalizada. Tratamiento con etanercept*

A. Palomo Arellano<sup>1</sup>, LM Torres Iglesias<sup>1</sup>, I. Cervigón González<sup>1</sup>, B. Gil Pascual<sup>2</sup>

<sup>1</sup>Dermatology and <sup>2</sup>Pathological Anatomy Section. Nuestra Señora del Prado Hospital. Talavera de la Reina. Toledo. Spain.

### Correspondence:

Iván Cervigón González  
Sección de Dermatología  
Nuestra Señora del Prado Hospital  
Ctra. de Madrid, km. 114  
45600 Talavera de la Reina (Toledo). Spain.  
Tel.: +34 661838719  
e-mail: icervigon@sescam.jccm.es

### Summary

*The treatment of acute generalized pustular psoriasis has classically been carried out with oral retinoids, cyclosporine, methotrexate, dapsone, colchicine, corticoids, coal tar or PUVA, slow and partial responses, as well as recurrences when the medication is decreased or suspended, being very relatively frequent. Several cases of acute generalized pustular psoriasis treated with infliximab and with quick and effective responses have recently been published based on the physiopathological relationship between the tumor necrosis factor (TNF) and psoriasis.*

**Key words:** *pustular psoriasis, tumor necrosis factor alpha, etanercept, infliximab.*

### Resumen

El tratamiento de la psoriasis pustulosa generalizada aguda se ha venido realizando con retinoides orales, ciclosporina, metotrexato, dapsona, colchicina, corticoides, coal tar o PUVA, siendo relativamente frecuentes las respuestas parciales o lentas, así como las recurrencias cuando la medicación se reduce o suspende.

Recientemente se han publicado varios casos de psoriasis pustulosa aguda generalizada tratadas con infliximab y con respuestas rápidas y eficaces basadas en la relación entre el factor de necrosis tumoral (TNF) y la psoriasis.

(A. Palomo Arellano, LM Torres Iglesias, I. Cervigón González, B. Gil Pascual. Psoriasis pustulosa generalizada. Tratamiento con etanercept. Med Cutan Iber Lat Am 2009;37(5):224-226)

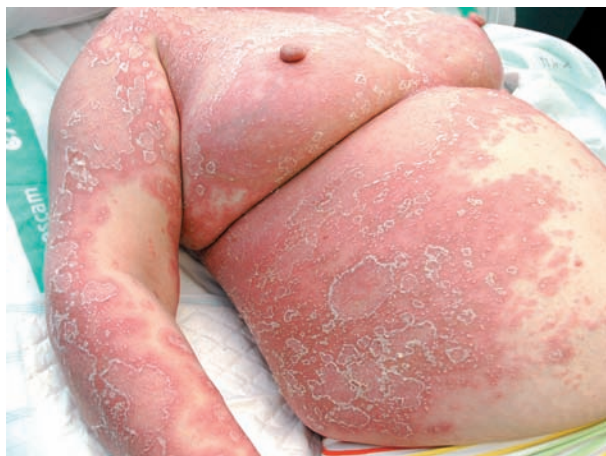**Palabras clave:** psoriasis pustulosa, factor de necrosis tumoral alfa, etanercept, infliximab.

Acute generalized pustular psoriasis, described by von Zumbusch in 1910,[1] is an infrequent and severe variant of psoriasis characterized by the presence of generalized inflammatory plaques where there are multiple sterile pustules, and it is accompanied by general discomfort, fever, asthenia, anorexia, leukocytosis, and an elevation of acute phase reactants.[1, 2] The lesions can be diffused (von Zumbusch type) or adopt a ring-shaped or polycyclic pattern, both clinical forms overlapping in many occasions.

It can sometimes be complicated with over-infection, hypoalbuminemia, and internal organ involvement.[3]

### Case report

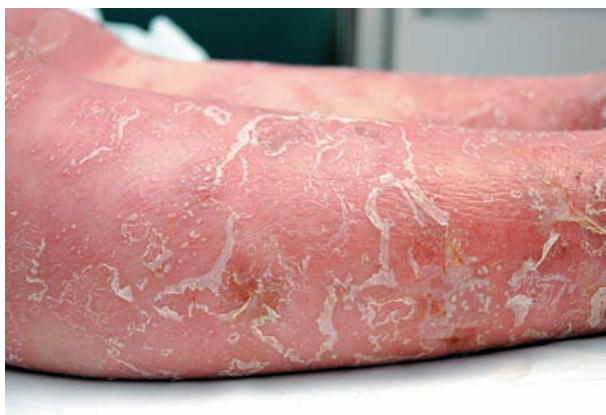A 49-year-old female patient, with schizophrenia for 12 years and undergoing treatment with fluphenazine and biperiden, presenting vulgar psoriasis with a duration of years, with lesions located in the scalp and extension areas. She was admitted for a schizophrenic episode and hypertension symptoms, ziprasidone (antipsychotic), amlodipine, captopril and hydrochlorothiazide being added to her usual medication. Fifteen days after her admission, the patient started having febricula, general discomfort and generalized skin lesions consisting of large erythematous-edematous



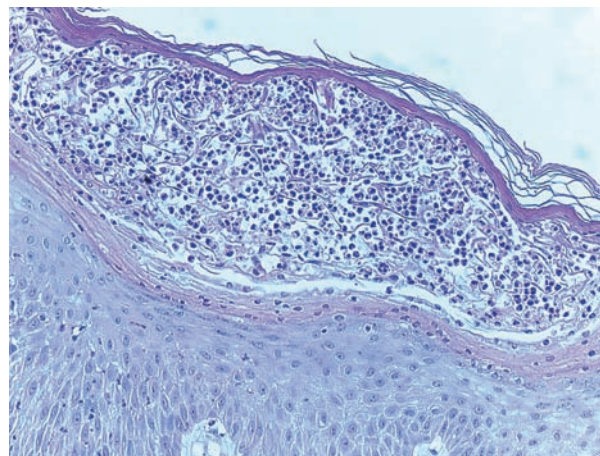
**Figure 1.** Generalized erythematous-edematous plaques with sterile pustules.

plaques, some of them with a ring-shaped arrangement, on which there were multiple sterile pustules (Figure 1). The more developed lesions had a desquamative centre with pustules on the edges of the plaque (Figure 2). Psoriasiform erythematous desquamative plaques on her scalp and at the nail level, thickening of the plate, ridging and limited oil droplets were also observed. There was no evidence of an effect on mucous membranes or of the presence of geographic tongue which are normally associated to this form of psoriasis.

Supplementary tests showed leukocytosis with left shift and an elevation of acute phase reactants, the remaining hematological and biochemical parameters being normal. The blood cultures, chest X-ray and serology for hepatotropic viruses and HIV, as well as the Mantoux test, were normal or negative. The biopsy of one of the lesions confirmed the presence of subcorneal psoriatic spongiform pustules (Figure 3).



**Figure 2.** Detail of the pustules.

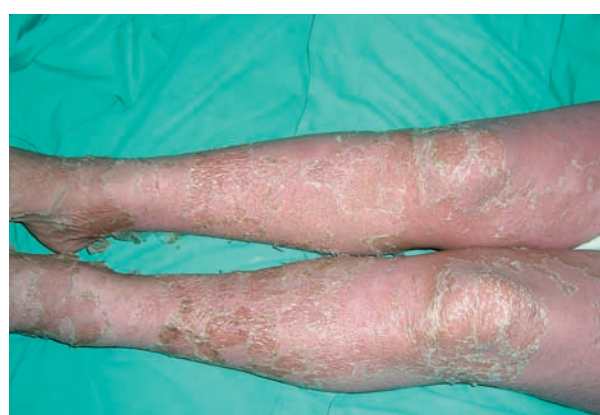

**Figure 3.** Extensive subcorneal spongiform pustule (H&E 200x).

The decision was made to withdraw the last prescribed drug regimens because they were considered to be possible pustular outbreak triggers, and treatment with 50 milligram etanercept administered subcutaneously twice a week was started. The pustules disappeared in 3 days, only erythema and desquamation persisting but they were completely resolved in 10 days (Figure 4). The systemic symptoms also remitted a week later. This etanercept dose was maintained for two weeks and the patient is currently asymptomatic with a 25 milligram maintenance dose twice a week.

## Comment

Irritant substances, drugs, infections, contraceptives, pregnancy, hypocalcemia, lithium, coal tar and the suspension of oral corticotherapy have been described as pustular outbreak triggers (2). In this patient, the cutaneous symptoms



**Figure 4.** Resolution of lesions after treatment with etanercept.

started after introducing ziprasidone and antihypertensives. [4] Ziprasidone, a drug which is not described as an inducer of this type of psoriasis, could also have acted as an outbreak trigger, therefore, its withdrawal is considered appropriate.

Tumor necrosis factor (TNF) has an essential role in the physiopathology of psoriasis. The psoriatic lesion is characterized by the presence of activated T cells, abnormal keratinocyte proliferation, excessive production of TNF and other proinflammatory cytokines and chemokines.[5-7] Etanercept acts by competitively inhibiting the interaction of TNF with its cell surface receptors, and it binds to soluble TNF, preventing the proinflammatory response mediated by this cytokine from occurring.[7-9] Anti-TNF drugs are being used in moderate-severe plaque psoriasis with good results.[5, 6] There are several publications[10-14] in which acute generalized pustular psoriasis has been treated with the anti-TNF drug infliximab, obtaining in all cases a quick (48-72 hours), complete response without any significant side effects. Although Trent and Kerdel[13] start treatment with infliximab until the outbreak is controlled, they continue with etanercept as maintenance medication in two of their patients without any recurrence of their disease. Kamarashev et al.[15] publish an excellent response to etanercept in a generalized pustular outbreak induced by the suspension of cyclosporine, obtaining a quick improvement of the cutaneous lesions and systemic symptoms.

In this patient, the decision was made to use a biological anti-TNF drug based on the excellent responses obtained by other authors with infliximab[10-14] and etanercept.[15] This therapy is preferred to other classic treatments because the patient's schizophrenia made compliance with a daily oral therapy or phototherapy difficult. The patient's hypertension also contraindicated the use of cyclosporine. In the same way, etanercept was chosen instead of infliximab due to its subcutaneous administration, because the patient's psychosis entailed a risk for an intravenous medication requiring slow infusions of up to 2 hours.

## Conclusion

Biological treatments are very interesting in severe forms of psoriasis, both due to their quickness and their response efficacy compared to classic therapies.[5, 6] The use of an anti-TNF drug has been considered to be appropriate in this type of psoriasis due to its dosage convenience and its quick and effective response with hardly any side effects.[16] Etanercept, a drug administered subcutaneously, could also be used in acute generalized pustular forms either as an initial therapy or, as indicated by Trent and Kerdel,[13] as maintenance therapy after having controlled the outbreak with infliximab.

## Bibliografía

1. Von Zumbusch LR. Psoriasis und pustulöses Exanthem. *Arch Dermatol Syph* 1910; 99: 335-46.
2. Zelickson BD, Muller SA. Generalized pustular psoriasis. A review of 63 cases. *Arch Dermatol* 1991; 127: 1339-45.
3. García-Doval I, Peteiro C, Toribio J. Mortalidad en pacientes psoriásicos: a propósito de un caso de psoriasis pustulosa. *Actas Dermosifiliogr* 1995; 86: 363-5.
4. Ikai K. Exacerbation and induction of psoriasis by angiotensin-converting enzyme inhibitors. *J Am Acad Dermatol* 1995; 32: 819.
5. Sterry W, Barker J, Boehncke WH et al. Biological therapies in the systemic management of psoriasis: International Consensus Conference. *Br J Dermatol* 2004; 151: 3-17.
6. Gamo R, López-Estebananz JL. Terapia biológica y psoriasis. *Actas Dermosifiliogr* 2006; 97: 1-17.
7. Gottlieb AB. Psoriasis: immunopathology and immunomodulation. *Dermatol Clin* 2001; 19: 649-57.
8. Daudén Tello E, Oñate Cuchet MJ. Revisión monográfica de Enbrel (etanercept) para psoriasis y artritis psoriásica. Wyeth; 2005.
9. López-Estebananz JL. Etanercept. Estructura química, farmacocinética y mecanismo de acción. *Actas Dermosifiliogr* 2005; 96: 2-9.
10. Elewski B. Infliximab for the treatment of severe pustular psoriasis. *J Am Acad Dermatol* 2002; 47: 796-7.
11. Newlan M, Weinstein A, Kerdel F. Rapid response to infliximab in severe pustular psoriasis, von Zumbusch type. *Int J Dermatol* 2002; 41: 449-52.
12. Benoit S, Toksoy A, Brocker EB, Gillitzer R, Goebeler M. Treatment of recalcitrant pustular psoriasis with infliximab: effective reduction of chemokine expression. *Br J Dermatol* 2004; 150: 1009-12.
13. Trent JT, Kerdel FA. Successful treatment of von Zumbusch pustular psoriasis with infliximab. *J Cutan Med Surg* 2004; 8: 224-8.
14. Lewis TG, Tuchinda C, Lim HW, Wong HK. Life-threatening pustular and erythrodermic psoriasis responding to infliximab. *J Drugs Dermatol* 2006; 5: 546-8.
15. Kamarashev J, Lor P, Foster A, Heinzerling L, Burg G, Nestle FO. Generalized pustular psoriasis induced by cyclosporin A withdrawal responding to the tumor necrosis factor alpha inhibitor etanercept. *Dermatology* 2002; 205: 213-6.
16. García-Patos Briones V. Seguridad de etanercept. *Actas Dermosifiliogr* 2005; 96: 25-32.