



## Transumbilical endoscopic surgery (TUES): Another option towards scarless abdominal surgery

Jiang Fan Zhu,\* Hai Hu,\* Ying Zhang Ma,\* Man Zhu Xu,\* Jin Ling Yu\*

### Abstract

*Many researchers are showing great interest in natural orifice transluminal endoscopic surgery (NOTES) for its advantages of decreased trauma and better cosmetic results during recent years. Another option known as transumbilical endoscopic surgery (TUES) has arisen at almost the same time. We here in introduce our preliminary work in transumbilical endoscopic surgery (TUES) both in animal research and clinical date. Eight domestic pigs were submitted to transumbilical endoscopic cholecystectomy. All the gallbladders were removed successfully in the eight pigs without severe bleeding during dissection, intraoperative and postoperative complications. Postmortem examination revealed that the gallbladder fossa was clean, the clips on the cystic duct and artery were secure, and that neither bile nor blood leakage was found at the operative field. Transumbilical abdominal exploration, liver cyst fenestration, appendectomy and cholecystectomy were completed successfully in 41 cases of bleeding ascites, liver cysts, chronic appendicitis and gallbladder diseases. No postoperative bleeding or bile leakage occurred in this group of patients. We conclude that transumbilical endoscopic surgery is feasible, and would be another option for scarless abdominal surgery. TUES cholecystectomy is technically challenging. Careful selection of patients is important at the beginning period of this technique.*

**Key words:** Transumbilical, endoscopy, surgery, cholecystectomy.

### Resumen

Muchos investigadores están mostrando un gran interés en la cirugía endoscópica transluminal o a través de orificios naturales (NOTAS), debido a sus ventajas para reducir los traumas y en los mejores resultados cosméticos o estéticos que se han obtenido durante los años recientes. Al mismo tiempo, ha surgido otra opción, conocida como cirugía endoscópica transumbilical (CETU). De aquí en adelante, nosotros presentamos nuestro trabajo sobre la cirugía endoscópica transumbilical (CETU), tanto a partir de la investigación sobre animales como así también los datos clínicos. Ocho cerdos domésticos se sometieron a colecistectomía endoscópica transumbilical. Se extrajeron exitosamente todas las vesículas biliares de los ocho cerdos sin haber un sangrado serio durante las disecciones, ni tampoco hubo complicaciones intraoperatorias o postoperatorias. El examen post-mortem reveló que las fosas de las vesículas biliares estaban limpias, los ganchos sobre los conductos císticos y las arterias eran seguros, y que además no se presentó drenado alguno de bilis o de sangre en el campo operatorio. La exploración abdominal transumbilical, la fenestración de los quistes hepáticos, la apendicectomía y la colecistectomía se completaron exitosamente en 41 casos de ascitis sangrante, fenestración de quistes, apendicitis crónica y enfermedades vesiculares. No ocurrió en este grupo de pacientes ningún sangrado postoperatorio o fuga o derrame de bilis. Concluimos que la cirugía endoscópica transumbilical es factible y debería constituirse en otra opción para la cirugía abdominal sin cicatrices. La colecistectomía CETU es técnicamente desafiante. Es importante una cuidadosa selección de los pacientes durante el periodo inicial de esta técnica.

**Palabras clave:** Transumbilical, endoscopia, cirugía, colecistectomía.

### TUES

With advances in the field of minimally invasive surgery, there has been an evolution in endoscopic therapy - natural orifice transluminal endoscopic surgery (NOTES). Many endoscopic physicians are showing great interest in this new technique. The major publications on NOTES during recent years include tubal ligation, gastrojejunostomy, splenectomy, cholecystectomy and so on, based on animal surgeries.<sup>1-3</sup> However, few clinical reports have appeared to date. The major barriers that limit clinical application include access, closure, infection, suturing technology and orientation.<sup>4</sup>

\* Department of General Surgery, East Hospital of Tongji University, Shanghai, China.

#### Correspondence:

**Jiang Fan Zhu, M.D. Professor of Surgery**

Department of General Surgery, East Hospital of Tongji University 150 Ji Mo Road, 200120 Pudong, Shanghai, China  
Phone: +86 3880 4518-8444  
Mobile: +86 138 1691 9763  
E-mail: zhujiangfan@hotmail.com

Considering the limitations to NOTES, another option known as transumbilical endoscopic surgery (TUES) has arisen. On May 21 2007, we successfully completed our first TUES surgery, transumbilical endoscopic liver cyst fenestration using a standard flexible endoscope, followed by TUES endoscopic abdominal exploration and appendectomy.<sup>5</sup> A tri-channel trocar was developed later, through which a 5 mm laparoscope and two semi-rigid instruments similar with those used in standard endoscopic therapy can be allowed to pass. We also developed the instruments suitable for transumbilical surgery, which include dissector, grasper and hook. It becomes possible to perform more complicated procedures with the newly developed instruments. An animal research on TUES cholecystectomy with the tri-channel trocar technique was conducted in the porcine model.<sup>6</sup> Transumbilical endoscopic cholecystectomy was completed by both tri-channel trocar and umbilical double trocar technique. Better abdominal cosmetic results were obtained after the reconstruction of the umbilicus.

### SPECIAL INSTRUMENTS

The tri-channel trocar (Yida Medical Device Co. Ltd., Hangzhou, China) was developed for this procedure, which consists of a typical trocar (15 mm in diameter) used in laparoscopic surgery and a shaft which can be inserted into the cannula sleeve when the abdominal wall puncture is completed. There are three channels— one 5 mm and two 2.8 mm in diameter— in the shaft, allowing a 5 mm laparoscope and two semi-rigid instruments to be inserted through the channels respectively (*Figure 1*).

The semi-rigid instruments with 60 cm in length and 2.8 mm in diameter were developed for this research, which include a grasper, dissector, hook, scissor and irrigation tube (Wilson Instruments CO. Ltd., Shanghai, China). The shape of the instruments is similar to the typical ones used in ordinary laparoscopic surgeries except for the semi-rigid shaft, which allows them to be inserted into the two close channels on the trocar and be manipulated easily at the same time. The hook was connected with a monopolar cautery generator (Valleylab, Boulder, USA), which was used in dissecting the gallbladder. A mini grasper with 25 cm in length and 2.0 mm in diameter (U.S. Surgical, Norwalk, CT, USA) was used to grasp the gallbladder. A rotatable clip fixing device (HX-50R-1) and clips (HX-600-090) (Olympus optical co., Ltd. Tokyo, Japan) were used to clip the cystic duct and arteries.

### FEASIBILITY STUDY FOR TUES CHOLECYSTECTOMY

#### Animal preparation

Eight domestic pigs weighing 30–38 kg were submitted to transumbilical endoscopic cholecystectomy. The animals

were fasted except for water for 12 hours before operation. On the day of operation, they were premedicated with intramuscular atropine (0.04 mg/kg) and ketamine (20 mg/kg). Animals were placed in a supine position, and Pentobarbital (20 mg/kg) was administered for induction of anaesthesia after an intravenous line was started. The pigs were intubated with an endotracheal tube and received isoflurane (2%) for maintenance of anaesthesia. Blood samples for blood count and biochemical analysis were drawn pre- and postoperatively. The heart rate, blood pressure, operative blood loss, volume of infused fluids and operative time were recorded intraoperatively.

### SURGICAL TECHNIQUE

After establishment of pneumoperitoneum by the standard Veress needle technique, the tri-channel trocar was placed through an infra-umbilical incision. The shaft with three channels was inserted into the cannula sleeve of the trocar. A 5 mm laparoscope was placed through the 5 mm channel. The abdominal cavity was inspected laparoscopically. A fine grasper of 2 mm in diameter was inserted through a small skin incision on the right upper abdomen into abdominal cavity. The floppy hepatic lobe covering the gallbladder was turned upward and the fundus of the gallbladder was lifted by the grasper. The semi-rigid grasper and hook were passed through channels on the shaft inserted into the cannula sleeve of the trocar.

Dissection of the cystic duct was carried out carefully by using a semi-rigid hook while the gallbladder was grasped with forceps (*Figure 2*). A dissector was used to further separate the cystic duct and artery. Once the cystic duct and artery were dissected free and were clipped by the clip fixing device used in ordinary endoscopic treatment (*Figure 3*). The gallbladder was pulled upward to expose the gallbladder bed, and it was then separated from the liver by using the hook dissection. The bleeding on the gallbladder bed was coagulated and the operative field was irrigated and suctioned by a flexible suction tube. The specimen was extracted through the umbilical trocar. The infra-umbilical incision was closed and the natural scar of the umbilicus was restored by subcuticular stitches.

### POSTOPERATIVE MANAGEMENT

Three animals were sacrificed following the operations immediately and five were keeping alive for one week postoperatively. Postmortem examinations were carried out for the three sacrificed animals after operations and the operative site was inspected to check the clip secure and blood or bile leakage. The other five pigs kept alive were fed for one week. A regular diet was resumed within 24 h after the procedure. A subcostal incision was made under general anesthesia to find evidence of adhesion formation,

abscess, clip secure or bile leakage in the abdominal cavity 7 days postoperatively.

## RESULTS

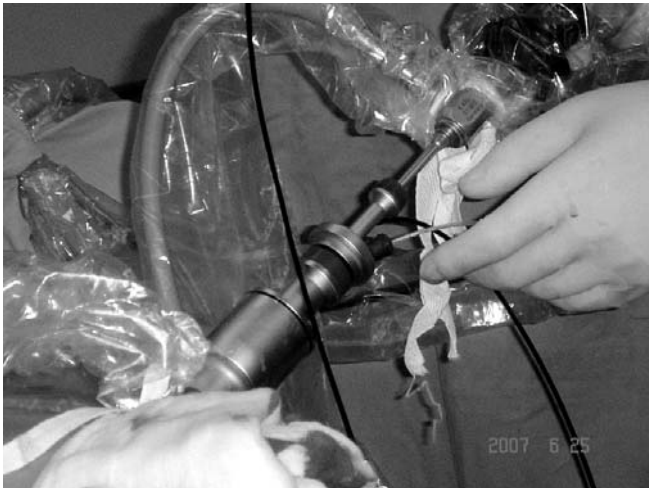The time for the operations ranged from 90 to 150 minutes ( $113.5 \pm 20.3$ ) and it decreased with experience. Intraoperative blood loss was 3.0 to 25mL ( $13.0 \pm 10.7$  mL). All the gallbladders were removed successfully without severe bleeding during dissection, intraoperative and postoperative complications, including one case whose gallbladder was attached to the left liver lobe. The gallbladder wall was perforated by cautery in two animals and the operative field was suctioned after the specimens were removed. Post-

mortem examination revealed that the gallbladder fossa was clean in six pigs and adhesion had formed in the two cases whose gallbladder walls were perforated during dissection. The clips on the cystic duct and artery were secure and that neither bile nor blood leakage was found at the operative site (Figure 4).

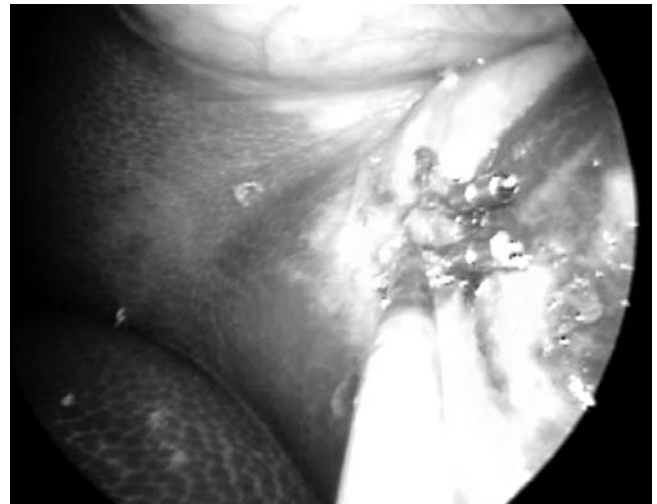## PRELIMINARY CLINICAL EXPERIENCE

### Clinical data

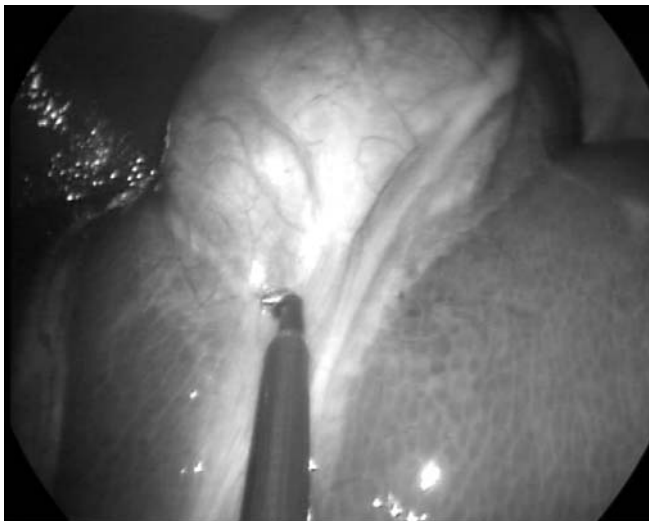From May 2007 to February 2008, 41 cases of TUES procedures were performed in our hospital. There were 18 men and 23 female with a mean age of 46 years (range: 18-65), which include 3 cases of liver cyst, 2 bloody ascites, 10 chronic appendicitis and 26 gallbladder diseases (22 gallstones and 4



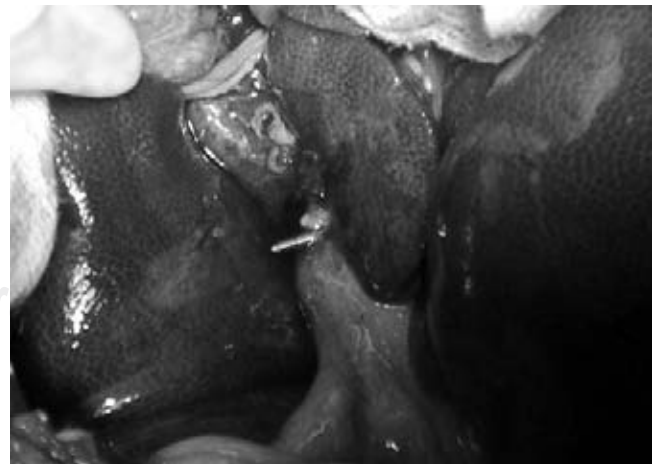
**Figure 1.** The tri-channel trocar is placed through the umbilical incision. A 5mm laparoscope and two flexible instruments are inserted into the working channels.



**Figure 3.** The cystic duct is clipped and dissected by the hook.



**Figure 2.** The semi-rigid hook is used to dissect the cystic duct.



**Figure 4.** Post mortem examination reveal that the gallbladder fossa is clean and the clips on the cystic duct is secure. Neither bile nor blood leakage is found at the operative site.

polyps in gallbladder). All the patients signed informed consent. Transumbilical endoscopic liver cyst fenestration, abdominal exploration, appendectomy and cholecystectomy were performed respectively. One case of liver cyst fenestration, abdominal exploration and appendectomy were performed by using an ordinary endoscope and instruments passed through the 12 mm trocar placed transumbilically. Two cases of liver cyst fenestration, 9 appendectomy and 6 cholecystectomy were completed by using the tri-channel trocar approach. Twenty cases of cholecystectomy were performed by umbilical double trocar technique.

## **SURGICAL TECHNIQUE**

### **Transumbilical endoscopic liver cyst fenestration**

One case was completed by using the ordinary endoscope (Olympus GIF 160, Tokyo, Japan) with one operating channel inserted through an umbilical trocar (12 mm in diameter). The cyst was located at the roof of the liver with the size of 15 × 12 cm. The cystic wall was dissected by a hot biopsy forceps passed through the working channel of the endoscope, assisted by a grasping forceps inserted through a 5 mm trocar at the right upper abdomen which was used as passage for a drain after deroofting of the cyst. The specimen was extracted by a grasper in the endoscope through the umbilical trocar. Two cases were performed by the tri-channel trocar technique. The trocar was placed through the infra-umbilical incision after establishment of pneumoperitoneum. A 5 mm laparoscope, 2.8 mm semi-rigid grasper and hook were inserted through the working channels in the inner shaft of the trocar. The cystic walls were opened by the monopolar cautery assisted by the grasper. Drainage tubes were not placed because the cystic fluid was very clear. The umbilicus was reconstructed without leaving visible scars on the abdomen after the operations.

### **TRANSUMBILICAL ENDOSCOPIC ABDOMINAL EXPLORATION**

Case 1: The endoscope was inserted through the umbilical 12 mm trocar after establishment of pneumoperitoneum. Bloody ascites was suctioned through the working channel of the endoscope. Cystic peritoneum contusion was detected. The focus was coagulated and hemostasis achieved.

Case 2: The patient was admitted for undefined ascites. Laparoscopic inspection found the tubercles were distributed on all the abdominal peritoneum. A biopsy was performed by using a hook passing through the transumbilical trocar. The diagnosis of abdominal tuberculosis was confirmed pathologically.

### **TRANSUMBILICAL ENDOSCOPIC APPENDECTOMY**

The abdominal cavity was explored first by an endoscope inserted through the umbilical trocar or a 5 mm laparo-

scope through the tri-channel trocar. The cecum was retracted and the appendix was exposed. The peri-appendix adhesion was dissected. The appendix was extracted through the umbilicus incision and resected extracorporeally. The pneumoperitoneum was reestablished. The appendix stump was inspected again to confirm it was well ligated. The umbilicus was reconstructed.

## **TRANSUMBILICAL ENDOSCOPIC CHOLECYSTECTOMY**

### **Tri-channel trocar technique**

The tri-channel trocar was placed transumbilically after establishment of pneumoperitoneum. A 5 mm laparoscope, a 2.8 mm semi-rigid grasper and hook connected with a monopolar cautery generator were passed through the working channels in the inner shaft of the trocar. A mini grasper with 25 cm in length and 2.0 mm in diameter (U.S. Surgical, Norwalk, CT, USA) was inserted through a small skin incision on the right upper abdomen into abdominal cavity for grasping fundus of the gallbladder. Dissection of the cystic duct was carried out carefully by using the semi-rigid hook while the gallbladder was grasped with the forceps. A dissector was used to further separate the cystic duct and artery. Once the cystic duct and artery were dissected free and were clipped by the clip fixing device used in ordinary endoscopic treatment. The gallbladder was pulled upward to expose the gallbladder bed, and it was then separated from the liver by using the semi-rigid hook dissection. The bleeding on the gallbladder bed was coagulated and the operative field was irrigated and suctioned by a flexible suction tube. The specimen was extracted through the umbilical trocar. The infra-umbilical incision was closed and the natural scar of the umbilicus was restored by subcuticular stitches.

### **UMBILICAL DOUBLE TROCAR TECHNIQUE**

A 1.5 cm infra-umbilicus skin incision was made and pneumoperitoneum was established by using a Veress needle. Two 5 mm trocars were placed along the skin incision. A 5 mm laparoscope and an ordinary 5 mm instrument (a dissector, hook or harmonic scalpel) were passed through the two trocars respectively. The mini grasper was inserted through a small skin incision on the right upper abdomen into abdominal cavity for retracting the gallbladder (Figure 5). The Calot's triangle was dissected by the hook and the cystic duct was freed. The cystic artery was coagulated by the harmonic scalpel. The gallbladder was dissected from the liver bed. An endoloop (Johnson & Johnson Medical Ltd., China) was used to ligate the cystic duct, which was cut by the harmonic scalpel. The gallbladder was put into a plastic bag and extracted from the umbilical incision.



## RESULTS

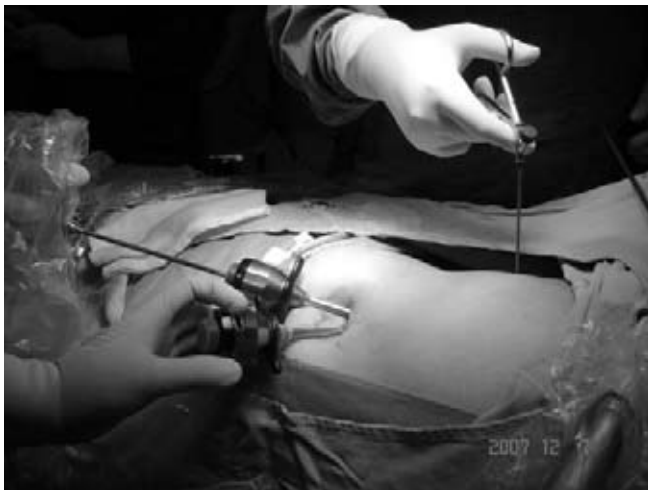One case of transumbilical cholecystectomy by double trocar technique was converted to routine laparoscopic operation due to uncontrollable intraoperative bleeding. Other procedures were completed successfully without obvious hemorrhage. The mean operating times were  $45 \pm 37$  min (range 30 - 150 min) for transumbilical cholecystectomy and  $35 \pm 16$  min (range 15 - 40 min) for appendectomy. One case of liver cyst fenestration performed by using the ordinary endoscope took 90 min, whereas the operating time in two cases by using the tri-channel trocar technique was 30 and 45 min respectively. All patients felt well after the operation without need for postoperative analgesia and resumed free oral intake 6 h after the procedure. All patients were discharged 48 h after the operation. Evaluation in outpatient department showed a good clinical course in every case one month postoperatively. Better cosmetic results were obtained on the abdomen compared with the routine laparoscopic technique (*Figure 6*).

## FUTURE POSSIBILITIES

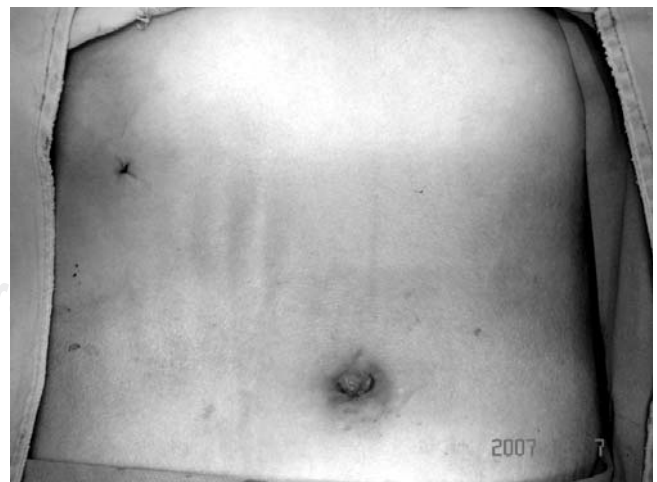During recent years, new interest has arisen in scarless endoscopic abdominal surgery with the development of technique in minimally invasive surgery. The new concept known as natural orifice transluminal endoscopic surgery (NOTES) has appeared since the publication of the first experimental report by Kalloo et al.,<sup>7</sup> which concluded that it was feasible to access the peritoneal cavity through peroral transgastric approach and offered the potential for a wide range of endoscopic surgery with the possible advantages of improved patient recovery, reduced need for anesthesia, and better cosmetic results.

More studies in NOTES technique have been performed including tubal ligation, cholecystectomy, splenectomy and so on, based on animal surgeries.<sup>2-4</sup> Marescaux et al. from Strasbourg University Hospital reported their first transvaginal endoscopic cholecystectomy on April 2, 2007.<sup>8</sup> The major publications on clinical NOTES procedures are transvaginal surgeries up to now.<sup>9,10</sup> Many endoscopic physicians are showing great interest in this new technique. However, few clinical reports have appeared to date. The major barriers that limit clinical application include access, closure, infection, suturing technology and orientation.<sup>1,4</sup>

Since the limitation exists in NOTES, TUES may be another option in trying scarless abdominal surgery. Single port transumbilical appendectomy has been described in literature. Usually a rigid laparoscope with a working channel was used in this technique. The appendix was pulled out from the umbilical port by the grasper inserted through the channel and removed extracorporeally.<sup>11,12</sup> Cuesta et al.<sup>13</sup> recently introduced transumbilical scarless cholecystectomy for 10 patients with gallstones. Two 5 mm trocars were introduced parallel to each other through an umbilical incision. A 5 mm laparoscope and instrument were used to dissect the gallbladder which was grasped by a 1-mm Kirschner wire introduced at the subcostal line. The author concluded that the umbilicus can be developed as a natural port for performing various operative procedures with better cosmetic result. A rigid instrument may be more easily maneuvered than a flexible one, but the fundus of the gallbladder is fixed by the Kirschner wire according to Cuesta's approach. It would be difficult to dissect the gallbladder by one instrument. Zornig et al.<sup>14</sup> described another hybrid technique, combined transvaginal and transumbilical cholecystectomy for a patient with gallstones. Conventional laparoscopic instruments and technique are used in this pro-



**Figure 5.** The two 5 mm trocars placed along the infra-umbilicus incision and the mini grasper inserted on the right upper abdomen.



**Figure 6.** Better abdominal cosmetic results after TUES cholecystectomy.

cedure, which provides a chance to optimize cholecystectomy in selected cases, without help from endoscopic specialties. Of course, this technique is limited only to female patients. Another variant of TUES cholecystectomy by using a flexible double channel endoscope was reported by Palanivelu et al<sup>15</sup> recently. The routinely used endoscopic instruments including grasping forceps or snare, hot biopsy forceps and endo-clips were used in this procedure. A 3-mm rigid transcutaneous trocar was placed in the left hypochondrium for liver retraction. The procedure was attempted in 10 well selected young patients, among whom 4 cases had to be converted to conventional laparoscopic cholecystectomy due to difficulty in dissection or uncontrollable hemorrhage. Cystic duct leak occurred in one patient who was successfully treated by endoscopic retrograde cholangiopancreatography with stenting. The author concluded that the results were not satisfied and the instruments need to be further improved. Transumbilical endoscopic cholecystectomy by using the flexible double channel endoscope should be easier than NOTES technically. But apparently, the flexible instruments are difficult to manipulate compared with the rigid laparoscopic instruments. Therefore, the umbilical double trocar technique could be the better choice.

On May 21 2007, we successfully completed our first TUES surgery: transumbilical endoscopic liver cyst fenestration using a standard flexible endoscope, followed by endoscopic abdominal exploration and appendectomy.<sup>5</sup> A tri-channel trocar was developed later, through which a 5 mm laparoscope and two semi-rigid instruments similar to those used in standard endoscopic therapy can be allowed to pass. The instruments suitable for transumbilical endoscopic surgery were developed, which include dissector, grasper and hook. We then completed transumbilical endoscopic cholecystectomy, both by tri-channel and umbilical double trocar technique, a modified Cuesta's procedure. The advantage of tri-channel trocar procedure is that two instruments can be used at the same time which is similar with a double channel endoscope. The adhesion around the appendix can be dissected by the semi-rigid hook assisted by another instrument, then the appendix can be easily pulled out of the abdomen and resected extracorporeally in transumbilical appendectomy. In liver cyst, deroofting can be completed by this technique without additional assisting

instrument in the upper abdomen if the cystic contents are clear and drainage is not considered in advance. Virtually no scar will be left on the abdomen when the umbilicus is reconstructed after the operations. In our series of patients, the right upper abdomen port is necessary for grasping the fundus of the gallbladder both in tri-channel trocar or umbilical double trocar techniques, which could be replaced by a magnetic anchored system.<sup>10,16</sup> Laparoscopic surgeons are used to using rigid instruments, which are stronger in retraction, dissection or assisting exposure compared with the semi-rigid instruments used in tri-channel trocar technique. So the umbilical double channel approach is easier than the tri-channel technique in transumbilical endoscopic cholecystectomy. Another advantage in the umbilical double channel technique is that the harmonic scalpel can be passed through the 5 mm trocar, hence more complicated procedures can be performed by this technique.

Compared with NOTES, TUES would be easier technically. There is almost no visible scar on the abdomen when the umbilicus is reconstructed. The brightness of a 5 mm laparoscope is much better and the orientation is more easily controlled than a routinely used endoscope. The instruments we developed for tri-channel trocar technique are shorter and with handles which are suitable for surgical maneuver. Dissection with the semi-rigid hook is easier and much more accurate than an endoscopic needle knife. Of course, TUES is a completely new technique with great challenge, which is more difficult than conventional laparoscopic surgery and needs to be further improved. Careful selection of patients is important at the beginning period of this technique. New instruments suitable for this procedure also need to be developed.

## CONCLUSIONS

Transumbilical endoscopic surgery (TUES) is feasible technically, which would be a simple and safe approach towards scarless abdominal surgery. At present, TUES is a relatively difficult procedure compared with routine laparoscopic surgery. Careful selection of patients and training are necessary. TUES will be widely used as the technique is further improved and new instruments suitable for this procedure are developed.

## REFERENCES

1. Giday SA, Kantsevov SV, Kalloo AN. Principle and history of natural orifice transluminal endoscopic surgery (NOTES). *Minim Invasive Ther Allied Technol* 2006; 15: 373-377.
2. Malik A, Mellinger JD, Hazey JW et al. Endoluminal and transluminal surgery: current status and future possibilities. *Surg Endosc* 2006; 20: 1179-1192.
3. Park PO, Bergstrom M, Ikeda K et al. Experimental studies of transgastric gallbladder surgery: cholecystectomy and cholecystogastric anastomosis. *Gastrointest Endosc* 2005; 61: 601-606.
4. Fuente SG, DeMaria EJ, Reynolds JD et al. New development in surgery: natural orifice transluminal endoscopic surgery (NOTES). *Arch Surg* 2007; 142: 295-297.
5. Zhu JF. Scarless endoscopic surgery: NOTES or TUES. *Surg Endosc* 2007; 21: 1898-1899.
6. Zhu JF, Ma YZ, Yu JL, Hu H. Transumbilical endoscopic cholecystectomy with the trichannel trocar technique: A porcine feasibility study. *Surg Innov* 2008; DOI: 10.1177/1553350608318453.

7. Kalloo AN, Singh VK, Jagannath SB, et al. Flexible transgastric peritoneo-scopy: a novel approach to diagnostic and therapeutic interventions in the peritoneal cavity. *Gastrointest Endosc* 2004; 60: 114-117.
8. Marescaux J, Dallemagne B, Perretta S et al. Surgery without scars: Report of transluminal cholecystectomy in a human being. *Arch Surg* 2007; 142: 823-826.
9. Zorron R, Maggioni LC, Pombo I, et al. NOTES transvaginal cholecystectomy: preliminary clinical application. *Surg Endosc* 2007; 21: online first.
10. Scott DJ, Tang SJ, Fernandez et al. Completely transvaginal NOTES cholecystectomy using magnetically anchored instruments. *Surg Endosc* 2007; 21: 2386-2316.
11. Koontz CS, Smith LA, Burkholder HC et al. Video-assisted transumbilical appendectomy in children. *J Pediatr Surg* 2006; 41: 710-712.
12. Pappalepore N, Tursini S, Marino N et al. Transumbilical laparoscopic-assisted appendectomy (TULAA): a safe and useful alternative for uncomplicated appendicitis. *Eur J Pediatr Surg* 2002; 12: 383-386.
13. Cuesta MA, Berends F, Veenhof AA. The «invisible cholecystectomy»: A transumbilical laparoscopic operation without a scar. *Surg Endosc* 2007; 21: online first.
14. Zornig C, Emmermann A, von Waldenfels HA et al. Laparoscopic cholecystectomy without visible scar: combined transvaginal and transumbilical approach. *Endoscopy* 2007; 39: 913-915.
15. Palanivelu C, Rajan PS, Rangarajan M, Parthasarathi R, Senthilnathan P et al. Transumbilical endoscopic cholecystectomy in humans: first feasibility study using a hybrid technique. *Endoscopy* 2008; 40: 428-431.
16. Park S, Bergs RA, Eberhart R et al. Trocar-less instrumentation for laparoscopy magnetic positioning of intra-abdominal camera and retractor. *Ann Surg* 2007; 245: 379-384.