



Rev Mex Med Forense, 2018, 3(2):47-53

ISSN: 2448-8011

Usefulness of immunohistochemistry in the diagnosis of hepatocolangiocarcinoma

Forensic Case

Estephani Mora-Morales ¹, Patricia Beatríz Denis-Rodríguez ², Guadalupe Melo Santiesteban ³, Ángel Augusto Aguirre Gutiérrez ⁴

Received: April 4, 2018, Accepted: May 3, 2018, Published: August 15, 2018

¹ Technician Histotechnologist and Embalmer, Universidad Veracruzana

² MD, Master in Forensic Medicine, PhD in Forensic Sciences, Institute of Forensic Medicine, Universidad Veracruzana

³ Forensic Pathologist, PhD in Forensic Sciences, Institute of Forensic Medicine, Universidad Veracruzana

⁴ MD, Master in Forensic Medicine, PhD in Forensic Sciences, Institute of Forensic Medicine, Universidad Veracruzana

Corresponding author: Estephani Mora-Morales, revmforense@uv.mx

SUMMARY

We present the case of a male individual, 67 years of age, with no relevant history, which presented a hepatic neoformation of 6 months of evolution. The preliminary histological interpretation was: Well-differentiated carcinoma, with 5% necrosis, 10% macrovesicular steatosis, 5% microvesicular steatosis and cirrhosis. In a complementary analysis, immunohistochemical studies were carried out to detect cytokeratin 19,

cytokeratin 7, carcinoembryonic antigen and Heppar1, being positive to the 4 mentioned tumor markers. With this, the immunohistochemistry allowed us to make the diagnosis of a Hepatocellular Carcinoma combined with Cholangiocarcinoma, entities that are not usually associated; we perform an analysis of the immunohistochemical application in cases in which the histopathological analysis can be confusing.

Keywords: *Hepatocellular carcinoma, cholangiocarcinoma.*

CASE PRESENTATION

We present the case of an individual of male sex, 67 years of age, with no relevant history, which presented a hepatic neoformation of 6 months of evolution, with apparent progressive growth; a biopsy was performed for histopathological study. Once placed in a vial with formaldehyde, three fragments of the neoformation were sent, the largest of them with a size of 1.1 x 0.5 cm and the smallest of them with a size of 0.4 x 0.3 cm; in all cases, the samples were light brown, with irregular edges and shapes, with a partially firm consistency, although the larger biopsy showed whitish areas.

Once processed and stained initially with Hematoxylin and eosin, in the sections made to the material, the

presence of a malignant epithelial lesion was detected, which showed medium caliber bile ducts, with dysplasia and cells suggestive of carcinoma, which broke the basal layer and infiltrated the stroma, with desmoplastic reaction. The rest of the lesion showed an indefinite mixture of groups of cells with hepatoid characteristics in thick trabeculae of more than two hepatocytes and cuboidal with glandular formations and secretion in their light; atypical mitoses and desmoplasia were observed, with foci of necrosis and pseudonodular areas.

Staining was performed with Masson's Trichrome and PAS, which showed fibrosis with complete nodules of hepatocytes as well as glycogen and positive secretion for SBP; staining of PAS with diastase with positive glandular

secretion for pseudoglandular lumen content.

The preliminary histological interpretation was: Well-differentiated carcinoma, with 5% necrosis, 10% macrovesicular steatosis, 5% microvesicular steatosis and cirrhosis. Immunohistochemical studies were carried out to detect cytokeratin 19, cytokeratin 7, carcinoembryonic antigen and Heppar1, being positive to the 4 mentioned tumor markers. We concluded it was a liver tumor with an immunophenotype concordant with mixed tumor (Hepatocarcinoma and Bile Duct Carcinoma).

DISCUSSION

The use of tumor markers in the diagnosis phase is greater than in the case of the early detection of cancer. It is important to clarify that, with few exceptions, the increase of a certain tumor marker is not enough to establish a definitive diagnosis; the diagnosis should be based in all cases on conventional methods, that is histology or cytology, according to the type of neoplasia.

Currently, statistics classify Hepatocolangiocarcinoma (HCC) as the main cause of mortality in people with compensated liver cirrhosis, the fifth to sixth most frequent neoplasm (500,000 to 700,000 new cases per year), with survival rates judged as very low (between 3 to 5% per year), and for this last reason is the third cause of cancer mortality on the planet.

Hepatocellular carcinoma is associated with infections, such as

hepatitis C and B. The annual incidence of hepatocellular carcinoma in carriers of hepatitis B virus (HBV) is 0.5 to 1% annually in those without cirrhosis. liver and 2.5% in those who do have cirrhosis. In contrast, HCC is an unusual form of hepatic carcinoma that shows both hepatocellular and biliary epithelial differentiation. The reported frequency of HCC is from 2.5% to 14.2% of primary liver tumors in series of autopsies. The histogenesis of this neoplasm is unclear, but some researchers have suggested that HCC originates from intermediate-type cells or progenitor cells with dual differentiation.

Despite advances in imaging techniques, early detection of these lesions remains difficult. Because the treatment of the disease when it is evolved is merely palliative; The reduction of mortality should focus on the identification of patients with risk factors and the early detection of these neoplasms, in order to obtain the highest possible resectability rates.

The Carcinoembryonic Antigen (CEA) is an oncofetal glycoprotein used as a Tumor Marker in suspicion of a tumor of the gastrointestinal tract. Unfortunately, the increase in the concentration of CEA in plasma ($> 5 \text{ ug / mL}$) rarely occurs in the early stages of the tumor, so it is usually used to determine the prognosis and evaluate the response to treatment. Its main drawbacks are the release of CEA to blood in inflammatory diseases such as hepatitis, chronic obstructive pulmonary disease or pancreatitis; and that in 15% of the tumors of the large intestine there is no increase in CEA (figure 1).

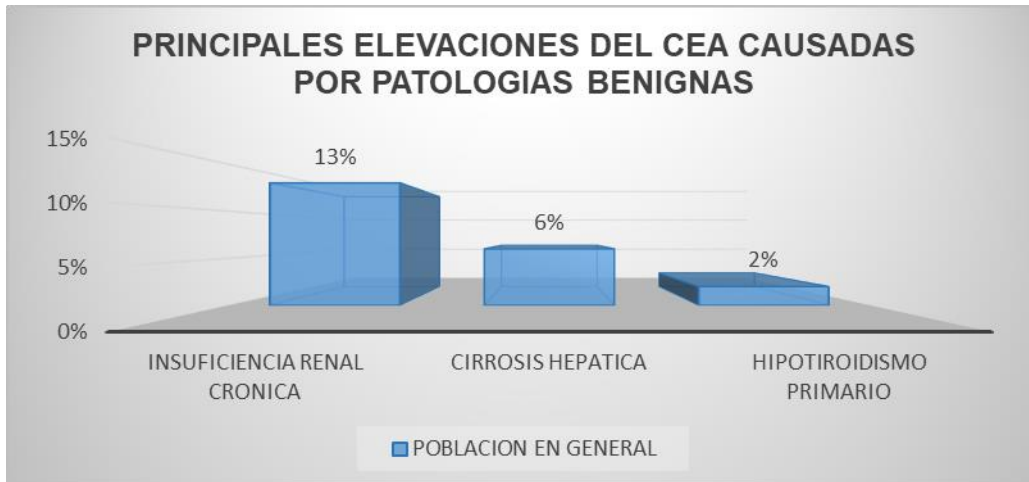


Figure 1. Non-neoplastic pathologies in which elevations of carcinoembryonic antigen may occur

The analysis of CEA concentration is not a valuable test for cancer screening because it yields a large number of false-positive and false-negative results. Post-operative testing of CEA should be restricted to patients who would be eligible for resection of metastases in the liver or lung.

The American Association of Clinical Oncology recommends the determination of CEA before surgery and every 2 or 3 months in the follow-up of an intervention with radical intention. Other tumors that elevate this marker are melanomas, lymphomas, breast cancer, lung, pancreas, stomach, cervix, bladder, kidney, thyroid, liver and ovary; its clearance is done through the liver, which is usually increased in cases of metastasis in this organ.

CEA has a sensitivity of 80% and a specificity of 70%. The determination of CEA has been shown to be more sensitive for the diagnosis of liver disease and not very sensitive for pulmonary involvement. It is exceptional to find figures above 20 ng / ml in patients who do not have a malignant condition. Values higher than 10 ng / ml usually indicate that the neoplasm has metastasized, evidently a

sign of poor prognosis and little success with respect to the possibility of total surgical resection. In this sense, patients with a malignant process and high values of CEA suffer metastasis, especially in the liver. It has been shown that ACE has no value as a screening method, since its sensitivity is low in early stages (less than 25%) and therefore it is not recommended for scrutiny.

Hepatocellular carcinoma, also known as hepatocarcinoma, is a malignant tumor of epithelial origin, derived from cells of the liver parenchyma. More than 80% of cases with hepatocarcinoma occur in patients with chronic liver diseases and liver cirrhosis. Among the main causes of liver cirrhosis in patients with hepatocellular carcinoma are Hepatitis B and C viruses as well as alcoholic liver disease. Some prospective studies have reported that once liver cirrhosis develops, the incidence of hepatocellular carcinoma is approximately 2 to 8% per year.

Cholangiocarcinomas are malignant tumors originating in the epithelium of intra- or extrahepatic bile ducts, which, due to their anatomical location, pose important technical difficulties in surgical resection. Long-

term survival is only achieved in resected cases, so it is important to identify patients with risk factors, as well as early diagnosis and assessment of resectability by a surgeon experienced in hepatobiliary surgery. It represents less than 2% of all malignant tumors of recent diagnosis. The incidence in the United States of North America is low, of 1.0 / 100,000 per year. It occurs especially after the sixth decade of life and is slightly more frequent in men than in women, in a proportion. Malignant lesions of the biliary epithelium include neoplasms of the intrahepatic, extrahepatic bile ducts of the gallbladder and the ampulla of Vater. These types of neoplasia are different from the clinical and

epidemiological point of view and, therefore, should be considered separately.

Immunohistochemistry has been used to facilitate the differential diagnosis between the combination between Hepatocarcinoma and cholangiocarcinoma, among which multiple antibodies with different sensitivities and specificities are used for hepatocarcinomas, cholangiocarcinomas and adenocarcinoma metastases. Upon detection of a high value of any marker, it is necessary to discriminate whether said elevation is due to the presence of a tumor or not. Chronic liver disease and renal failure are the two main causes of false (usually moderate) increases in tumor markers (Table 1).

MARCADOR TUMORAL	VALOR NORMAL	SENSIBILIDAD	TUMOR PRIMARIO	OTRAS NEOPLASIA
Antígeno carcino embrionario	< 2,5 ng/ml (no fumador) < 5 ng/ml (fumador)	Elevado < 25 % de cáncer de colon en estadios tempranos y en el 75 % en estadios avanzados	Cáncer de Colon	Mama, pulmón, estómago, páncreas, cabeza y cuello, hígado, linfoma, melanoma, medular de tiroides
Alfa feto proteína	< 5,4 ng/ml	Elevado 80 % carcinomas hepatocelulares y 85 % tumores de células germinales no seminomatosos	Carcinoma hepatocelular, tumores de células germinales no seminomatosos	Estómago, biliar, páncreas
CA 19.9	< 37 U/ml	Elevado 80-90 % cáncer de páncreas, 60-70 % cáncer biliar	Cáncer de páncreas, cáncer de tracto biliar	Colon, esófago e hígado

Table 1. Main tumor markers used in the detection of hepatocolangiocarcinoma

REFERENCES

1. Avilés A, Luévano A, Herrera R. Hepatocolangiocarcinoma combina

do. Presentación de un caso y revisión de la literatura. Rev Gastroenterol Mex. 2006; 71:483--6.

2. Edmondson HA, Steiner P. Primary carcinoma of the liver: a study of 100 cases among 8,900 necropsies. *Cancer*. 1954; 7: 462-503.
3. Gómez-Mateo M, Rodrigo B, Cabezas-Macián M. Hepatocolangiocarcinoma combinado. Claves para su diagnóstico anatomopatológico. *Rev Esp Patol*. 2013; 46: 73---8.
4. Hatano H, Kobayashi S, Nagano H. A case of successful multimodal treatment for combined hepatocellular and cholangiocarcinoma with portal venous tumor thrombus. *Gan To Kagaku Ryoho*. 2009; 36: 2374-6.
5. Ikeda H, Harada K, Sato Y. Clinicopathologic significance of combined hepatocellularcholangiocarcinoma with stem cell subtype components with reference to the expression of putative stem cell markers. *Am J Clin Pathol*. 2013; 140:329-40.
6. Paradis V. Histopathology of hepatocellular carcinoma. *Recent Results Cancer Res*. 2013; 190: 21-32.
7. Tejada AA, Cabrera MP, Martínez MS. Hepatocholangiocarcinoma in young patient with a giant liver tumour. *Cirugía y Cirujanos*, 2017; 85(3): 250-253.
8. Willekens I, Hoorens A, Geers C. Combined hepatocellular and cholangiocellular carcinoma presenting with radiological characteristics of focal nodular hyperplasia. *World J Gastroenterol*. 2009; 15: 3940-3.
9. Yano Y, Yamamoto J, Kosuge T. Combined hepatocellular and cholangiocarcinoma: a clinicopathologic study of 26 resected cases. *Jpn J Clin Oncol*. 2003; 33: 283---7.
10. Zhou Y-M, Zhang X-F, Wu L-P. Risk factors for combined hepatocellular-cholangiocarcinoma: a hospital-based case-control study. *World J Gastroenterol*. 2014; 20: 12615---20.

