

Vertebral-subclavian bifurcation treatment. “The wedding ring technique” for a vertebral in-stent restenosis associated with stent fracture

Félix Damas-De Los Santos^{1*}, Federico Colombo², Andrea Zuffi³ and Alberto Cremonesi⁴

¹Interventional Cardiology Department, Instituto Nacional de Cardiología Ignacio Chavez, Mexico City, Mexico; ²Interventional Cardiology Department, Ospedale Maggiore di Milano, Milan, Italy; ³Interventional Cardiology Department, Centre Hospitalier Universitaire Vaudois CHUV, Lausanne, Switzerland; ⁴Interventional Cardio-Angiology Department, GVM Care and Research, Cotignola, Ravenna, Italy

Abstract

This report describes a solution for a restenosis and for the fracture of a stent in the vertebral artery in a patient suffering from vertebrobasilar symptoms. Angiography demonstrates restenosis of a vertebral stent as well as its fracture and migration into the subclavian artery. This complication was managed percutaneously by passing a guide wire through the fractured stent. Pre-dilatation and kissing balloon techniques were applied in both the vertebral and subclavian arteries to modify the stent's dimensions and shape it into the form of a “ring.” Postprocedural angiography demonstrated an excellent final result with the assistance of StentBoost visualization. Control angiography at six months also utilized StentBoost imaging and confirmed the patency of the bifurcation and that the stent was not displaced.

KEY WORDS: Vertebral. Bifurcation. Stent. Fracture. Technique.

Resumen

Este reporte muestra la solución para la reestenosis y fractura de un stent en la arteria vertebral (VA), en un paciente con síntomas vertebrobasilares. La angiografía diagnóstica mostró reestenosis del stent vertebral, fractura y migración de este dentro de la arteria subclavia. Esta complicación fue manejada por vía percutánea, al pasar una guía dentro del stent fracturado. Se llevó a cabo predilatación y kissing balón de la VA y arteria subclavia, para modificar la dimensión y forma del segmento de stent fracturado y migrado, dándole la forma de un anillo. La angiografía posterior con stent boost mostró un buen resultado angiográfico final. Se repitió la angiografía de control a los 6 meses con stent boost que confirmó la permeabilidad de la bifurcación y no modificaciones en el stent. (Gac Med Mex. 2015;151:655-9)

Corresponding author: Félix Damas-De Los Santos, damasdelossantos@yahoo.com.mx

PALABRAS CLAVE: Bifurcación vertebral-subclavia. Stent. Fractura. Técnica.

Correspondence to:

*Félix Damas-De Los Santos
Interventional Cardiology Department
Instituto Nacional de Cardiología “Ignacio Chavez”
Juan Badiano, 1 - second floor
Col. Sección XVI, Del. Tlalpan
C.P. 14080, México, D.F., México
E-mail: damasdelossantos@yahoo.com.mx

Fecha de recepción: 06-09-2014

Fecha de aceptación: 28-12-2014

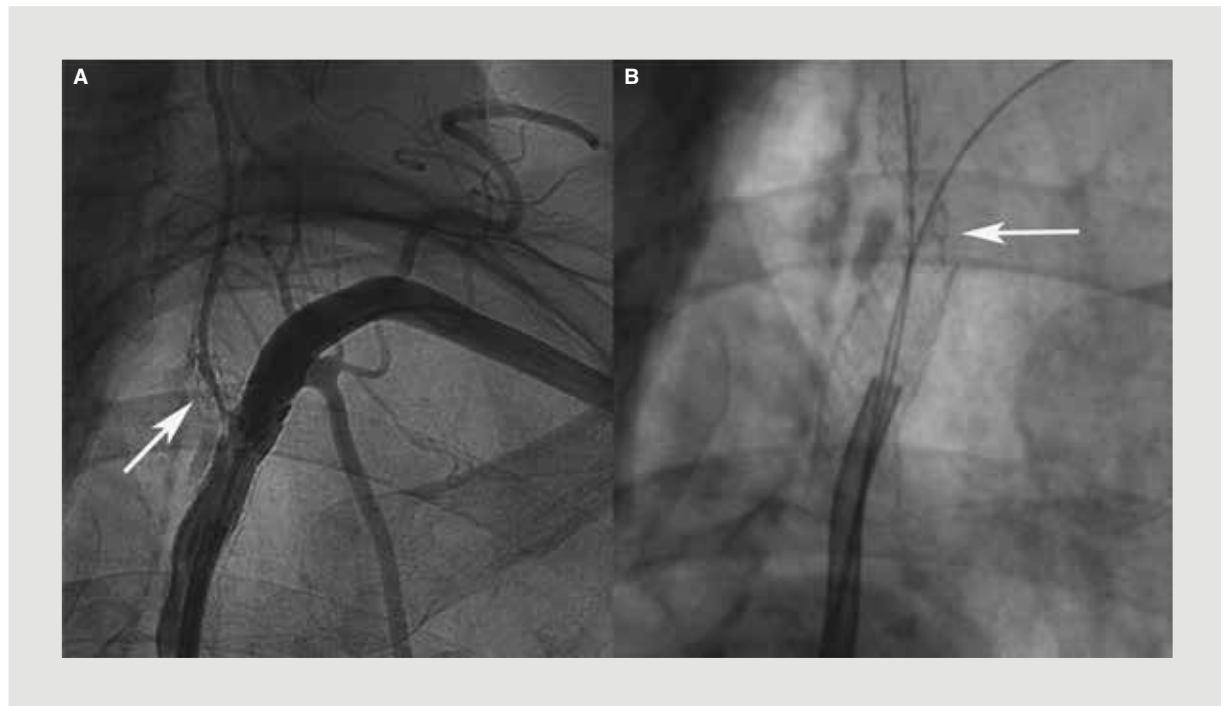


Figura 1. A: Diagnostic angiography, critical restenosis in the vertebral artery (arrow) and middle hyperplasia in the subclavian artery. **B:** In the image without contrast, a fractured vertebral stent lodged in the subclavian artery may be seen (arrow).

Background

For patients experiencing vertebrobasilar transient ischemic attacks, vertebral artery (VA) stenosis portends a 22-35% stroke risk over five years¹. Angiographic and necropsy studies demonstrate that the first 1-2 cm of the proximal extracranial segment of the vessel is the most frequent site of VA stenosis². Following endovascular treatment, the rate of major stroke or death after 30 days is 3.2%^{3,4}, but the rate of periprocedural stroke has reached 7.3%⁵ in selected series. The SSYLVA group reported a 6.6% prevalence of post-procedural stroke, but it is not clear how many of these strokes occurred within the vertebrobasilar territory. Additionally, the risk of stroke between 30 days and one year following treatment was 7.3%. The subgroup of vertebral artery stenosis included in the CAVATAS study shows that the degree of mean vessel stenosis at follow up was 47%⁶. The endovascular procedure is not free from long-term complications. The rate of in-stent restenosis varies between 30 and 43%^{7,8}. It has been associated with stent fracture in selected series at follow-up. In a Japanese series involving patients treated with coronary stents, a fractured stent was detected in 50% of cases⁹. StentBoost is a decompilation

of acquired images of two fixed markers (balloons) that have been recompiled into a highlighted still image using the same markers. This case report details the unusual behavior of a previously deployed stent at the location of a previously diagnosed VA stenosis, and aims to demonstrate a technique of approaching the lesion, controlling the stent, and subsequently visualizing the stent at follow-up using StentBoost imaging.

Case report

A 68-year-old female patient presented to our facility with a history of smoking, arterial hypertension, and mild stenosis of the right and left internal carotid arteries. She had undergone an angioplasty of the left common iliac artery in 2007, as well as an angioplasty with stent placement in the left subclavian (SC) and VA in 2008. In July 2008, following the return of vertiginous symptoms, a follow-up evaluation utilizing Doppler technology showed increases in the systolic peak velocity of the VA. The subsequent procedure was initiated utilizing a femoral approach. Diagnostic angiography was performed using a Judkins right 5 Fr guiding catheter, the preferred device of the authors because it facilitates the use of multiple guide wires and simultaneous injections when navigating the challenging anatomy of the aortic arch.

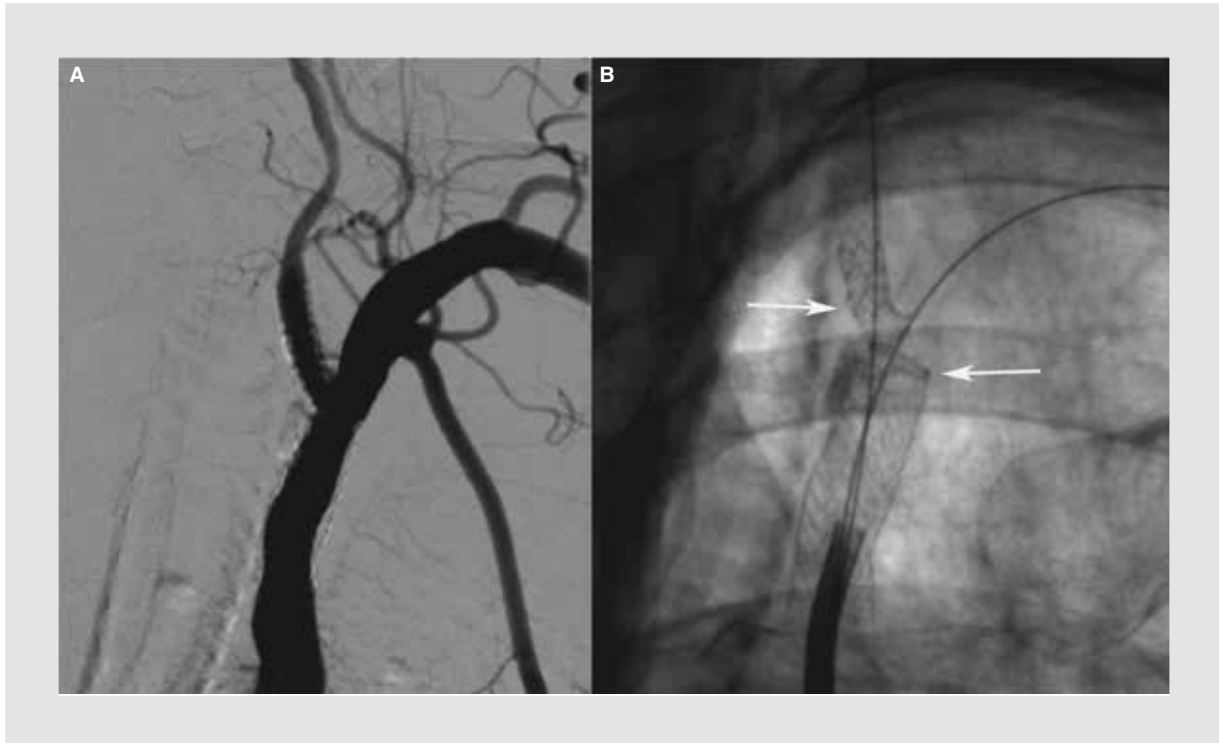


Figure 2. **A:** Digital subtraction angiography showing complete stenosis resolution and confirmation of a new bifurcation. **B:** The image showing the segment where the fractured stent was located has been completely reconstructed. The vertebral artery ostium is covered by a drug-eluting stent (upper and right arrow), and the fractured stent is dilated and attached to the arterial wall, having taken the shape of a ring (lower and left arrow).

Initial angiographic images revealed in-stent restenosis within the vertebral artery, as well as the image of a fractured vertebral stent, which had apparently been dislodged into the lumen of the SC artery (Fig. 1). We subsequently placed a 0.0014-inch ChocICE™ Extra support guide wire (Boston Scientific Corporation Natick, MA, USA) into both the SC and VA. In the SC artery, the wire was passed through the cells of the fractured stent. An initial kissing balloon and two Sprinter® Legend balloons (2.5 × 20 mm) (Medtronic Inc, Minneapolis, USA), facilitated the advance of a Quantum® balloon (5.0 × 15 mm) (Boston Scientific, MA, USA) through the SC artery, making it possible to use sequential kissing balloons. The fractured stent was then shaped into a thin ring, similar to the shape of a “wedding ring.” The origin of the VA was stented with a Taxus® stent (4.0 × 16 mm) (Boston Scientific, MA, USA). A final kissing balloon was utilized, and the final results of the procedure are depicted in figure 2. Control angiography performed eight months later demonstrated a patent bifurcation, and normal flow within the VA and SC arteries and only minimal intimal hyperplasia. StentBoost imaging revealed preservation of the bifurcation, as well as mild deformity of the ostial segment of the VA (Fig. 3).

Discussion

This report depicts a fractured stent from the VA that became lodged in the lumen of the SC artery. Unfortunately, we do not have the angiographic images of the first stent implantation as this procedure was performed at another institution. This situation presented the challenge of changing both the natural form and the dimensions of the stent. Fortunately, the device was a balloon expandable stent without “thermal memory,” which afforded us an opportunity that may not have been possible with a nitinol self-expandable stent. The new shape of the fractured stent was similar to that of a ring. This shape was preserved throughout the six months that elapsed between the procedure and follow-up as the shape was verified via angiography during the follow-up appointment. Another possible solution for this problem could have been surgical treatment. However, open surgical procedures, including vertebral endarterectomy and bypass operations, have been associated with a high frequency of non-stroke-related complications, including Horner’s syndrome, lymphatic injury, VA thrombosis, and laryngeal nerve injury¹⁰. By contrast,

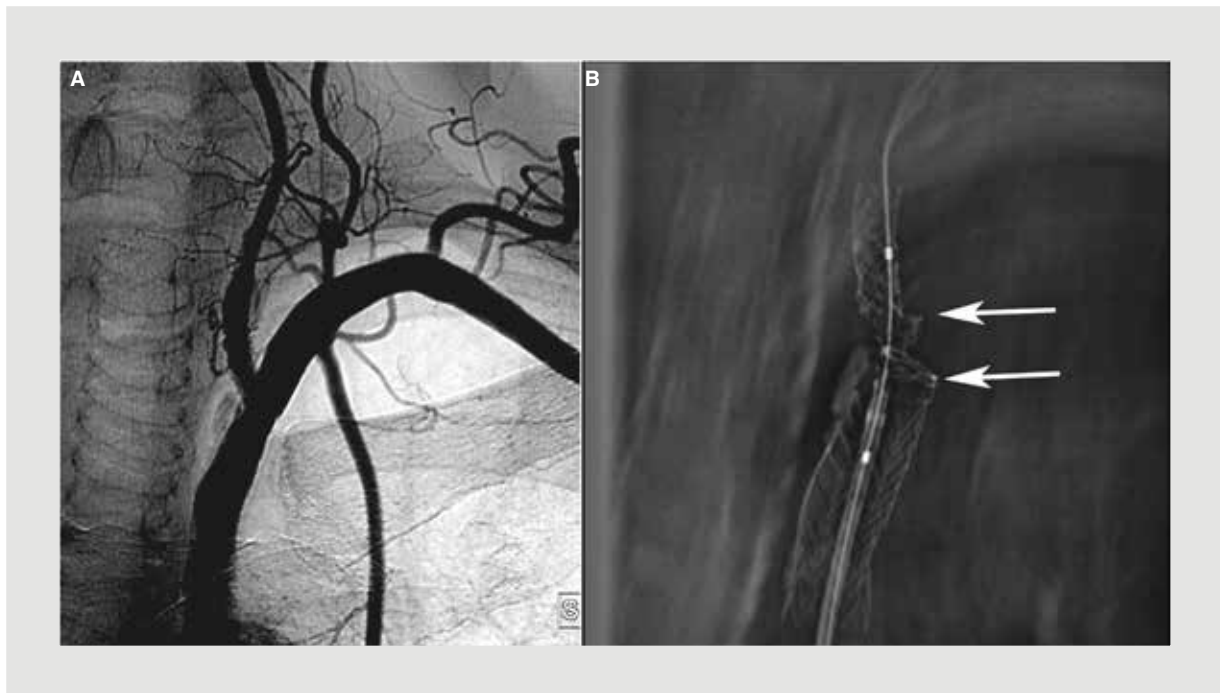


Figura 3. A: Angiographic follow-up, with minimal hyperplasia at the subclavian and vertebral stents. **B:** The StentBoost control enhances the modification of the stent struts in the ostial segment of the vertebral artery (upper arrow), as well as the new bifurcation architecture. The ring shape image is preserved (lower arrow).

Albuquerque, et al. reported a series in which technically successful VA stenting was achieved in 97% of patients (32/33). The only case of technical failure was associated with the slippage of a hand-mounted stent¹¹. This series, as well as another series in which bare metal stents were utilized, achieved excellent technical success rates of between 92 and 100%; however, the restenosis rate ranges between 28 and 48% when using bare metal stents¹²⁻¹⁵. The choice of a drug-eluting stent was based on selected series with low restenosis rates, although these series included low numbers of patients; the largest series included 31 patients, but did not include specifications about stenting the VA origin. Ogilvy, et al., Weber, et al. and Edgell, et al.^{16,17} published the most recent series with drug-eluting stents, series in which restenosis rates ranged between 7 and 17%. The quantity of patients who participated in these studies was small, but the benefits of drug-eluting stents seem to be reasonable. Another option for bifurcation treatment was reported by Rouguin and Alhaddad¹⁸, who used the crush technique at both the VA origin and at the SC artery with excellent angiographic results. In our case, however, the crush technique may have compromised the origin of the VA. Of course, the use of complex techniques to treat bifurcations must be clearly justified,

depending on the characteristics of the lesion. In the example of the kissing balloon, the use of two stents, as well as the rewiring of a single stent, carries the risk of embolization but may be useful if applied only in special cases. The angiographic follow-up images and StentBoost images demonstrated the durability of this technique. At present, the fractured stent that was lodged in the SC artery remains in both the same form and position, with endothelium having covered its surface. The patient remained asymptomatic as of her six-month follow-up appointment.

Conclusions

This case is special as decisions were made during the course of the procedure. Providers may consider this option in the setting of fractured stents in the lumen of the SC artery. Practitioners may offer the patient another feasible treatment when required by the case.

Acknowledgements

To Dr. Alberto Cremonesi, our teacher, for assuming responsibility for our training and for helping us develop this case report.

References

1. Heyman A, Wilkinson WE, Hurwitz BJ. Clinical and epidemiologic aspects of vertebrobasilar and non focal cerebral ischemia. In Berguer R, Bauer RB (Ed). Vertebro basilar arterial occlusive disease. Medical and surgical Management. New York: Raven Pres, 1984:27-36.
2. Caplan LR. Vertebro basilar disease. Adv Neurol. 2003;92:131-40.
3. Coward L, Featherstone R, Brown MM. Percutaneous transluminal angioplasty and stenting for vertebral artery stenosis (Review). Cochrane Database Syst Rev. 2005;CD000516.
4. Gomez CR, Orr SC. Angioplasty and stenting for primary treatment of intracranial artery stenosis. Arch Neurol. 2001;58:1687-90.
5. Lutsep H, Mawad M, Chiu D, et al. The SSYLVA study investigators. Stenting of symptomatic atherosclerotic lesions in vertebral or intracranial arteries. (SSYLVA): Study results. Stroke. 2004;35:1388-92.
6. Coward LJ, Featherstone RL, Brown MM. Angioplastia percutánea transluminal y colocación de stents para la estenosis de la arteria vertebral (Revisión Cochrane traducida). En: La Biblioteca Cochrane Plus, 2008 Número 4. Oxford: Update Software Ltd. Available at: <http://www.update-software.com>. (Traducida de The Cochrane Library, 2008 Issue 3. Chichester, UK: John Wiley & Sons, Ltd.).
7. Wehman C, Hanel R, Guidot C, et al. Atherosclerotic Occlusive extracranial Vertebral artery disease: Indications for intervention, endovascular techniques, Short-term and Long-term results. J Interven Cardiol. 2004;17:219-32.
8. Du B, Wong E, Jiang W, et al. Long-term outcome of Tandem stenting for stenoses of the intracranial vertebrobasilar Artery and vertebral ostium. Am J Neuroradiol. 2009;4:840-4.
9. Tsutsumi M, Kazekawa K, Onizuka M, et al. Stent fracture in revascularization ostial vertebral artery stenosis. Neuroradiology. 2007;3:253-7.
10. Imparato AM. Vertebral arterial reconstruction: A nineteen year experience. J Vasc Surg. 1985;2:626-34.
11. Albuquerque FC, Fiorella D. A reappraisal of angioplasty and stenting for the treatment of vertebral origin stenosis. Neurosurgery. 2003;53:607-16.
12. Weber W, Mayer TE, Henkes H, et al. Efficacy of stent angioplasty for symptomatic stenosis of the proximal vertebral artery. Eur J Radiol. 2005;56:240-7.
13. Ogilvy C, Yang X, Natarajan S, et al. Restenosis rates following vertebral artery origing stenting: Does stent type make a difference? J Invasive Cardiol. 2010;22:119-24.
14. Taylor RA, Siddiq F, Suri MF, et al. Risk factors for in-stent restenosis after vertebral ostium stenting. J Endovasc Ther. 2008;15:203-12.
15. Lin YH, Liu YC, Tseng WY, et al. The impact of lesion length on angiographic restenosis after vertebral artery origin stenting. Eur J Vasc Endovasc Surg. 2006;32:379-85.
16. Werner M, Bräunlich S, Ulrich M, et al. Drug eluting stents for treatment of vertebral artery origin stenosis. J Endovasc Ther. 2010;17:2323-40.
17. Edgell RC, Yavagal DR, Drazin D. et al, Treatment of vertebral artery origin stenosis with antiproliferative drug-eluting stents. J Neuroimaging. 2010;20:175-9.
18. Roguin A, Alhadaddad I. Crush stenting of bifurcational left subclavian-vertebral artery stenosis. Catheter Cardiovasc Interv. 2004;62:393-5.