



Human herpesvirus-6 (HHV-6) is a possible cardiac pathogen: An immunopathological and ultrastructural study

Gerhard RF Krueger,^{*,**} Julieta Rojo,^{***}
L Maximilian Buja,^{*} Dirk Lassner,⁺ Uwe Kuehl⁺⁺

ABSTRACT

Human Herpesvirus-6 (HHV-6), a lymphotropic and neurotropic virus, potentially infects cells with the complement receptor CD46 and may cause significant disease. Although cardiomyocytes do not seem to express significant amounts of the CD46 receptor, cardiac symptoms were previously described in patients with active HHV-6 infection. We have thus studied biopsy and autopsy tissues from serologically HHV-6 positive patients with various cardiac diseases. Diseases include dilated cardiomyopathy in HIV1+/AIDS, other cardiomyopathies or myocarditis, and status post cardiac transplantation. Techniques used include immunohistochemistry for HHV-6 antigens, *in situ* hybridization for HHV-6 DNA, as well as electron microscopy for viral particles. Viral antigens, DNA and viral particles were identified preferentially in vascular endothelial cells, but only occasionally in single degenerating cardiomyocytes. An endothelial dysfunction and microvascular disease is discussed as possible pathogenesis of HHV-6 associated cardiovascular diseases.

Key words: HHV-6, Cardiomyopathy, Myocarditis, Cardiac Transplants, AIDS.

RESUMEN

El virus humano herpes-6 (HHV-6) es un virus linfotrópico y neurotrópico que infecta potencialmente a la célula a través del receptor de complemento CD46, causando daño considerable. Aun y cuando los cardiomiocitos no parecen expresar cantidades significativas de receptores de CD46, se han descrito previamente síntomas cardiacos en pacientes con infección activa de HHV-6. Por lo anterior, estudiamos tejidos de biopsia y de autopsia de pacientes serológicamente positivos a HHV-6 con varias enfermedades cardiacas que incluyeron: cardiomiopatía dilatada en SIDA con HIV1 positivo, otras cardiomiopatías o miocarditis y estados de postrasplante cardiaco. Las técnicas utilizadas incluyeron inmunohistoquímica para determinación de ADN de HHV-6, así como antígenos HHV-6, hibridación in situ microscopia electrónica para partículas virales. Los antígenos virales, el ADN y las partículas virales fueron identificadas principalmente en las células endoteliales vasculares, pero sólo ocasionalmente en aislados cardiomiocitos degenerativos. La enfermedad microvascular con disfunción endotelial se discute como posible patogénesis de enfermedades cardiovasculares asociadas a HHV-6.

Palabras clave: HHV-6, cardiomiopatía, trasplantes cardiacos, síndrome de Kawasaki, SIDA.

INTRODUCTION

HHV-6 belongs to the roseola virus genus of the β -herpesvirus subfamily with the CD46 molecule as its cellular receptor.¹ CD46 is strongly expressed on epithelial cells of salivary gland ducts and on renal tubular cells, moderately well on lymphocytes and vascular endothelial cells, and only weakly on interstitial mesenchymal cells and myocytes.² HHV-6 is ubiquitous in general populations with up to 90% of

* Department of Pathology & Laboratory Medicine, The University of Texas Houston Medical School, and Memorial Hermann Hospital, TX, USA.

** Laboratory of Computational Cell Biology, Department of Anatomy II (Neuroanatomy), The University of Cologne, Cologne, Germany

*** Centro Nacional de la Transfusión Sanguínea, México, D.F.

+ Institut Kardiale Diagnostik und Therapie (IKDT), Berlin, Germany.

++ Department of Cardiology & Pneumology, Charite Universitaetsmedizin Berlin, Campus Benjamin Franklin, Berlin, Germany.

adults being seropositive.³ While acute primary infection with HHV-6 mainly remains subclinical and only in about 5% causes febrile seizures in children or exanthem subitum (roseola infantum), reactivated infections in older children and in adults may be associated with more serious diseases.^{2,4} Such diseases include lymphoproliferative disorders (e.g. co-pathogenesis of Hodgkin's disease), demyelinating diseases (e.g. multiple sclerosis) and post transplantation syndromes, among others.^{2,4,5} Although cardiac symptoms such as palpitations, arrhythmias and tachycardia can be observed in a significant number of patients with reactivated HHV-6 infection,⁶ defined cardiac diseases are only sporadically described so far.⁷ In the current paper we report the identification of viral particles, their antigens and DNA in cardiac biopsies and autopsy specimens from selected patients with seropositive HHV-6 and cardiac pathology.

MATERIAL AND METHODS

Criteria for selecting patients for our study were a) serological evidence for a reactivated HHV-6 infection, and b) clinical cardiac symptoms. Serological evidence for HHV-6 reactivation were serum IgG IFA titers of 1:640 and above, positive serum antigen-capture ELISA for HHV-6 p41 antigens, and blood quantified single round hotstart PCR for HHV-

6 DNA.^{8,9} Clinical evidence for cardiac disease consisted in symptoms such as fatigue, dyspnea on exertion, arrhythmias, abnormal electrocardiogram, enlargement of cardiac ventricles and left ventricular dysfunction (significantly decreased left ventricular ejection fraction). Cardiac tissue from a total of 10 patients were studied: Two HIV1+ patients with dilated cardiomyopathy (autopsies), 2 patients with cardiac allotransplants (autopsies), 2 patients with myocarditis (1 endomyocardial biopsy, 1 autopsy) and 4 patients with cardiomyopathy (endomyocardial biopsies). Immunohistochemical studies for HHV-6 antigens (gp 110/60 J. Luka, Maryland USA, and p41 ABI, Advanced Biotechnologies Inc., Maryland USA) using the APAAP technique were previously described,¹⁰ and *in situ* hybridization for HHV6 DNA were done using the NBT/BCIP technique and a synthetic pZVH14 analogue as DNA probe.^{10,11} Biopsy and autopsy specimens were deparafinized and fixed again for 90 minutes in 0.1 Millionie's buffer (pH 7.2) containing 3% glutaraldehyde and postfixed in 2% osmium tetroxide for one hour. After staining with uranyl acetate, dehydration and propylene oxide treatment, samples were embedded in epoxy resins. 100 nm sections were cut with a Leica EM UC6 ultramicrotome and stained with uranyl acetate and lead citrate. All sections were evaluated in a JEOL 1200EX microscope.

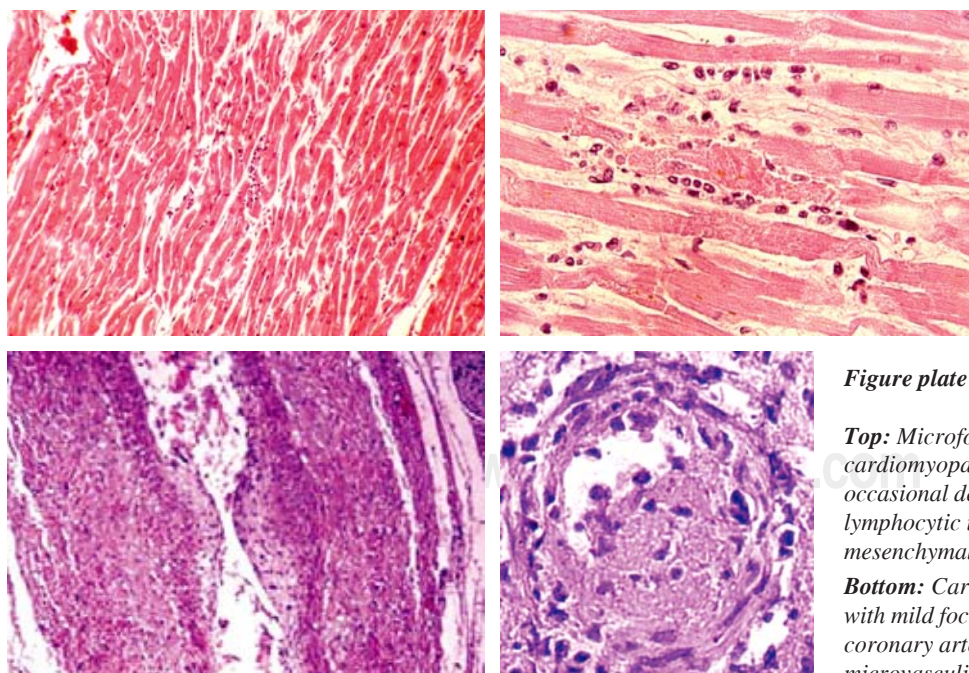


Figure plate 1.

Top: Microfocal myocarditis in HHV-6 positive cardiomyopathy and AIDS patients with occasional degenerating cardiomyocyte, mild lymphocytic infiltration and prominent mesenchymal activation.

Bottom: Cardiac transplant and AIDS patients with mild focal fibroendothelial plaques in coronary arteries and occasional thrombotic microvasculitis.

RESULTS

Gross and microscopic findings

All 10 patients showed a prominent enlargement of their hearts, both on chest Xray and at autopsy with a reduced left ventricular ejection fraction of below 50%. Microscopy (preferentially of the left lateral ventricular wall) showed usually some interstitial edema with swollen and proliferated mesenchymal cells, mild diffuse and perivascular fibrosis, and only a scarce focal lymphocytic infiltrate ("borderline myocarditis"). Only in the two cases diagnosed as myocarditis lymphocytic infiltrates were somewhat more prominent. Cardiomyocytes in the endomyocardial biopsies showed some vacuolization ("sarcolysis") as known from reperfusion damage, occasional contraction bands, and in two HIV1+ autopsy cases scattered small focal necroses. In addition, the AIDS+ cases and cardiac transplants showed focal intimal proliferates in coronary arteries and occasional thrombotic small vessel disease in epicardial and systemic vessels (*Figure plate 1*).

Immunohistochemistry and *in situ* hybridization

Both gp110/60 and p41 HHV-6 antigens were demonstrated in all biopsy- and autopsy cases, although usually in small numbers of cells only. While HHV-6 gp 110/60 antigens were detected preferentially in interstitial cells and in vascular endothelial cells with some equivocal staining of cardiomyocytes, HHV-6 p41 was also seen in endothelial cells of small vessels (*Figure plate 2*). There was no unequivocal deposition of HHV-6 p41 antigens in cardiomyocytes with the techniques used. Interstitial cells that stained positive were usually larger cells probably representing macrophages rather than lymphocytes. This impression was supported by *in situ* hybridization data, where HHV-6 DNA was seen in all cases only in endothelial cells of small interstitial vessels. The 2 transplant patients showed HHV-6 DNA focally in endothelial cells of coronary vessels as previously described by J.Luka using *in situ* PCR.¹²

Ultrastructural studies

Although specimens for ultrastructural studies were not optimal due to previous formalin fixation and paraffin embedding, careful evaluation confirmed the micro-

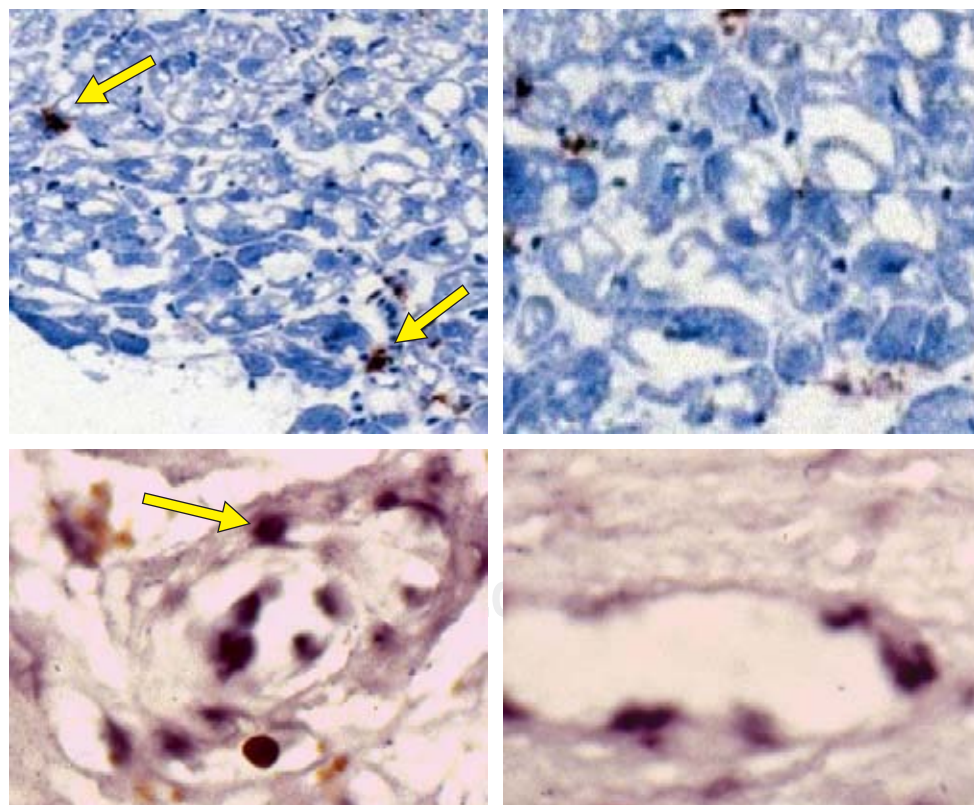


Figure plate 2.

Top: Myocardial biopsies of patients with HHV-6 positive cardiomyopathy and myocarditis showing prominent ballooning degeneration of cardiomyocytes and HHV-6 antigen deposition in interstitial cells and vascular endothelia (arrows).

Bottom: In situ hybridization for showing endothelial deposits of HHV-6 DNA in all patients (arrow).

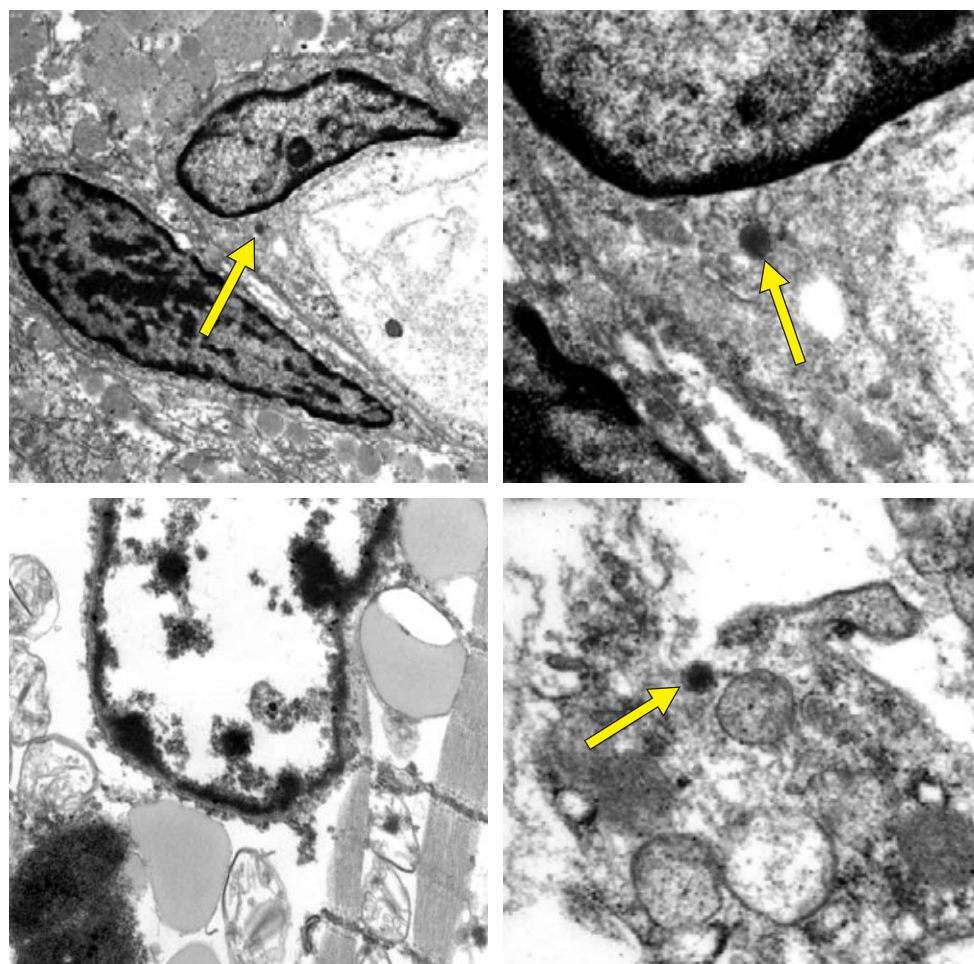


Figure plate 3.

Top: Electron microscopy showing herpesvirus particles in vascular endothelium of cardiac biopsies in HHV-6 positive cardiomyopathy and myocarditis as well as in AIDS patients (arrows).

Bottom: Electron microscopy showing a degenerating cardiomyocyte without clearly identifiable viral structures (left) while interstitial degenerating macrophages contain occasional herpesvirus particle (right, arrow).

scopic findings of mesenchymal cell activation, occasional mild focal inflammatory (lymphocytic) infiltration and focal cardiomyocyte degeneration. Herpes-type virus particles were found in all cases preferentially in small vascular endothelial cells. Degenerating cardiomyocytes occasionally contained dense bodies that might have been remnants of herpesvirus particles, yet proof was not possible with the techniques used. Also, monocytes contained occasional herpesvirus particle in the cases with myocarditis, cardiomyopathy, yet not in the transplant patients (*Figure plate 3*).

DISCUSSION

All cases reported in this study were selected on the basis of proven HHV-6 reactivation with circulating viral DNA and p41 antigen and clinical evidence of cardiac dysfunction. Some are part of a major clinical study which is reported elsewhere.^{13,14} Cases with dual viral infections such as with parvovirus B19 and

with adenovirus were excluded from this study except for the two HIV1 positive AIDS cases. Using such strict criteria for selection, all 10 cases studied showed evidence for active cardiac HHV-6 infection (without distinguishing between the subtypes HHV-6A and HHV-6B with the methods used).

As HHV-6 positive cases were selected intentionally, nothing can be said about the frequency of HHV-6 reactivation in the diseases discussed. This is addressed in the main clinical publication.¹³ The current study was done to identify the eventual localization of HHV-6 in the heart itself of diseased patients and thus contribute to the elucidation of its possible pathogenesis.

HHV-6 gp 110/60 antigens as detected preferentially in interstitial cells and in vascular endothelial cells with some equivocal staining of cardiomyocytes is a structural viral antigen. Its deposition does not prove an ongoing active infection, yet only that virus antigen was deposited at some time without a clearcut time frame. It does also not prove unequivocally

cally a pathogenic relationship of cardiac lesions and HHV-6.^{15,16} HHV-6 p41, instead, is a functional antigen synthesized during virus replication and thus indicates active infection when shown in tissues. Our finding of HHV-6 p41 antigen in scattered interstitial cells (probably macrophages) and in small vessel endothelial cells proves viral replication at these sites. This is further substantiated by showing HHV-6 DNA at these sites and by the ultrastructural demonstration of herpesvirus particles in these cells (while there was no serologic evidence in selected patients for infections with other herpes viruses but HHV-6). No differentiation is possible, though, in our present study between the HHV-6 subtypes, HHV-6A or HHV-6B.

The low number of cells carrying HHV-6 DNA by *in situ* hybridization and HHV-6 p41 by immunohistochemistry, and the even lower number of cells with recognizable viral particles in electron microscopy make a direct pathogenic effect of HHV-6 on myocardial cells less convincing. This notion is further supported by finding viral DNA and viral particles quite preferentially in small vessel endothelial cells rather than in cardiomyocytes. In addition, early microscopic lesions in the myocardium of HHV-6 infected hearts remind to a certain extent on what is commonly seen in reperfusion damage of the heart. In this context, the observations of Vallbracht and colleagues are most important that the endothelium-dependent flow-mediated vasodilatation becomes impaired in patients with myocardial virus persistence.¹⁷ Our findings are thus further supporting the previous hypothesis that cardiac pathology in persistent active HHV-6 infection is a consequence of microcirculatory dysfunction rather than of a direct toxic effect on cardiomyocytes.^{7,14} This idea was further supported by the observation of thrombotic microvasculitis in occasional case. The final proof of HHV-6 as a causative agent in certain forms of myocarditis/cardiomyopathies and post transplant cardiac dysfunction will rely upon the clinical improvement following successful treatment of the viral infection.¹³

REFERENCES

1. Santoro F, Kennedy PE, Locatelli G, Malnati MS, Berger EA, Lusso P. CD46 is a cellular receptor for human herpesvirus 6. *Cell* 1999; 99: 817-828.
2. Krueger GRF, Ablashi DV. Human herpesvirus-6: A short review of its biological behavior. *Intervirology* 2003; 46: 257-269.
3. Ablashi DV, Krueger GRF, Salahuddin SZ (eds). *Human Herpesvirus-6*. Amsterdam: Elsevier Sci Publ; 1992. p. 1-341.
4. Krueger GRF. Infections with HHV-6 and HHV-7: summary of other disease associations. *J Clin Virol* 2006; 37 (suppl 1): S109-110.

5. HHV-6; an underestimated virus. *Proc 5th Internat Conf on HHV-6 & HHV-7*. Barcelona, 2006. *J Clin Virol* 2006; 37 (suppl 1): S1-S120.
6. Krueger GRF, Klueppelberg U, Hoffmann A, Ablashi DV. Clinical correlates of infection with human herpesvirus-6. *In Vivo* 1994; 8: 457-485.
7. Buja LM. HHV-6 in cardiovascular pathology. In: Krueger GRF, Ablashi DV (eds). *Human Herpesvirus-6*. 2nd ed. Amsterdam: Elsevier Sci Publ; 2006. p. 233-241.
8. Krueger GRF, Bertram G, Ramon A, Koch B, Ablashi DV, Brandt ME, Wang G, Buja LM. Dynamics of infection with human herpesvirus-6 in EBV-negative infectious mononucleosis: data acquisition for computer modeling. *In Vivo* 2001; 15: 373-380.
9. Wagner M, Krueger GRF, Ablashi DV, Whitman JE. Chronic fatigue syndrome: a critical evaluation of testing for active human herpesvirus-6 (HHV-6) infection: Review of data of 107 cases. *J Chron Fatigue Syndr* 1996; 2: 3-16.
10. Seyda M, Scheele T, Neumann R, Krueger GRF. Comparative evaluation of nonradioactive *in situ* hybridization techniques for pathologic diagnosis of viral infection. *Pathol Res Pract* 1989; 184: 18-26.
11. Josephs SF, Salahuddin SZ, Ablashi DV, Schachter F, Wong-Staal F, Gallo RC. Genomic analysis of the human B-lymphotropic virus (HBLV). *Science* 1986; 234: 601-603.
12. Luka J, Aufferbach C, Carson SD, Krueger GRF. Detection of human herpesvirus-6 (HHV-6) genomes by *in situ* PCR and *in situ* hybridization in tissues from Kawasaki disease and in coronary arteries of transplanted hearts. *J Clin Virol* 2006; 37 (suppl 1): S111.
13. Kuehl U, Lassner D, Pauschinger M, Gross UM, Krueger GRF, Seeberg B, Noutsias M, Escher F, Poller W, Schultheiss HP. Prevalence of cardiac involvement of human herpesvirus 6A and B subtypes in patients with acquired cardiomyopathies and heart failure symptoms. 2008 submitted for publication
14. Krueger GRF. HHV-6 in cardiac diseases. SFB Transregio 19 International Symposium on Molecular Therapies Targeting new Pathogenic Pathways and Networks in Human Cardiomyopathies. Harnack House of the Max-Planck-Society Berlin Oct. 25-27, 2007.
15. Krueger GRF, Ablashi DV, Salahuddin SZ (eds). Persistent herpesvirus infections: Current techniques for diagnosis. *J Virol Methods* 1988; 21: 1-326.
16. Krueger GRF, Ablashi DV, Josephs SF, Salahuddin SZ, Lembke U, Ramon A, Bertram G. Clinical indications and diagnostic techniques of human herpesvirus-6 (HHV-6) infection. *In Vivo* 1991; 5: 287-296.
17. Vallbracht KB, Schwimmbeck PL, Kuehl U, Seeberg B, Schultheiss HP. Endothelium-dependent flow-mediated vasodilatation of systemic arteries is impaired in patients with myocardial virus persistence. *Circulation* 2004; 110: 2938-2945.

Corresponding author:

Gerhard RF Krueger MD PhD

Department of Pathology & Laboratory Medicine,
UT - Houston Medical School,
6431 Fannin St., MSB 2.136,
Houston, Texas 77030
E-mail: Gerhard.Krueger@uth.tmc.edu