



Use of amniotic membrane radiosterilized with cobalt-60 for reconstruction of ocular surface

Leticia Vázquez-Maya,* Marco Antonio Salazar-Escamilla,*
María Esther Martínez-Pardo**

ABSTRACT

Purpose: To evaluate the efficiency of the Radiosterilized Amniotic Membrane in diseases of the ocular surface, from refractory to conventional treatments. **Methods:** In this study 17 eyes of 15 patients with corneal ulcer, persistent epithelial defect, alkali burn, symblepharon and the like, were treated with radiosterilized amniotic membrane. 11 men and 4 women were included. They were divided into two groups: in group I there were 10 eyes with epithelial defects and thinning of the stroma, which constituted a menace to the integrity of the eye and seven eyes were used in group II, where it was required to promote an adequate epithelial migration of the eye to avoid exaggerated fibrous scarring after a surgical procedure. **Results:** The average age of our population was 38.4 ± 22.6 , with a range of 12 to 83 years of age. The post surgical follow-up, on average, was 3.1 ± 2.5 months (range of 15 days to 7 months). The desired effect with the membrane was: 90% in group I and 85.7% in group II. **Conclusion:** The amniotic membrane radiosterilized with cobalt-60 represents an effective and secure treatment for diseases of the ocular surface. This type of membrane has several advantages: low cost, storage at room temperature, translucent, among others.

Key words: Amniotic membrane, radiosterilization, ocular surface diseases.

RESUMEN

Objetivo: Evaluar la eficacia de la membrana amniótica radioesterilizada con cobalto-60 en enfermedades de la superficie ocular, refractarias a tratamientos convencionales. **Método:** 17 ojos de 15 pacientes que presentaron úlceras corneales, defectos epiteliales persistentes, quemaduras corneales por álcalis o simblefaron, fueron tratados con injerto de membrana amniótica radioesterilizada. Fueron incluidos 11 hombres y cuatro mujeres, divididos en dos grupos. Grupo I: 10 ojos con defectos epiteliales y adelgazamiento corneal que amenazaba con perforación. Grupo II: Siete ojos que requerían promover una adecuada migración de epitelio y evitar la formación de una cicatrización exagerada después de un procedimiento quirúrgico. **Resultados:** El promedio de edad fue 38.4 ± 22.6 años (rango: 12 a 83). El promedio de seguimientos quirúrgicos fue de 3.1 ± 2.5 meses (rango: 15 días a siete meses). El efecto esperado con el uso de la membrana amniótica fue de 90% en el grupo I y de 85.7% en el grupo II. **Conclusiones:** La membrana amniótica radioesterilizada con cobalto-60 resulta en un tratamiento efectivo y seguro para enfermedades de la superficie ocular. Las ventajas que tiene esta membrana son: bajo costo, conservarse a temperatura ambiente y ser translúcida.

Palabras clave: Membrana amniótica radioesterilizada, enfermedad de la superficie ocular.

INTRODUCTION

The amniotic membrane of the human placenta, obtained during natural childbirth or cesarean operation,¹ is the internal wall of the fetal membrane² and it has

been used in skin transplants. In 1910 Davis was the first to report on its use as surgical material for skin.³ It is an excellent option for skin grafts due to its anti-inflammatory, anti-scarring and anti-adhesive properties, as well as a stimulation of the epithelium.

* Hospital General de México.

** Instituto Nacional de Investigaciones Nucleares.

Recibido para publicación: 09/02/09.

Aceptado: 09/03/09.

For more than half a century, the use of the amniotic membrane for ophthalmologic applications remained dormant. After the initial use of De Roth⁴ and Sorsby⁵ and up to the 90s, when Batle,⁶ Dua,⁷ Tseng⁸ and others gave it the legitimate character it continues to have.

Types of amnion graft

The types of amnion grafts used for clinical application can use fresh amniotic membranes (kept at 4-8 °C), lyophilized or frozen. The fresh membrane is as good or better than the preserved frozen membrane (-70 °C). However there is a concern over the risk of HIV infection. The radiosterilized amniotic membrane used in this research offers the following advantages:

1. Security: appropriated donor screening and a sterilization assurance level (SAL) of 10⁻⁶.
2. Easy handling and storage at room temperature.
3. Low cost.
4. Translucent, which permits easy clinical examination of the corneal evolution.

The Hospital General de México has the experience needed in the use of amniotic membranes that have been preserved in a solution where antibiotics have been added. The product is called «am2 amnios in a preserving medium» and is used in the treatment of patients with different corneal pathology.⁹

In Mexico, the Banco de Tejidos Radioesterilizados (Radiosterilized Tissue Bank) of the Instituto Nacional de Investigaciones Nucleares (National Institute for Nuclear Research) (BTR-ININ), was established in 1999, thanks to strong support of the International Atomic Energy Agency (IAEA). The BTR processes and sterilizes with cobalt-60 gamma radiation, tissues such as amnion and pig skin. These tissues have been used as biological wound dressings in patients with first, second and third degree burns, ulcers, epidermolysis bullosa,¹⁰ bloody areas, and in wounds difficult to heal.¹¹⁻¹² The Secretaría de Salud (Mexican Ministry of Health) issued the sanitary license No. 1062000001 to the BTR-ININ on July 7, 1999.¹³ The Quality Management System QMS of the bank was certified by ISO 9001:2000 on August 1, 2003,

Diverse pathologies exist that condition severe lesions of the ocular surface, such as: keratoconjunctivitis with scarring, pterygium associated with symblepharon,¹⁴ epidermolysis bullosa,¹⁵ neurotrophic ulcers,¹⁶ corneal thinning or those caused by bacteria or trauma, which often require surgery but have an unsuccessful outcome.

PATIENTS AND METHODS

A clinical prospective study was carried out on lesions of the ocular surface of 17 eyes from 15 patients, between March and November of 2005, at the Department of Cornea and Refractive Surgery of the Ophthalmology Service in the Hospital General de México. This hospital attends mainly needed individuals who cannot afford expensive treatments.

Written and informed consent was obtained from all patients. The amniotic membrane was donated by the BTR-ININ, this bank has its sanitary license since 1999. Patients underwent a ophthalmologic examination, which included record of visual acuity, slit-lamp examination biomicroscopy and photographic control.

The patients were divided into two groups: Group I included 10 eyes with epithelial defects and thinning of the stroma, in imminent danger of perforation, which constituted a menace to the integrity of the eye (*Table I*). The patients from group I had the following diagnosis: necrotizing scleritis (n = 1); corneal thinning (n = 2); partial stem cell deficiency (n = 1); persistent epithelial defect (n = 1); corneal perforation (n = 1) and corneal ulcer (n = 4).

Seven eyes formed group II, where it was required to promote an adequate epithelial migration of the eye to avoid exaggerated fibrous scarring after the surgical procedure (*Table II*). In this group, the number of patients with their diagnosis was: symblepharon (n = 3); invasive pterygium (n = 1); band keratopathy (n = 1); complete stem cell deficiency (n = 1) and pterygium/ectropion (n = 1).

The inclusion criteria were as follows: All patients with lesions of the ocular surface were included, independent of their age, sex, or pathology, and who had received some kind of treatment for at least two weeks, without favorable results. The ocular surface lesions considered for this research were: a) Corneal thinning with an imminent risk of perforation or, if the perforation existed, that it be less than 0.5 mm, evaluated with a slit lamp with a positive Seidel sign, b) Corneal and conjunctival scarring (symblepharon, recurrent pterygium), c) Corneal opacity with stem cell deficiencies.

Patients with macro corneal perforations (more than 2 mm in diameter) and those that did not agree with the procedure were excluded.

The evaluation included follow-up visits on days 2, 7, 15 and monthly. On each visit we evaluated pain with a scale, where zero was no pain and ten was unbearable. Visual acuity, intraocular pressure, slit-

lamp examination where we evaluated the adhesion of the membrane, re-absorption of the membrane and corneal epithelium integrity, presence of signs of corneal perforation such as flat or shallow anterior chamber or positive Seidel test, ocular surface inflammation or corneal scarring.

In the postoperative period, a combination of tobramycin and prednisolone eye drops were adminis-

tered every four hours for 15 days and oral analgesic as needed, in addition to patient's regular basis of medication.

The desired effect of the surgery was defined by any of the following: re-formation of the anterior chamber and a negative Seidel test, restoration of corneal epithelium, transparency of the cornea or no presence of scar tissue. Failure was defined as the

Table 1. Group I: Risk of corneal perforation. Patients with threat of the integrity of the eyes.

Case	Age	Gender	Eye	Diagnosis	Associated condition	Procedure	Length of follow-up (months)
1	40	M	RE	Necrotizing scleritis	Erythropoietic porphyria	AMT	1
3	37	F	LE	Corneal thinning	Rheumatoid arthritis	AMT	7
5	37	F	RE	Corneal thinning	Rheumatoid arthritis	AMT	7
9	18	M	RE	Alkali burn		AMT	5
10	83	F	RE	Persistent epithelial defect	Penetrating keratoplasty	AMT	3
11	15	M	LE	Corneal perforation	Herpes simplex	AMT	2
13	56	F	RE	Exposition corneal ulcer	Orbital sarcoma	AMT + tarsorrhaphy	1
14	44	F	RE	Exposition corneal ulcer	R. arthritis, facial palsy	AMT	1
15	17	M	RE	Corneal ulcer	Atopic conjunctivitis	AMT + (Cryo)	1
16	17	M	LE	Corneal ulcer	Atopic conjunctivitis	AMT + (Cryo)	1

AMT = Amniotic membrane transplantation. BCL + C = Bandage corneal lent + cyanoacrylate. Cryo = Cryotherapy.

Table II. Group II: Alteration of epithelialization and scarring.

To promote corneal epithelium healing and prevent scarring after surgery with extensive corneo-conjunctival adhesion.

Case	Age	Gender	Eye	Diagnosis	Associated condition	Procedure	Length of follow-up
2	20	M	LE	Symblepharon	Thermal burn	AMT + limbal graft	3 months
4	37	M	LE	Invasive pterygium	Actinic prurigo	AMT	4 months
6	39	M	RE	Symblepharon	Alkaline burn	AMT	3 months
7	12	M	LE	Band keratopathy	Penetrating keratoplasty	AMT	1 week
8	75	M	RE	Symblepharon		AMT	3 months
12	19	M	LE	Conjunctivization corneal	Thermal burn	AMT + limbal graft	1 month
17	64	M	LE	Pterygium/ectropion	Schizophrenia	AMT + blepharoplasty	1 month

AMT = Amniotic membrane transplantation.

presence of any of the following: persistence of Sidel sign, reoccurrence of the de-epithelialization, opacity of the cornea or the reoccurrence of exuberant scar tissue.

Amnion processing. To obtain the raw material, the amnion, the ININ has an agreement with the Hospital Materno Infantil-ISSEMYM. Thus, the hospital is liable for:

- *Donor selection:* Potential donors are identified at the hospital and each donor must sign the donor consent prior to procurement. Amnions collected after written consent from healthy mothers were obtained during caesarean sections or vaginal natural birth under aseptic conditions, complete gestation, without any macroscopic evidence of fetal suffering (meconium spots), among others.
- *Serology tests:* According to international requirements, blood for donor testing is drawn prior to donation and 6 months later, if conventional serological techniques are used (such as ELISA). The serological tests performed by a licensed laboratory included HIV-1/2, Hepatitis B, Hepatitis C and Syphilis. The screening of donors is done according to the IAEA International Standards for Tissue Banks (2002)¹⁷ and are the minimum required all over the world.
- *Amnion procurement, preliminary cleaning and temporary storage:* Fresh placenta is collected aseptically from the delivery room or operating theatre. Amnion is immediately separated from chorion and cleaned by rinsing several times in saline solution at room temperature, to eliminate blood remnants. Then, the amnion (amniotic membrane AM) is transferred to a sterile plastic container with a sterile normal saline 0.9% solution, labeled with donor's data, and preserved in a domestic refrigerator (4-8 °C) until the tissue is sent to the bank.

The BTR-ININ is responsible for the following:

- *Reception:* The tissues (AM) are placed in a refrigerator in the human tissue humid process area in the BTR, awaiting quality control approval. This is done only after all serological test results are completed and negative. The time between procurement and processing should be 7 days maximum.
- *Washing and drying:* Amnion are washed thoroughly four times, 10 min each, in sterile saline

solution (0.9%), soaked in 0.5% sodium hypochlorite solution for 10 min and washed four times, 10 min each, with sterile distilled water in a shaker to obtain a clean tissue without any blood remnants or spongy layer. Under a laminar airflow cabinet class II, exclusive for human tissues, the AM is placed on the surface of sterile tissue (polyester) so that it may air-dry overnight.

- *Packaging and labelling:* Amnion specimens are cut in small pieces for ophthalmology use, 3 x 3 cm² in the laminar airflow cabinet, double-packed at vacuum in a medical grade paper/polyethylene (PE) bag as primary package, labelled and placed inside a PE bag, which is the secondary package. The label has the tissue bank data, tissue type, identification code for traceability, expiration date, size, recommendations for handling and storage at room temperature and, of course, an irradiation indicator that changes from yellow to red upon irradiation.
- *Microbiological control:* It is done at ININ Biology Department, following the ISO/13409:1996 18, which is an adaptation of the ISO 11137 (Method 1) for small or infrequent production of tissue batches. This norm is to determine the sterilization dose to achieve a SAL of 10⁻⁶, taking into account the initial average bioburden, which must be less than 1000 colony forming units (CFU)/product unit. For average bioburden estimation, 10 sample item products (SIP) are taken.
- *Sterilization:* Radiation sterilization of amnion is done at the Departamento del Irradiador del ININ (ININ Irradiator Department); using an industrial cobalt-60 source, model JS-6500 AECL. The maximum source strength in *becquerel* is 37 PBq (1x10⁶ Curie). To maintain the installed capacity, the radiation source is reloaded annually. This facility has an operation license issued by the Comisión Nacional de Seguridad Nuclear y Salvaguardias (National Nuclear Safety and Regulatory Commission), a sanitary license issued by the Secretaría de Salud (Mexican Health Ministry) and Quality Management System QMS certified by ISO 9001:2000. The irradiator works continuously, the product boxes are exposed to high penetrating gamma radiation, which is electromagnetic radiation similar to X-rays. Gamma radiation produces an ionizing effect which inactivates microorganisms without significant temperature increase. The amount of absorbed energy per unit mass of

the irradiated material is called absorbed dose (or dose) and is expressed in *gray* units (1gray = 1 Gy = 1 J/kg). To quantify the maximum and minimum dose is necessary to use dosimeters, placed in specific positions on the product box. The sterilization dose usually used for the amnion is 25 kGy.

- **Sterility tests, storage at room temperature and distribution** of high quality tissues for clinical application are the final steps. Once the irradiation process is finished, the tissue is returned to the BTR, where it remains at room temperature for six months, during which the living donor is located and serology is repeated. Once the results are negative for Syphilis, HIV 1, 2, Hepatitis B and C, the tissue is ready for its clinical application. All activities are performed under rigorous quality control to comply with the requirements of the BTR-ININ QMS, which was certified under ISO 9001:2000 on August 1, 2003.¹⁹ Accordingly, each step has the corresponding Standard Operation Procedure (SOP), Working Instructions or Register form, if necessary.

Surgical technique. The surgery was performed by one surgeon. Sub-conjunctival anesthesia with 2%

Lidocaine was used and in one patient retrobulbar anesthesia was required. Epithelial debridement using a 15 blade scalpel was done as shown in *figure 1*. The membrane was submerged in a balanced saline solution for 10 minutes before collocation. A conjunctival peritomy was carried out in 360° fornix base with blunt dissection. The cornea was covered with the membrane, overlaid, adjusting it to an adequate size, being sure that the borders always remained under the conjunctiva. In this type of membrane, the epithelial side is indistinguishable. We used continuous suture with monofilament 10-0 in the 360°.

Finally, tobramycin and prednisolone colirium were applied as well as a therapeutic soft contact lens. The stitches were removed 15 days later and the contact lens was removed one month later (*Figure 1*).

Statistical analysis. A descriptive statistic strategy was carried out by analyzing the data with measures of central tendency, with the help of a spreadsheet (Microsoft Office-Excel).

RESULTS

The average age of our population was 38.4 ± 22.6 , with a range of 12 to 83 years of age. The post-surgical follow-up, on average, was 3.1 ± 2.5 months (range of 15 days to 7 months). Two patients discon-

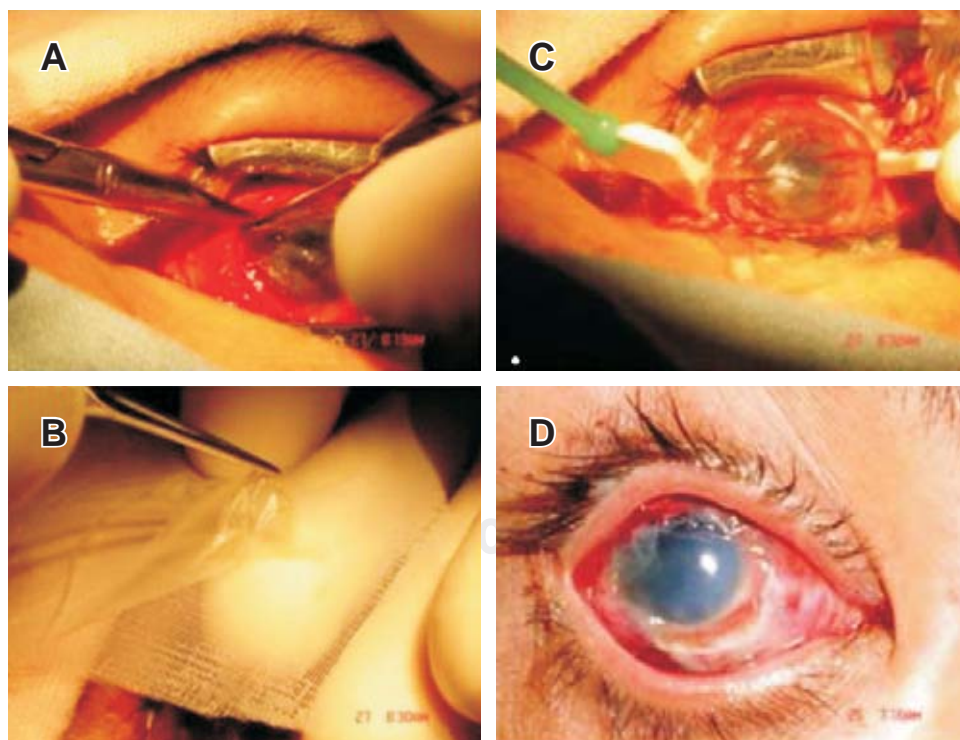


Figure 1.

Surgical Technique. The peritomy was completed for 360 degrees using Steven or Wescott scissors (A). Membrane under the conjunctiva (C). Radiosterilized membrane (B). First day after surgery (D).

tinued the post-surgical follow-up for unknown causes, the first one, number 1, from Group I after one month, and the second one, number 7 from Group II, after 15 days.

In group I, only the amniotic membrane was placed in 7 eyes, in one eye a tarsorhaphy was done and on two eyes cryotherapy of the tarsal papilla was carried out. Only in case 14 was the amniotic membrane applied in multi layers, due to the depth of the ulcer which involved the deep stroma. In group II, four eyes were grafted only with the amniotic membrane. In two eyes the limbus graft was combined with the amniotic membrane and blepharoplasty with membrane was performed on the last patient.

Inflammation and pain were significantly reduced in both groups. In group I, 90% had complete adhesion of the membrane one week later, and in group II, 100% had complete adhesion of the membrane. In the same time lapse patients with simblepharon

and pterygium, from group II, had excellent results as much for cosmetic purposes as for functional ones (*Figure 2*).

All the membranes were totally or partially absorbed. The remnants presented a variable quantity of opacity that disappeared at the end of the study. In the two cases with perforation history (group I) the anterior chamber depth was normal and the cornea had complete epithelialisation and increase of stroma thickness.

In group I, visual acuity remained unchanged in two patients. It improved in three patients, and deteriorated in four patients. In group II, the visual acuity improved in 6 cases. Case 3 of group I, which corresponds to the left eye of a patient with rheumatoid arthritis, presented corneal perforation two months later. For this reason, it was necessary to place a therapeutic lens with cyanoacrylate; subsequently this patient had two tectonic grafts in his left eye. In case 5 of group I, which corresponds to the right eye of the same patient of case 3, perforation was detected three months after placing the membrane on the right eye. For this reason, cyanoacrylate and therapeutic lenses were placed.

The desired effect above mentioned with the membrane was obtained in 90% in group I and 85.7% in group II.

DISCUSSION

Even though the use of the amniotic membrane is not a new procedure, in the last few years there has been a boom in its use.²⁰

The amniotic membrane graft offers great advantages over any other procedure. The conjunctival flap tend to retract and leave the surface uncovered. Furthermore, this conjunctival flap does not allow the observation of the evolution of the damaged tissue. Grafts with radiosterilized amniotic membrane also offer security because they do not express antigens HLA-A, B or DR, and do not provoke rejection.²¹⁻²² There is a potential risk of bacterial contamination of the membrane that has been cryopreserved.²³

In cases 3 and 5, which correspond to the same patient that suffered rheumatoid arthritis, it is important to point out that she had been treated in other institutions, where tectonic grafts had been used. When she came to us, she had already been rejected from these institutions because they had nothing else to offer. Her main objective was to maintain an-

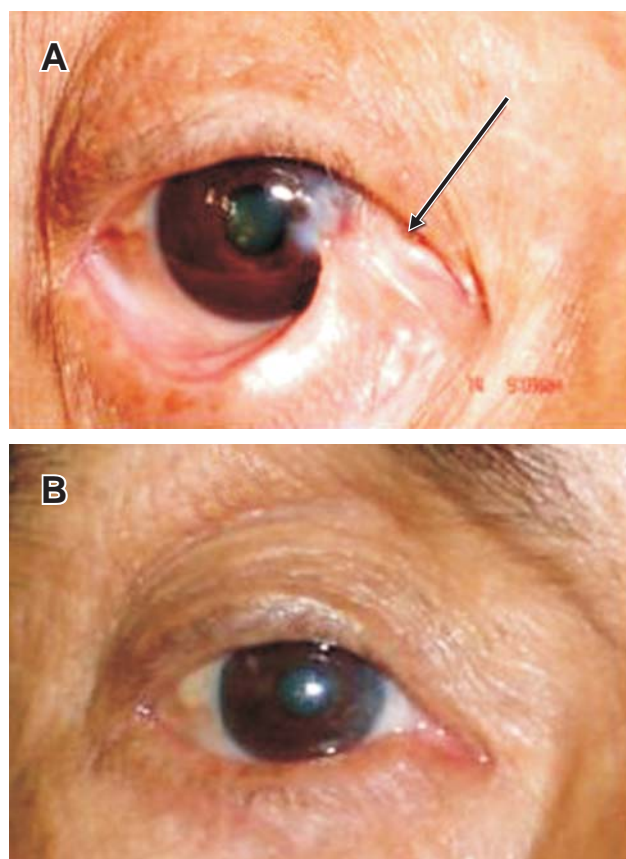


Figure 2. Case 8 had symblepharon, indicated by an arrow (A). Three months after membrane transplantation and symblepharon resection (B).

atomical integrity. The placing of the membrane avoided the loss of the organ, but persistent inflammation of the ocular surface, lack of lubrication, and the essential pathology (rheumatoid arthritis) causes its effect to slowly deteriorate as time goes by, as is pointed out in other publications²⁴ and thus it would only be a temporary treatment before performing any other surgical procedure.

In this research no case of loosening of the membrane was presented, as has been reported in other papers.²⁵ We think this is because we always place it under the conjunctiva so we can avoid the eyelid movements from loosening it.

In this study, an important reduction of the inflammation was observed after placing the membrane, as is pointed out in other reports.⁹⁻¹² It is important to remember that the persistence of the exposition

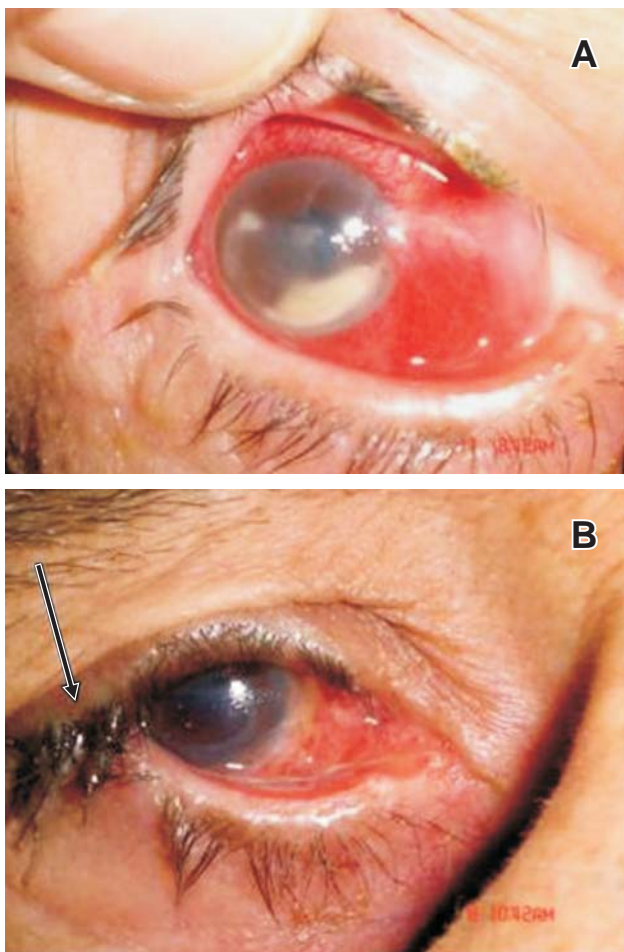


Figure 3. Case 13 had corneal ulcer by exposure, see the inflammatory reaction (A). One month after surgery, completely healthy. The arrow indicates partial tarsorrhaphy.

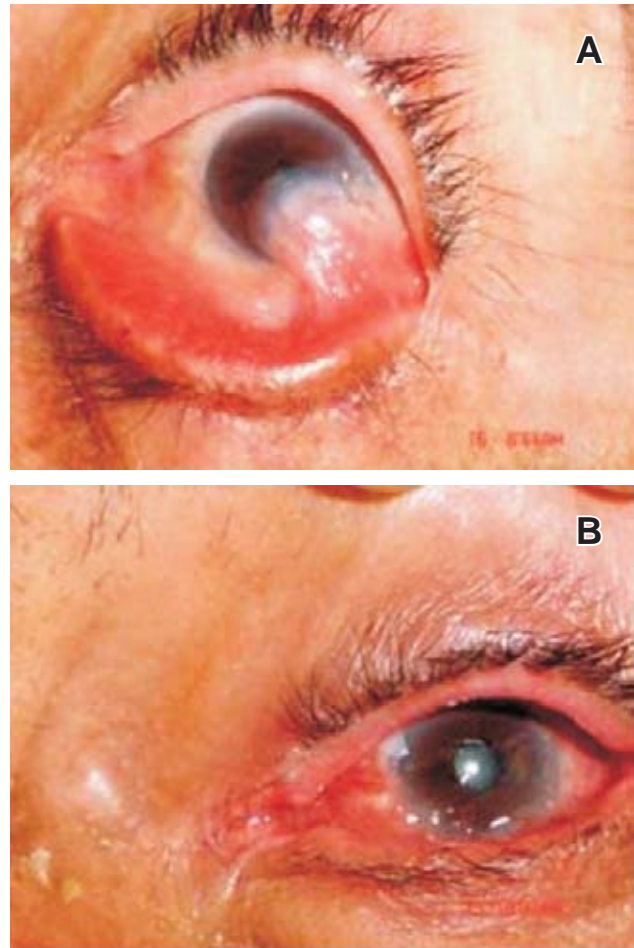


Figure 4. Case No. 17 had symblepharon and ectropion (A). One month after amniotic membrane transplantation and ectropion correction.

is a limiting factor for the result of the graft, this is why in case 13 of group II it was combined with a tarsorrhaphy (Figure 3). A wide resection of the maxillary antrum was performed on this patient due to a tumor, provoking a very important exposure of the ocular globe.

The use of the membrane in case 17 was to prevent exposure and dryness of the ocular surface, due to poor eyelid movement and to promote epithelial healing (Figure 4). This patient underwent a symblepharon resection with amniotic membrane placement, obtaining satisfactory results.

The use of the amniotic membrane can promote the regeneration of stem cells when a partial deficiency exists as is case 9, who suffered an alkali corneal burn, provoking a partial stem cell deficiency. A

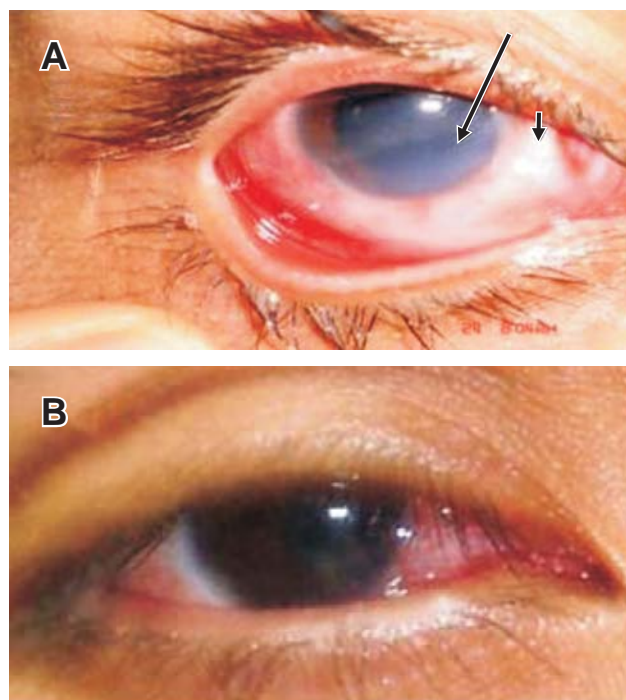


Figure 5. Case 9 had corneal burn by alkali. Corneal opacity (large arrow) and limbal ischemia (small arrow) are clearly shown in (A). Three months after amniotic membrane transplantation, the cornea is completely clear (B).

membrane without the limbus graft was placed (Figure 5). The opacity that the cornea presented due to the damage done to the stem cells disappeared. At any rate it must be emphasized that the membrane must not be used in cases of total stem cell deficiency or severe tear deficiency.²⁶ Even though this recommendation, we used amniotic membrane and limbal graft in case 12: a patient that suffered an explosion of gumpodwer, that affected his left eye. The eye showed total corneal opacity and superior symblepharon. During the surgery, the reconstruction of the cul de sac was performed. Later, the debridement of the scarring tissue on the cornea was done. Finally, the limbal graft was placed and covered with the amniotic membrane. The reason to use the membrane plus limbal graft was to prepare the patient for a successful cornea transplantation in the near future.

CONCLUSIONS

The amniotic membrane radiosterilized with cobalt-60 represents an effective treatment of the damaged ocular surface, as has been described with the cryopreserved membrane, but with the advantage that you

can be sure of the total absence of bacteria. In addition, the irradiated membrane does not require refrigeration, it can be stored at room temperature without any deterioration of its properties,²⁷ which facilitates its handling.

Our study demonstrates the efficiency of the amniotic membrane in persistent defects of the ocular surface which have been resistant to other treatments. As far as we know and according to the revision of the literature up to 2005, this is the first study in Mexico that has been carried out concerning diseases of the ocular surface, treated with amniotic membrane radiosterilized with cobalt-60.

ACKNOWLEDGEMENTS

We would like to thank the Instituto Nacional de Investigaciones Nucleares through the Radiosterilized Tissue Bank for its collaboration in this research.

REFERENCES

1. Charters L. The factors of growth of the amniotic membrane can be indicating of treatment. *Ophthalmology Times*; 2001; 28-32.
2. Azuara-Blanco A, Pillai CT, Dua HS. Amniotic membrane transplantation for ocular surface reconstruction. *Br J Ophthalmol* 1999; 83: 399-402
3. Davis JW. Swing transplantation with a review of 550 cases at the Johns Hopkins Hospital. *Johns Hopkins Med J* 1910; 15: 307.
4. De Roth A. Plastic repair of conjunctival defects with fetal membranes. *Arch Ophthalmol* 1940; 23: 522-525.
5. Sorsby A, Symons HM. Amniotic membrane grafts in caustic burns of the eye (second degree burns). *Br J Ophthalmol* 1940; 30: 337-345.
6. Batle JF, Perdomo FJ. Placental membranes as a conjunctival substitute. *Ophthalmol* 1993; 100-107
7. Dua HS, Gomes JAP, King AJ et al. The amniotic membrane in ophthalmology. *Survey Ophthalmol* 2004; 49: 51-77.
8. Tseng SCG, Prabhasawat P, Barton K et al. Amniotic membrane transplantation with or without limbal allografts for corneal surface reconstruction in patients with limbal stem cell deficiency. *Arch Ophthalmol* 1998; 116: 431-441.
9. Salazar EMA, Vázquez ML. Injerto de membrana amniótica para la reconstrucción de la superficie ocular. Poster presented at the XI International Course of Cornea and Refractive Surgery. 2005.
10. Martínez PME, Reyes FML, Ramos DLE, Gutiérrez SE, Carrera GJ, Marin MA. Clinical application of amniotic membranes on a patient with epidermolysis bullosa. *Ann Transplant* 1999; 4 (3-4): 68-73.
11. Martínez PME, Reyes FML. The tissue bank at the National Nuclear Research Institute in Mexico. *Cell and Tissue Banking* 2003; 4: 163-168.
12. Ley CE, Martínez PME, Román R, Oliveros LF, Canchola ME. Application of biological dressings from radiosterilized amnions with Cobalt 60 and serologic studies on the handling of burns in pediatric patients. *Ann Transplant* 2003; 8 (4): 46-49.

13. Martínez PME, Ley CE, Reyes FML, Rodríguez FP, Vázquez ML, Salazar EMA. Radiat Phys Chem 2007; 76/ 11-12, 1771-1774.
14. Shimazaki J, Shinozaki N, Tsubota K. Transplantation of amniotic membrane and limbal autograph for patients with recurrent pterygium associated with Symblepharon. Br J Ophthalmol 1988; 82: 235-240.
15. Prado-Serrano A. Alteraciones corneales en un caso de epidermólisis bulosa. Rev Mex Oftalmol 2003; 4: 153-156.
16. Chen HJ, Pires RTF, Tseng SCG. Amniotic membrane transplantation for severe neurotrophic corneal ulcers. Br J Ophthalmol 2000; 826-833.
17. International Atomic Energy Agency 2002; International Standards for Tissue Banks, Vienna.
18. International Organization for Standardization (ISO) Sterilization of health care products-radiation sterilization-substantiation of 25 kGy as a sterilization dose for small or infrequent production batches, 1996; ISO 13409, Geneva.
19. Martínez-Pardo ME, Mariano-Magaña D. The tissue bank at the Instituto Nacional de Investigaciones Nucleares: ISO 9001:2000 certification of its quality management system Cell and Tissue Banking 2006; 8: 221-231.
20. Siennicka A, Pecold-Stepniewska. Transplantation of amniotic membrane for patients with bullous keratopathy and chemical and thermal burns. Klin Oczna 2003; 105 (1-2): 41-45.
21. Dua HS. Amniotic membrane transplantation. Br J Ophthalmol 1999; 83: 748-752.
22. Madhavan HN. Preparation of amniotic membrane for ocular surface reconstruction. Indian J Ophthalmol 2002; 50 (3): 227-231
23. Adds PJ. Bacterial contamination of amniotic membrane. Br J Ophthalmol 2001; 85: 228-230.
24. Barabino S. Role of amniotic membrane transplantation for conjunctival reconstruction in ocular-cicatricial pemphigoid. Ophthalmology. 2003; 110(3):474-80
25. Khokar S. Amniotic membrane transplantation in refractory neurotrophic corneal ulcers: A randomized, controlled clinical trial. Cornea. 2005; 24 (6): 654-660.
26. Tosi GM. Amniotic membrane transplantation in ocular surface disorders. J Cell Physiol 2005; 202: 849-851.
27. Singh R. Properties of air dried processed amniotic membranes under different storage conditions. Cell Tissue Banking 2003; 4: 95-100.

Corresponding author:

Leticia Vázquez-Maya

E-mail: letivaz@yahoo.com.mx

Telephone: 2789-2000, ext. 1481