

## ANNALS OF HEPATOLOGY

Volume **2**

Number **2**




April-June **2003**

### *Artículo:*




The benefit of adding Sodium Nitroprusside (NPNa) or S-nitrosoglutathion (GSNO) to the University of Wisconsin Solution (UW) to prevent morphological alterations during cold preservation/reperfusion of rat livers

Copyright © 2003:  
Mexican Association of Hepatology

**Otras secciones de  
este sitio:**

-  [Índice de este número](#)
-  [Más revistas](#)
-  [Búsqueda](#)

***Others sections in  
this web site:***

-  [Contents of this number](#)
-  [More journals](#)
-  [Search](#)

Original article

# The benefit of adding Sodium Nitroprusside (NPNa) or S-nitrosoglutathion (GSNO) to the University of Wisconsin Solution (UW) to prevent morphological alterations during cold preservation/reperfusion of rat livers

Alejandra B. Quintana PhD,<sup>1</sup> Joaquin V. Rodriguez PhD,<sup>2</sup> Angel L. Scandizzi PhD,<sup>2</sup> Edgardo E. Guibert PhD<sup>3</sup>

## Abstract

Cold liver preservation in the University of Wisconsin solution (UW) followed by reperfusion alters hepatic parenchyma and extra cellular matrix. In this study we analyzed the benefit of adding either 500  $\mu$ M Sodium Nitroprusside (NPNa) or 100  $\mu$ M S-nitrosoglutathione (GSNO) as Nitric Oxide (NO) donors to the UW solution to prevent hepatic injury. Wistar adult rat livers were stored in UW solution (0°C) for 48Hs and reperused (60 minutes) in the isolated perfused rat liver model (IPRL). Untreated livers were used as normal controls. Livers perfused but not preserved were used as controls of reperfusion. Parenchyma damages were evaluated by Hematoxylin-Eosin stain. Picrosirius Red and Gordon-Sweets stains were used for collagen and reticulin networks, respectively. An immunohistochemistry assay for albumin was used as functional test. Cold preservation step was followed by swollen hepatocytes with "light empty halos" surrounding the nucleus, conserved hepatocyte cords and many rounded endothelial cells. The addition of NPNa or GSNO into UW solution, avoid these alterations. Livers preserved for 48 Hs and then reperused

showed extended areas of vacuolation around central veins, and many endothelial cells were rounded and located inside sinusoidal lumens. The collagen network was disorganized while the reticulin one was less altered. Albumin was distributed preferentially in pericentral areas. On the contrary, livers preserved in presence of NPNa or GSNO did not show vacuolation and both collagen and reticulin networks were unchanged. Albumin was more homogeneously distributed in both groups. In conclusion, the addition of 500  $\mu$ M NPNa or 100  $\mu$ M GSNO as a NO donor, improves UW solution properties to preserve rat livers by maintaining the hepatic morphology and avoiding hepatic injury post-cold preservation/reperfusion.

**Key words:** Cold preservation; UW solution; nitric oxide donors, ischemia/reperfusion injury, liver morphology.

## Introduction

The University of Wisconsin solution (UW) has extended the scope and application of liver transplantation therapy.<sup>1</sup> However, reperfusion of livers exposed to variable ischaemia time period during hepatic surgery can cause severe injury to hepatic tissue.<sup>2</sup> Direct effects of cold ischaemia on livers produces cell swelling, interstitial edema, denudation of the sinusoidal lining cells by alterations in connections between cells and extra cellular matrix<sup>3,4</sup> and activation of proteases.<sup>5,6</sup> Extra cellular matrix damages cause changes on parenchymal and nonparenchymal cell morphology. Hepatic injury is further aggravated by disturbances of hepatic microvascular blood flow in the postischemic period that may be a consequence of nonparenchymal cell damage. These alterations increase vascular resistance, impeding the appropriate oxygen transport and delivery of nutrients from blood to hepatocytes. This phenomenon always precedes hepatocyte injury, suggesting that abnormalities in microcirculation could play a primary role in the pathogenesis of the graft nonfunction.<sup>7</sup>

Microcirculatory blood flow is modulated by vasoactive substances, such as Nitric Oxide (NO) and Endothelins.<sup>2</sup> Al-

<sup>1</sup> Morfología, Departamento de Ciencias Biológicas.

<sup>2</sup> Farmacología, Departamento de Ciencias Fisiológicas.

<sup>3</sup> Biología Molecular, Departamento de Ciencias Biológicas, Facultad de Ciencias Bioquímicas y Farmacéuticas, Universidad Nacional de Rosario, Suipacha 531 (S2002LRK) Rosario, Argentina.

## Address for correspondence:

Dr. Edgardo E. Guibert, Biología Molecular, Dto. Cs. Biológicas, Fac. de Cs. Bioquímicas y Farmacéuticas, UNR, Suipacha 531 (S2002LRK) Rosario, Argentina.  
Phone: 0054-341-4393400  
Fax: 0054-341-4804601

E-mail: eguibert@fbioyf.unr.edu.ar

J.V.R. and E.E.G. are members of The National Council of Research (CONICET), Argentina.

Abbreviations: UW: University of Wisconsin; NO: nitric oxide; NPNa: sodium nitroprusside; GSNO: S-nitrosoglutathione; KH: Krebs-Henseleit bicarbonate buffer; IPRL: isolated perfused rat liver.

teration of intrahepatic concentrations of vasoconstrictors and vasodilators during reperfusion could therefore be responsible for postischemic impairment of hepatic blood flow.<sup>8</sup>

S-nitrosothiols are important NO donors, which exhibit endothelin, derived relaxing factor-like properties<sup>9</sup> and have effects on vascular smooth muscle. S-nitrosoglutathione (GSNO) is a S-nitrosothiol that has proved to relax tracheal smooth muscle.<sup>10</sup> Aside from its use as organic synthesis reagent, GSNO is of interest because its potent pharmacological properties and possible physiological role in smooth muscle relaxation like other NO donors such as Sodium Nitroprusside (NPNa).<sup>10,11</sup> Meanwhile, NPNa is a potent vasodilator that releases NO by a non-enzymatic process and it acts as a direct vasodilator independent from endothelial function.<sup>12,13</sup>

In previous works we demonstrated that the addition of 100  $\mu$ M GSNO or 500  $\mu$ M NPNa to the UW solution, as NO donors, improved the morphology of rat livers cold preserved in UW solution during 48 Hs at 0°C and then reperused using the Isolated Perfused Rat Model (IPRL).<sup>11,14</sup>

The purpose of this work was to compare the benefit of adding 100  $\mu$ M GSNO or 500  $\mu$ M NPNa to the UW solution and to determinate which of this two NO donors is more suitable to avoid preservation/reperfusion injuries on rat livers morphology when they are cold preserved in UW solution (48 Hs-0°C) and then reperused using de IPRL model.

## Materials and methods

### Animals

Adult male Wistar rats weighing 250-350 g were used for this study. Animals had free access to standard rat chow and tap water, and were not fasted before surgery. All operations were performed between 9 AM and noon. The experiments described in this report were conducted according to international regulations and approved by the National Council of Research in Argentina (CONICET).

### Solutions

The UW solution used in this study was modified<sup>11</sup> based on the UW solution described by Beltzer.<sup>15</sup> The composition of the modified UW solution was as follows: 100 mM Lactobionic Acid, 25 mM  $\text{KH}_2\text{PO}_4$ , 5 mM  $\text{MgSO}_4$ , 30 mM Raffinose, 5 mM Adenosine, 1 mM Allopurinol, 3 mM Glutathione (GSH), 0.25 mg/mL Streptomycin and 10 UI/mL Penicillin G. GSH was added to UW solution before use, UW solution was brought to pH 7.40 at 25°C with 5 M KOH. The final  $\text{Na}^+$  and  $\text{K}^+$  concentrations were 30 mM and 125 mM, respectively. The solution was bubbled with 100%  $\text{N}_2$  for 15 min at 0°C before use.<sup>16</sup> Hydroxyethyl Starch, Dexametasone and Insulin were omitted with respect to the commercial solution, because their roles are still controversial.<sup>17</sup> GSNO or

NPNa was dissolved in a small volume of distillate water and added to UW solution immediately before use.

Composition of perfusate Krebs-Henseleit bicarbonate buffer (KH)–bovine serum albumin: the synthetic medium consisted in 2 % bovine serum albumin (Sigma A 4503) in KH with the following composition: NaCl 118 mM, KCl 4.8 mM,  $\text{NaHCO}_3$  25 mM,  $\text{KH}_2\text{PO}_4$  1.2 mM,  $\text{MgSO}_4$  1.2 mM,  $\text{CaCl}_2$  1.5 mM, Heparin 2 UI/mL and Glucose 5 mM. The final pH of the KH solution after equilibration with carbogen ( $\text{O}_2:\text{CO}_2$ , 95:5 %) was 7.40. The perfusate was filtered through a 1.5  $\mu$ m glass fiber filter before use.

### Hepatectomy and cold storage

The rats were anesthetized with sodium tiopental (50 mg/Kg, *i.p.*) and livers prepared according to the standard technique.<sup>18</sup> In brief, the bile duct was cannulated with a PE-50 catheter (Intramedic USA) and 0.2 mL of saline containing 500 UI of Heparin (Abbot, Argentina) was injected into the femoral vein. The portal vein was cannulated with a large catheter 14 G (2.10 mm internal diameter) and the hepatic artery were ligated. The liver was perfused with oxygenated KH buffer (37°C) at a flow of 15 mL/min. The suprahepatic inferior vena cava was then cannulated with a polyethylene tubing (3 mm internal diameter) and the liver was removed without stopping the perfusion. In the control group the perfusion was performed immediately, whereas in the experimental groups the livers were flushed-out with 30 ml of cold UW solution for approximately 2 min and then transferred to a vessel containing the preservation solution maintained at 4°C. At the end of this procedure, the livers were cold stored at 0°C for 48 hours.

### Chemicals

GSNO was prepared according to the method of Hart<sup>19</sup> by incubating equimolar amounts of glutathione and sodium nitrite in acidified water at 0°C. GSNO solutions were freshly prepared before each experiment from GSNO powder conserved at 4°C under vacuum. Preparation quality and concentration of GSNO was spectrophotometrically determined at 335 nm ( $\epsilon = 826 \text{ dm}^3 \text{ mol}^{-1} \text{ cm}^{-1}$ ) and at 545 nm ( $\epsilon = 17.4 \text{ dm}^3 \text{ mol}^{-1} \text{ cm}^{-1}$ ). NPNa was purchased from Merck (AG, Germany).

### The perfusion system

The livers were perfused using a recirculating system modified from Alexander et al.<sup>20</sup> as we described previously.<sup>11,21,22</sup>

### Histological studies

To evaluate histological changes produced during cold preservation/reperfusion, pieces of livers were taken from each experimental group (n = 5). Tissues were fixed in 4%

PBS buffered formalin (pH = 7.40) and embedded in paraffin. Sections were cut at 5  $\mu$ m thick and processed as follows:

- Hematoxilin-eosin stain was performed to evaluate hepatocyte cords integrity; presence of vacuoles, blebs and necrotic focus; sinusoidal endothelial cells shape; and the morphological aspect of the hepatic lobules.
- Picrosirius red stain was used to analyze the collagen network.<sup>23</sup>
- Gordon-Sweet stain was used to analyze the reticulin network.<sup>24</sup>
- Immunohistochemistry for albumin was done to study the content of hepatocyte albumin after cold preservation/reperfusion as a parameter of viability for parenchymal cells. Immunohistochemistry was performed using an antibody against albumin (Serotec-UK) as we described previously.<sup>14</sup> Briefly, paraffin sections were prepared and microwaved for antigen recover (800 W, 4'30", temperature lower than 85°C) in citrate buffer pH = 6.00, and cooled under tap water. Liver sections were then incubated with anti-albumin (diluted 1:2,000) after nonspecific binding was blocked with 5% non-fat milk in buffer TBS, for 40 min in hummed chamber at room temperature. After incubation with ABC system (Vector Laboratories, USA), sections were incubated with Fast Red solution at 37°C for 25 minutes according to manufacture directions, counterstained with Hematoxylin and mounted with glycerol buffered.

### Experimental group

#### Controls:

- I) normal controls consisted in livers neither preserved nor reperfused (**I<sub>C</sub>**);
- II) reperfusion controls, in which hepatectomy was immediately followed by the organ perfusion in the IPRL model during 60 min (**II<sub>RC</sub>**)

#### Preserved groups:

To study the effect of GSNO and NPNa added to UW solution on liver morphology during cold preservation we analyzed the following groups:

- III) Livers cold preserved during 48 Hs at 0°C in UW solution (**III<sub>P48</sub>**);
- IV) Livers cold preserved during 48 Hs at 0°C in UW solution with the addition of 500 mM NPNa (**IV<sub>PNPNa</sub>**);
- V) Livers cold preserved during 48 Hs at 0°C in UW solution with the addition of 100  $\mu$ M GSNO (**V<sub>PGSNO</sub>**);

#### Reperfused groups:

To investigate the effect of cold preservation followed by reperfusion we analyzed the following groups:

- VI) Livers cold preserved (0°C-48 Hs) in UW solution and then reperfused (**VI<sub>P/R48</sub>**);
- VII) Livers cold preserved (0°C-48 s) in UW solution with 500  $\mu$ M NPNa and then reperfused (**VII<sub>P/RNPNa</sub>**);
- VIII) Livers cold preserved (0°C-48 Hs) in UW solution with 100  $\mu$ M GSNO and then reperfused (**VIII<sub>P/RGSNO</sub>**).

## Results

### Hematoxilin-eosin stain

#### Controls

Group **I<sub>C</sub>** was used to compare the histology of normal livers with the hepatic morphology of treated groups (preserved and preserved/reperfused) (*Figure 1a*). In group **II<sub>RC</sub>** we observed the presence of few vacuoles around central veins, sinusoid lumens appeared wider than in group **I<sub>C</sub>** and some sinusoidal endothelial cells showed rounded shape, hepatocytes cords were not disorganized and no necrotic focus or great damages were seen within the hepatic lobule. Morphological alterations of this group represented the damages caused on hepatic structure by the IPRL system itself (*Figure 1b*).

#### Preserved groups:

The morphology of group **III<sub>P48</sub>** showed swollen hepatocytes with "light empty halos" surrounding the nucleus but the hepatocyte cords were conserved. Sinusoids had a greater diameter than the ones of group **I<sub>C</sub>** and many rounded sinusoidal endothelial cells were seen (*Figure 1c*).

In group **IV<sub>PNPNa</sub>** alterations seen in group **III<sub>P48</sub>** were avoided significantly. While the "light empty halos" disappeared, the other alteration were present (*Figure 1e*). The same results were obtained for group **V<sub>PGSNO</sub>** (*Figure 1g*).

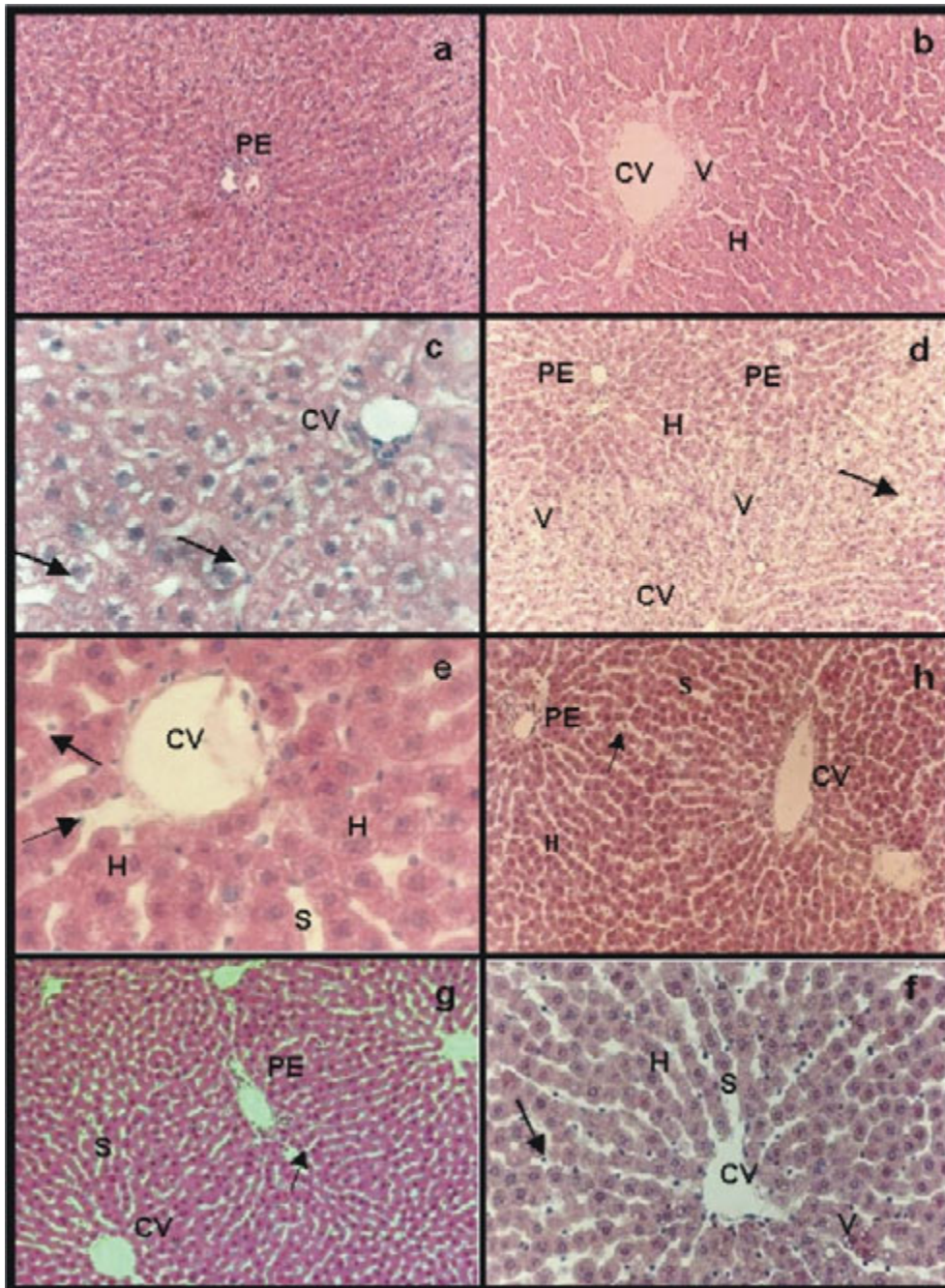
#### Reperfused groups:

Group **VI<sub>P/R48</sub>** showed extended areas of vacuolation around central veins with portal areas without vacuoles. Hepatocytes were swollen but hepatocyte cords integrity was preserved. Sinusoidal endothelial cells were all rounded and most of them appeared inside sinusoidal lumen (*Figure 1d*).

In group **VII<sub>P/RNPNa</sub>** not vacuolation was seen, and less endothelial cells were inside sinusoidal lumen. Nevertheless, most endothelial cells appeared rounded and sinusoid were dilated. The parenchyma was organized and most conserved than in group **VI<sub>P/R48</sub>** (*Figure 1f*).

The only difference between group **VII<sub>P/RNPNa</sub>** and group **VIII<sub>P/RGSNO</sub>** (*Figure 1h*) was that the last group pre-





**Figure 1:** Hematoxylin-eosin stain: **a)** group  $I_C$ , normal parenchyma around a portal space (PE); **b)** group  $II_{RC}$ , small area of vacuolation (V) around central vein (CV). Sinusoids appeared wider than in normal controls (S); **c)** group  $III_{P48}$ , swollen hepatocytes with “light empty halos” surrounding the nucleus (arrows) and sinusoids with a greater caliber than the ones of group  $I_C$  (S); **e)**  $IV_{PNPNa}$  and **g)** group  $V_{PGSNO}$ , in both groups “light empty halos” disappeared while sinusoids presented wider caliber than controls (S), swollen hepatocytes (H) and some rounded endothelial cells were seen (arrows); **d)** group  $VI_{P/R48}$ , extended areas of vacuolation (V) around central veins (CV) with portal areas (PE) without vacuoles. Hepatocytes were swollen (H). Sinusoidal endothelial cells were all rounded and most of them appeared inside sinusoidal lumen (arrow); **f)** group  $VII_{P/RNPNa}$  and **h)** group  $VIII_{P/RGSNO}$ , less endothelial cells were inside sinusoidal lumen (arrows), sinusoid were dilated (S). The only difference between group  $VII_{P/RNPNa}$  and group  $VIII_{P/RGSNO}$  (Figure 1h) was that the last group presented few vacuoles (V) around central veins with normal portal areas. Magnifications: a, b, d, h, g: 41x, f: 83x and e, c: 165x.

sented few vacuoles around central veins with normal portal areas.

### Picrosirius red and Gordon-Sweet stains

#### Controls

Group  $I_C$  showed networks of collagen (Figure 2a) and reticulin (Figure 2f) organized with abundant fibers. Group  $II_{RC}$  presented certain disorganization of both collagen (Figure 2b) and reticulin (Figure 2g) networks and apparently with less fibers compared with group  $I_C$ .

#### Preserved groups

Groups  $III_{P48}$ ,  $IV_{PNPNa}$  and  $V_{PGSNO}$  had no relevant differences of collagen and reticulin networks compared with group  $I_C$  (data not shown).

#### Reperfused groups

Group  $VI_{P/R48}$  presented disorganized networks of collagen with fewer fibers than group  $I_C$  (Figure 2c). Reticulin network was more organized but the amount of fibers seemed to be diminished compared with  $I_C$  (Figure 2h).



Groups **VII**<sub>P/RNPNa</sub> had organized networks of collagen (*Figure 2d*) and reticulin (*Figure 2i*) and the amount of fibers were similar to group **I**<sub>C</sub>. The same results were obtained for group **VIII**<sub>P/RGSNO</sub>. (*Figure 2e*, collagen; *Figure. 2j*, reticulin).

### Immunohistochemistry for albumin

#### Controls

In group **I**<sub>C</sub> albumin appeared homogeneously distributed within the hepatic lobules (data not shown). Group **II**<sub>RC</sub> showed less amount of albumin, which was more abundant around central veins and portal areas (*Figure 3a*).

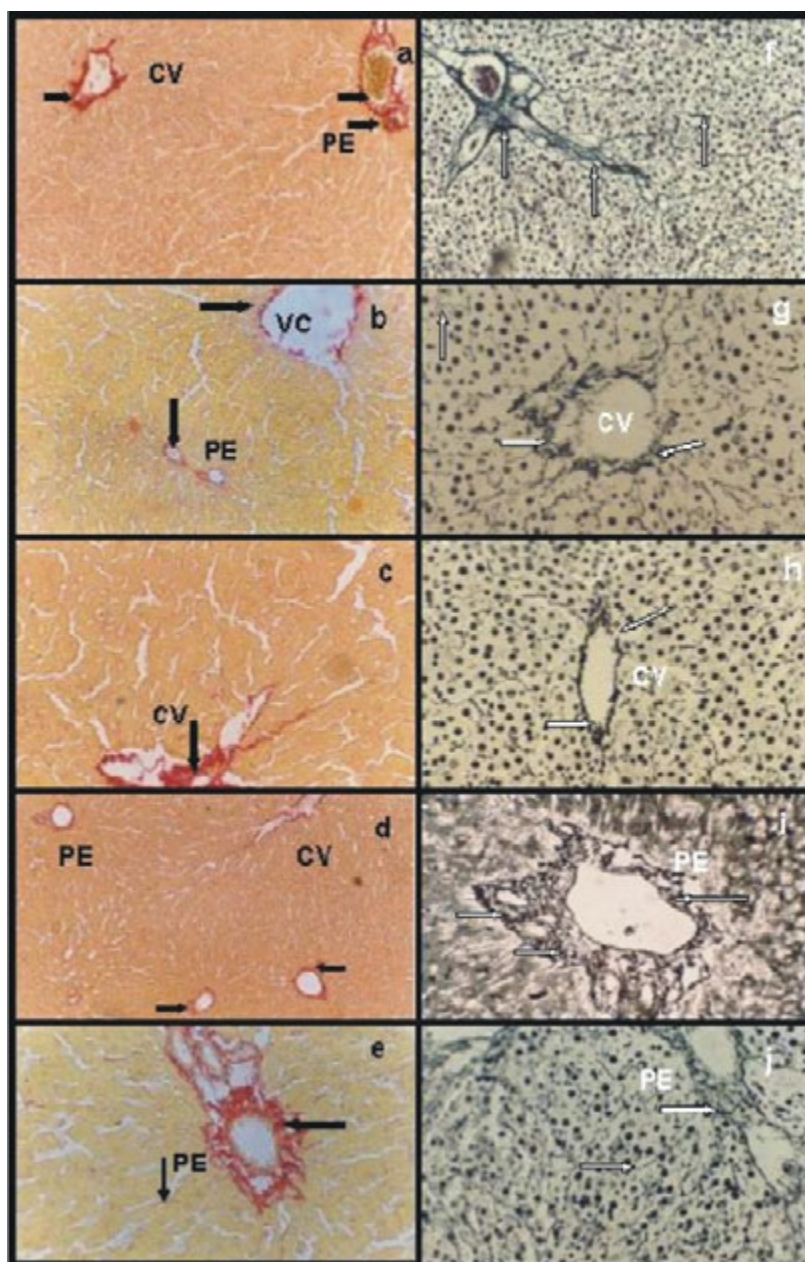
#### Preserved groups

Groups **III**<sub>P48</sub>, **IV**<sub>P/NPNa</sub> and **V**<sub>P/GSNO</sub> had no differences compared with group **I**<sub>C</sub> (data not shown).

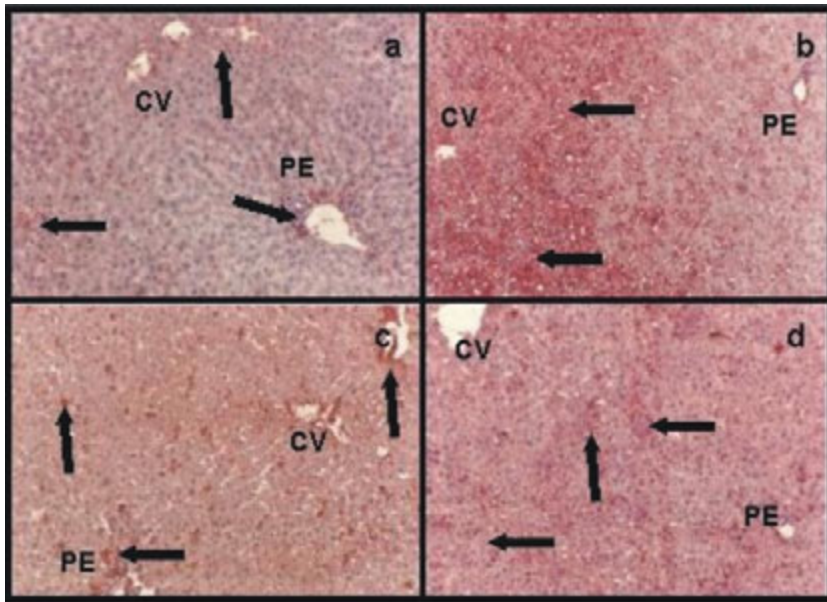
#### Reperfused groups

Group **VI**<sub>P/R48</sub> showed a heterogeneous distribution of albumin within the hepatic lobule. The great amount of albumin was present in pericentral areas and de less amount in periportal ones (*Figure 3b*).

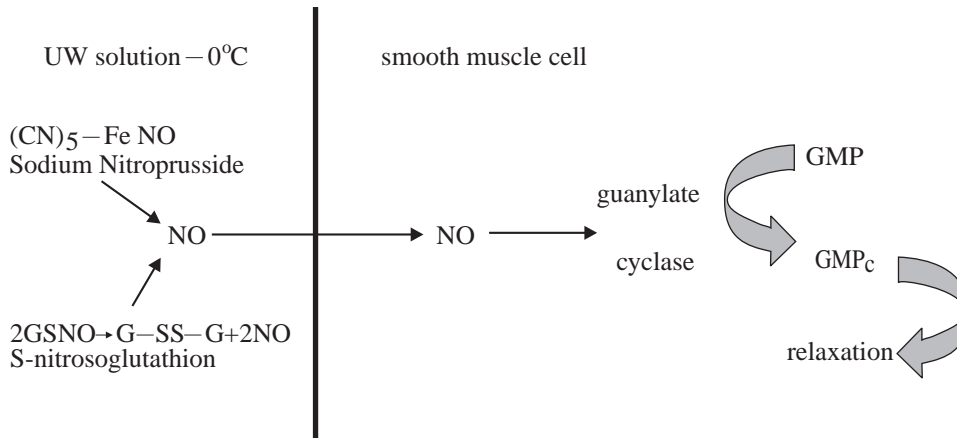
Groups **VII**<sub>P/RNPNa</sub> (*Figure 3c*) and **VIII**<sub>P/RGSNO</sub> (*Figure 3d*) had no differences for albumin distribution within the



**Figure 2:** Picrosirius red stain: **a)** group **I**<sub>C</sub>, abundant and organized network of collagen type I and III around a portal space (PE) and central vein (CV) (arrows); **b)** group **II**<sub>RC</sub>, certain disorganization of both collagen network and apparently with less fibers compared with group **I**<sub>C</sub> (arrows); **c)** group **VI**<sub>P/R48</sub>, disorganized networks of collagen with less fibers than group **I**<sub>C</sub> (arrow); **d)** group **VII**<sub>P/RNPNa</sub> and **e)** group **V**<sub>P/GSNO</sub>. Groups **VII**<sub>P/RNPNa</sub>, both groups had organized networks of collagen and the amount of fibers were similar to group **I**<sub>C</sub>. **Gordon-Sweet stain:** **f)** group **I**<sub>C</sub>, abundant and organized network of reticulin around a portal space (PE) and within the entire parenchyma (arrows); **g)** group **II**<sub>RC</sub>, Group **II**<sub>RC</sub> certain disorganization of reticulin network and apparently with less fibers compared with group **I**<sub>C</sub> (arrows); **h)** group **VI**<sub>P/R48</sub>, reticulin network was more organized around central veins (CV) and portal areas, but the amount of fibers seemed to be diminished compared with **I**<sub>C</sub> (arrows); **i)** group **VII**<sub>P/RNPNa</sub> and **j)** group **VIII**<sub>P/RGSNO</sub>, both groups presented an organized networks reticulin around portal areas (PE) and central veins, and the amount of fibers were similar to group **I**<sub>C</sub> (arrows). Magnifications: a, b, d, f, j: 41x; c, e, h, i: 83x.



**Figure 3:** Immunohistochemistry for albumin: **a)** group  $\text{II}_{\text{RC}}$ , less amount of albumin than in normal controls which was more abundant around central veins (CV) and portal areas (PE); **b)** group  $\text{VI}_{\text{P/R48}}$ , an heterogeneous distribution of albumin within the hepatic lobule. The great amount of albumin was present in pericentral areas (CV) and the less amount in periportal ones (PE) (arrows); **c)** group  $\text{VII}_{\text{P/RNPNa}}$  and **d)** group  $\text{V}_{\text{P/RGSNO}}$ , both groups had no differences for albumin distribution within the hepatic parenchyma. Albumin was more homogeneous distributed than in group  $\text{VI}_{\text{P/R48}}$  (arrows). Magnification: 41x.



**Figure 4:** NPNa donates NO to UW solution by a nonezymatic process;<sup>12,13</sup> meanwhile GSNO is oxidized to G-SS-G releasing NO to UW solution.<sup>29</sup> NO can diffuse through cells cytoplasmatic membranes easily. NO generated in UW solution from NPNa or GSNO enters the smooth muscle cells and activates guanylate cyclase to transform GMP to GMP $_c$ . The last compound produces relaxation.<sup>30</sup>

hepatic parenchyma. Albumin was more homogeneous distributed than in group  $\text{VI}_{\text{P/R48}}$ .

## Discussion

Ischemia causes morphological alterations on livers cold preserved in UW solution (48 Hs  $-0^{\circ}\text{C}$ ). Reperfusion with the IPRL model after cold preservation aggravates these damages.<sup>11,14</sup> Cold preservation of rat livers in UW solution for 24 Hs is not a severe condition leading to primary liver non-function. Longer periods of cold preservation should be used when studying the hepatophysiologic mechanisms involved in the cold-ischemia injury of rat liver.<sup>25</sup> In previous studies we hence demonstrate that rat livers stored in UW solution up to 48 Hs shown severe morphological and hemodynamics alterations indicating that 48 Hs is the timeline to preserve rat livers under hypoxia and hypothermia.<sup>11,14,21,22</sup> However, these alterations could be reversed by adding 500  $\mu\text{M}$  NPNa<sup>11</sup> or 100  $\mu\text{M}$  GSNO.<sup>14,22</sup>

Morphological alterations of parenchymal and non-parenchymal cells (hepatocytes and endothelial cells) seen in group  $\text{III}_{\text{P48}}$  represented long term of hypothermic preservation (48 Hs) under hypoxia. Swollen hepatocytes and disruption of the endothelial cell line are described as ones of the primary injuries seen during cold preservation of livers in UW solution.<sup>3,4</sup> These alterations were observed in group  $\text{III}_{\text{P48}}$  and in addition, perinuclear “light empty halos” were also seen in all hepatocytes within the hepatic lobule. This halos were not present when 500  $\mu\text{M}$  NPNa or 100  $\mu\text{M}$  GSNO was added to UW solution. This phenomenon might represent reversible alterations characteristic of cold preservation and hypoxia.

Groups  $\text{IV}_{\text{PNPNa}}$  and  $\text{V}_{\text{PGSNO}}$  improved liver morphology, diminishing the alterations seen in group  $\text{III}_{\text{P48}}$ . The improvement of UW solution with the addition of NO donors in an adequate concentration had been proved previously.<sup>11,14</sup> In this study we demonstrate that the addition of 500  $\mu\text{M}$  NPNa or 100  $\mu\text{M}$  GSNO avoided parenchymal

and nonparenchymal cells morphology damages during cold preservation under our experimental conditions (48 hs-0°); no differences between both NO donor in preventing preservation/reperfusion injuries could be established with our results.

Collagen and reticulin networks were not significantly altered in preserved groups. This finding might be due to the fact that during cold preservation, proteases are activated<sup>5,6</sup> and the damages produced by this phenomenon are clearly manifested after reperfusion.

After long terms of hypoxia, reoxygenation during reperfusion causes an increment of superoxide anion concentration, especially in middle zones of the hepatic lobule, producing superoxide-mediated cytotoxicity.<sup>26,27</sup> This could explain the extended vacuolated areas seen around central veins and middle zones, with normal portal areas, observed in group VI<sub>P/R48</sub>. Livers of this group showed more albumin distribution around perivenous hepatocytes rather than in periportal areas. Since perivenous hepatocytes were the ones that showed their cytoplasm full of vacuoles, it could be assumed that these cells were damaged and could be the first to lose viability. Nevertheless, the content of albumin was higher than in hepatocytes of portal areas where no vacuolation was seen. These results allow us to conclude that albumin secretion is not appropriate to estimate hepatocyte viability after cold preservation/reperfusion period. Collagen and reticulin networks were disorganized comparing with group I<sub>C</sub>. This could be related to protease activation.<sup>5,6</sup> Matrix metalloproteinases, particularly metalloproteinases 2 and 9, are activated during cold preservation.<sup>6</sup> Since collagen type I is one of matrix metalloproteinase 2 substrate,<sup>28</sup> it seems possible that the activation of these metalloproteinase during cold preservation induced collagen and reticulin network disorganization and sinusoidal endothelial cell detachment which is more evident after reperfusion.

During cold preservation there is an increment of endothelins due to hypoxia and this phenomenon produces vasoconstriction. In addition, the high concentration of potassium in UW solution aggravates this phenomenon.<sup>11</sup> To improve hepatic hemodynamic and morphology during cold preservation in UW solution (0°C-48 Hs) following by reperfusion, GSNO or NPNa was added.<sup>11,14,22</sup> These compounds can generate NO, which is vasodilator that produces relaxation on smooth muscle cells according to the reactions shown in figure 4.

The addition of NPNa or GSNO reversed many morphological alterations seen in group VI<sub>P/R48</sub>. There were no significant differences among the results obtained with both NO donors and we assumed that either NPNa or GSNO is suitable as a UW solution component to avoid cold preservation/reperfusion injuries. Nonetheless, GSNO has a physiological mechanism to generate and storage NO in cells. S-nitrosothiols are present in cells and they can promote relaxation naturally. Accordingly, we suggest that GSNO could be a better additive for UW

solution to prevent hepatic morphological alteration during cold preservation/reperfusion rather than NPNa.

## Acknowledgments

The authors acknowledge Histotechnologist Alejandra Inés Martínez for her excellent technical assistance. This study was supported by the Agencia Nacional de Promoción Científica y Tecnológica (ANPCyT) of República Argentina. PICT – 05-06434, BID 1201 OC/AR

## References

1. Lemasters JJ and Thurman RG. Perfused Liver. Hypoxic, Ischaemic and Preservation-Induced Injury. In: Ballet F and Thurman RG, eds. *Perfused Liver. Clinical and Basic Applications*. London: John Libbey, 1991; 97-120.
2. Koeppel TA, Gebhard MM, Otto G, Post E. Inhibition of Nitric Oxide Synthesis in Ischaemia/Reperfusion of the Rat Liver is followed by Impairment of Hepatic Microvascular Blood Flow. *J Hepatol* 1997; 27: 163-169.
3. Clavien PA. Sinusoidal Endothelial Cell Injury during Hepatic Preservation and Reperfusion. *Hepatology* 1998; 28: 281-285.
4. Müller AR, Platz KP, Heckert C, Häusler M, Guckelberger O, Schuppan D, Lobeck H, et al. The Extracellular Matrix: an early target after small bowel Transplantation. *Transplantation* 1998; 65: 6 770-776.
5. Li XK, Matin AFM, Suzuki H, Uno T, Yamaguchi T and Harada Y. Effect of Protease Inhibitor on Ischemia/Reperfusion Injury of the Rat Liver. *Transplantation* 1993; 56: 1331-1336.
6. Upadhyay AG, Harvey RPC, Howard TK, Lowell JA, Shenoy S, Strasberg SM. Evidence of a Role for Matrix Metalloproteinases in Cold Preservation Injury of the Liver in Humans and in the Rat. *Hepatology* 1997; 26: 922-928.
7. Churchill TA, Green CJ, Fuller BJ. Protective Properties of Amino Acids in Liver Preservation: Effects of Glycine and a Combination of Amino Acids on Anaerobic Metabolism and Energetics. *J Hepatol* 1995; 23: 6 720-726.
8. Stansby G, Fuller B, Jeremy J, Cheetan K, Roller K. Endothelin Release. A Facet of Reperfusion Injury in Clinical Liver Transplantation. *Transplantation* 1993; 56: 239-240.
9. Ignarro LJ, Lippton H, Edwards JC, Barilos WH, Hyman AL, Kadowitz PJ, Gruetter CA. Mechanism of Vascular Smooth Muscle Relaxation by Organic Nitrates, Nitrites, Nitroprusside Oxide. *J Pharmacol Exp Ther* 1981; 218: 739-749.
10. Rodney Mathews W and Kerr SW. Biological Activity of S-Nitrosothiols: The Role of Nitric Oxide. *J Pharmacol Exp Ther* 1993; 267 3: 1529-1537.
11. Rodriguez J, Guibert E, Quintana A, Scandizzi A, Almada L. The Role of Sodium Nitroprusside in the Improvement of Rat Liver Preservation in University of Wisconsin Solution. A Study in the Isolated Perfused Liver Model. *J Surg Res* 1999; 87: 201-208.
12. Feelisch M, Noack E. Correlation between nitric oxide formation during degeneration of organic nitrate and activation of guanylate cyclase. *Eur J Pharmacol* 1987; 139(1): 19-30.
13. Fullerton DV, Mitchell MV, McIntyre RC. Cold ischemia and reperfusion each produce pulmonary vasomotor dysfunction in the transplanted lung. *J Thorac Cardiovasc Surg* 1993; 106: 1213-1217.
14. Quintana A, Rodriguez J, Scandizzi A, Guibert E. Effect of S-nitrosoglutathione (GSNO) Added to the University of Wisconsin Solution (UW): I) Morphological Alteration During Cold Preservation/Reperfusion of Rat Liver. I. *Journal of Surgical Investigation* 2001; 2: 401-411.
15. Belzer FO and Southard JH. Principles of Solid Organ Preservation by Cold Storage. *Transplantation* 1988; 45: 673-676.
16. Mamprin ME, Rodriguez JV, Guibert EE. The Importance of pH in Resuspension Media on Viability of Hepatocytes Preserved in University of Wisconsin Solution. *Cell Transplant* 1995; 4(3): 269-274.



17. Chazouillieres O, Calmus Y, Vaubordolle M, Ballet F. Preservation-Induced Liver Injury. Clinical Aspects, Mechanism and Therapeutic Approaches. *J Hepatol* 1993; 18: 123-134.
18. Miller LL. The technique of Isolated Rat Liver Perfusion. In: I. Bartosek, A. Guatain, LL. Miller, eds. *Isolated Liver Perfusion and Its Applications*. New York: Raven Press, 1973: 11-52.
19. Hart TW. Some Observation Concerning S-nitroso and S-phenylsulfonyl Derivatives of L-cysteina and glutathione. *Tetrahedron Lett* 1985; 26: 2013-2016.
20. Alexander B, Aslarn M, Benjamin IS. Hepatic Function During Prolonged Isolated Rat Liver Perfusion Using a New Miniaturized Perfusion Circuit. *J Pharmacol Toxicol Methods* 1995; 34(4): 203-210.
21. Almada LL, Scandizzi AL, Guibert EE, Furno G, Rodriguez JV. Biliary Inorganic Phosphate as a Tool for Assessing Cold Preservation-Reperfusion Injury: A Study in the Isolated Perfused Rat Liver Model. *Liver Transplantation* 2003; 9(2):160-169.
22. Quintana AB, Lenzi HL, Almada LL, Scandizzi AL, Furno G, Rodríguez JV, Guibert EE. Effect of S-Nitrosoglutathione (GSNO) added to the University of Wisconsin Solution (UW): II) Functional Response to Cold Preservation/Reperfusion of Rat Liver. *Ann Hepatol* 2002; 1(4): 183-191.
23. Junqueira LCU, Bignolas G and Bretani R. Picrosirius Staining plus Polarization Microscopy, a Specific Method for Collagen Detection in Tissue Section. *Histochem J* 1979; 11: 447-455.
24. Lynch MJ, Raphael SS, Mellor LD, Spare PD, Inwood MJH. *Medical Laboratory Technology and Clinical Pathology*. Philadelphia: W. B. Saunders Company. 1969: 1113-1114.
25. Urata K, Nguyen B, Brault A, Lavoie J, Rocheleau B, Huet PM. Decreased survival in rat liver transplantation with extended cold preservation: Rol of portal vein clamping time. *Hepatology* 1998; 28: 366-373.
26. Huet PM, Kassissia I, Semret M. Haemodynamics. In: Ballet F, Thurman RG, eds. *Perfused Liver. Clinical and Basic Applications*. London: John Libbey 1991: 33-42.
27. Weiss RH and Riley DP. Uses of Inorganic Chemistry in Medicine in: Farrell NP, ed. *Therapeutic Aspects of Manganese (II)-based Superoxide Dismutase Mimics*. Royal Society of Chemistry. Perfusion Circuit. *J Pharmacol Toxicol Met* 1999; 34: 203 - 210.
28. Shapiro SD. Matrix metalloproteinase degradation of extracellular matrix: biological consequences. *Current Opinion in Cell Biology* 1998; 10: 602-608.
29. Turpaev KT. Nitric Oxide in Intercellular Communication. *Mol Biol* 1998; 32 (4): 475-484.
30. Ignarro LJ. Endothelium-derived nitric oxide: pharmacology and relationship to the actions of organic nitrate esters. *Pharm Res* 1989; 6(8): 651-659.