

ANNALS OF HEPATOLOGY

Volume 2

Number 2

April-June 2003

Artículo:

Microhamartomas (Von Meyenburg Complexes)

Copyright © 2003:
Mexican Association of Hepatology

**Otras secciones de
este sitio:**

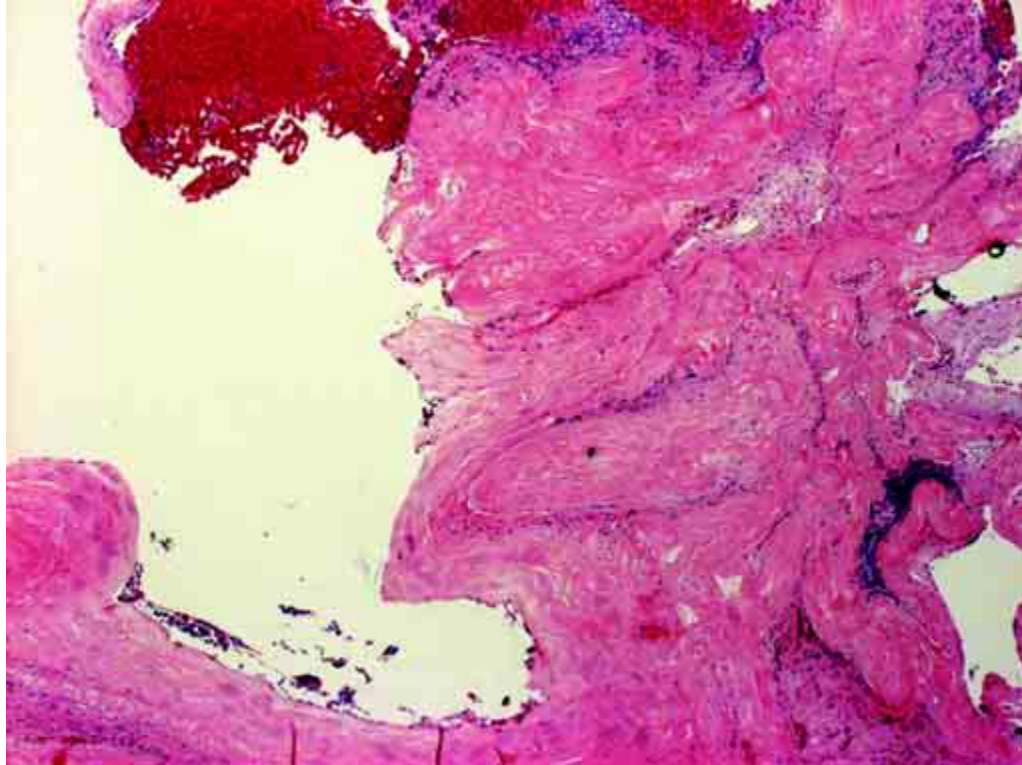
- 👉 [Índice de este número](#)
- 👉 [Más revistas](#)
- 👉 [Búsqueda](#)

***Others sections in
this web site:***

- 👉 [Contents of this number](#)
- 👉 [More journals](#)
- 👉 [Search](#)

Images in Hepatology

Microhamartomas (Von Meyenburg Complexes)



A 69-year-old man, with a long history on diabetes mellitus, controlled with oral hypoglycemic agents and hypertension controlled with Enalapril. He was fine until one month before admission when he suddenly presented weakness, complaining of right upper quadrant abdominal pain, chills, fever, and jaundice. On admission, the temperature was 36.1°C, the pulse was 92, and the respirations were 24. The blood pressure was 130/90 mm Hg. he had a white cell count $8.5 \times 10^9/L$ with 65% neutrophils. His hematocrit was 42.4%, with a mean corpuscular volume of $86.9 \mu m^3$ and a platelet count of $329/mm^3$, and glucose 119 mg/dL, amylase 776 U/L, Lipase 764 U/L, and abnormal liver-function test: protein 7.01 g/dL, albumin 3.51 g/dL, total bilirubin 3.60 mg/dL, conjugated 1.94 mg/dL, Alkaline phosphatase 186 U/L, Aspartate aminotransferase 160 U/L, Alanine aminotransferase 291 U/L. Abdominal ultrasound with stones in the gallbladder, and normal diameter of the bile ducts. Two days later a laparoscopic cholecystectomy and liver biopsy were performed.

The liver biopsy showed microhamartomas (Von Meyenburg Complexes), Figure. These findings are considered to be a part of the spectrum of adult polycystic liver disease. The lesions are small and usually multiple grayish with or green. Each complex is composed of cystically dilated bile ducts lying in a fibrous tissue stroma.

Nahum Méndez-Sánchez MD, PhD, Raúl Pichardo-Bahena, MD, Misael Uribe, MD

Departments of Biomedical Research, Pathology and Liver Unit.
Medica Sur Clinic & Foundation Mexico City 14050 Mexico