

ANNALS OF HEPATOLOGY

Volume 2

Number 2

April-June 2003

Artículo:

Hepatic *Echinococcus granulosus*. A Case report

Copyright © 2003:
Mexican Association of Hepatology

**Otras secciones de
este sitio:**

- 👉 [Índice de este número](#)
- 👉 [Más revistas](#)
- 👉 [Búsqueda](#)

***Others sections in
this web site:***

- 👉 [Contents of this number](#)
- 👉 [More journals](#)
- 👉 [Search](#)

Case Report

Hepatic *Echinococcus granulosus*. A Case report

Nahum Méndez-Sánchez, MD, PhD,¹ Reyna Vega, MD,¹ Rubén Cortés, MD,² Roberto Corona, MD,³
Raúl Pichardo-Bahena, MD,⁴ Misael Uribe, MD,¹

Abstract

A 32-year-old woman was admitted to hospital complaining of right upper quadrant and epigastrium abdominal pain, and nausea. On routine physical examination an abdominal mass was discovered on the right upper quadrant. Liver tests were normal. Magnetic resonance imaging of the abdomen revealed a low-density cystic mass. A cystectomy was performed. Hydatid sand containing a protoscolex of *Echinococcus granulosus* was seen on microscopical examination. Specific antiparasitic treatment was given and after two months the patient is asymptomatic.

Key words: *Echinococcus granulosus*, liver mass, hepatic cyst.

A 32-year-old woman without any history of digestive or hepatic disease. The patient had been well until few hours of her admission. She was admitted to hospital complaining of right upper quadrant and epigastrium abdominal pain, and nausea. On routine physical examination an abdominal mass was discovered on the right upper quadrant, and there was tenderness in the upper abdomen. Hematologic and blood chemical tests were performed: Her haematocrit was 36.4%, with a mean corpuscular volume of 86.9 μm^3 and a platelet count of 162/mm³. White-cell count of 7.0 per mm³, differential count, neutrophils 79.8%, lymphocytes 7.1%, monocytes 6.4%, 6.7%. Liver tests were normal. Magnetic resonance imaging was performed (MRI) of the abdomen with contrast medium re-

vealed a low-density cystic mass measuring 11 by 11 by 10 cm in the right lobe, with a thick, irregular wall (*Figure 1, panel A*). Twelve hours later, a laparoscopy was indicated. A cystectomy was performed, with the use of specific precautions to prevent local spread of disease abdominal Aspiration of the contents of the cyst yielded clear, colorless fluid. Hydatid sand containing a protoscolex of *Echinococcus granulosus* was seen on microscopical examination (unstained wet preparation, x40; *Figure 1, panel B*). Serological test to *Echinococcus granulosus* antibodies IgG were positive. Specific antiparasitic treatment was given and after two months the patient is asymptomatic.

Infection with *Echinococcus granulosus* is the most common form of echinococcal infection in humans.¹ This parasite's life cycle typically involves dogs (the definitive hosts) and sheep (the intermediate hosts); however, strains that are transmitted from dogs to cattle, horses, camels, and pigs have been identified.¹ In the definitive canine host, the adult worm resides in the intestine, and its eggs, or oncospheres, are released into the feces. When an oncosphere is ingested by a suitable intermediate host, it penetrates the intestinal wall and migrates by way of the portal circulation to the liver, where most oncospheres are deposited. However, some of the organisms are not filtered by the liver and are trapped in the pulmonary circulation. Once an oncosphere is deposited in tissue, the metacestode, or hydatid cyst, develops. The hydatid cyst slowly expands and is composed of a capsule, which is made up of a germinal layer and a host inflammatory response (fibrosis and chronic inflammation), and internal cystic fluid, which is filled with daughter cysts. The life cycle is complete when the intermediate host dies and the cysts are ingested by the definitive host.

Echinococcal infection in humans occurs incidentally, when a person comes into close proximity to a reservoir host, and is not a necessary step in the life cycle of the parasite. Since the parasite has evolved mechanisms to avoid host immunity, the infection is often asymptomatic until a mechanical complication occurs, such as rupture (into the biliary tree, bronchial tree, or peritoneum), compression of vital structures, hemorrhage, or tissue failure (particularly with bone involvement).² In human hosts, the cysts typically expand at a rate of approximately 1 cm per year in the liver and at a slightly faster rate in the lung.

¹ Departments of Biomedical Research, Gastroenterology and Liver Unit.

² Surgery.

³ Radiology.

⁴ Pathology

Medica Sur Clinic & Foundation, Mexico City, Mexico

Address for correspondence:

Nahum Méndez-Sánchez, MD, PhD

Departments of Biomedical Research and Gastroenterology, Medica Sur Clinic & Foundation, Puente de Piedra 150 Col. Toriello Guerra Mexico City, Mexico. Phone: (+525) 606 6222 Ext 4215 Fax: (+525) 666 4831 and 606 1651; E-mail: nmendez@medicasur.org.mx

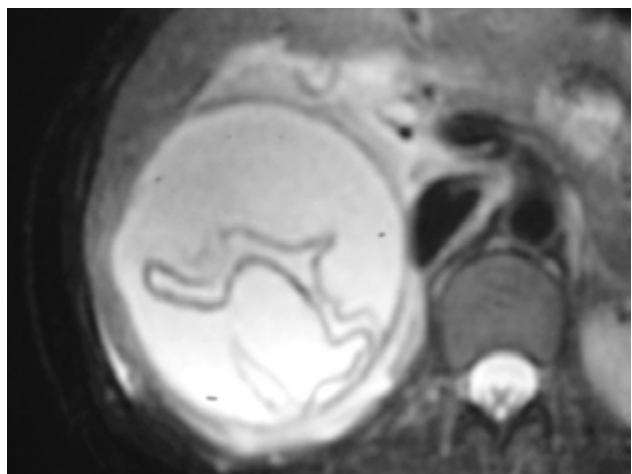
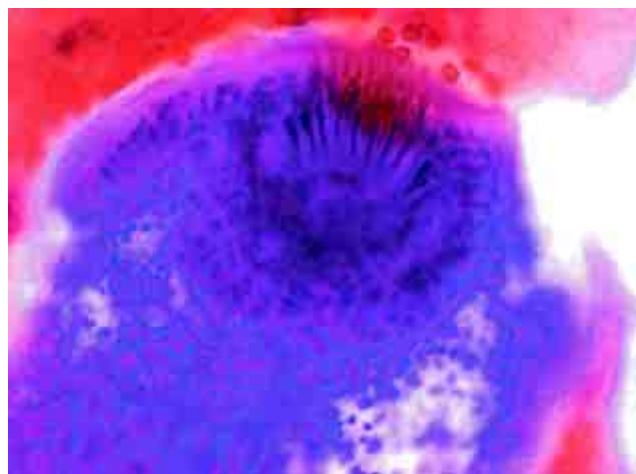


Figure 1. Panel A. MRI revealed a low-density cystic mass measuring 11 by 11 by 10 cm in the right lobe, with a thick, irregular wall.



Panel B. Hydatid sand containing protoscolex of *Echinococcus granulosus* was seen on microscopical examination (unstained wet preparation, x40;

Most primary infections in humans involve a single cyst; multiple cysts are present in 20 to 40 percent of cases. Approximately 65 percent of cysts develop in the liver and 25 percent in the lungs; the remainder may occur anywhere else in the body.³

References

1. Goldman IS, Lloyd L, Brandborg LL. Parasitic Diseases of the liver. In: Zakim D, Boyer TD, eds. *Hepatology: A Text Book of Liver*. Volume 2, 3rd ed. Philadelphia, PA: W.B. Saunders Company, 1996: 1206-1231.
2. Shantz PM. Echinococcosis. In: Geurrant RL, Walker DH, Weller PF, eds. *Tropical infectious diseases: principles, pathogens, & practice*. Vol. 2. Philadelphia: Churchill Livingstone, 1999: 1005-25.
3. Pawlowski ZS, Eckert J, Vuitton DA, et al. Echinococcosis in humans: clinical aspects, diagnosis and treatment. In: Eckert J, Gemmel MA, Meslin F-X, Pawlowski ZS, eds. *WHO/OIE manual on Echinococcosis in humans and animals: a public health problem of global concern*. Paris: World Organization for Animal Health. World Health Organization, 2001: 20-71.