

## ANNALS OF HEPATOLOGY

Volume **3**

Number **4**

October-December **2004**

*Artículo:*

Telangiectatic adenoma: a variant of  
hepatocellular adenoma

Copyright © 2004:  
Mexican Association of Hepatology

**Otras secciones de  
este sitio:**

-  [Índice de este número](#)
-  [Más revistas](#)
-  [Búsqueda](#)

***Others sections in  
this web site:***

-  [Contents of this number](#)
-  [More journals](#)
-  [Search](#)

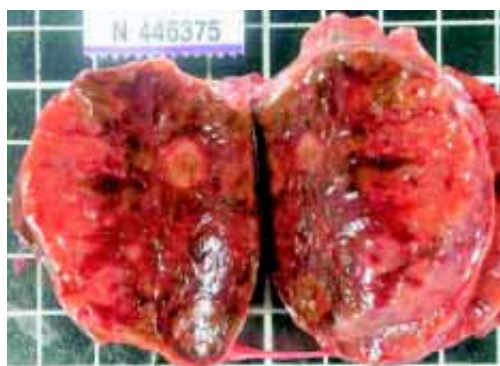


**medigraphic.com**

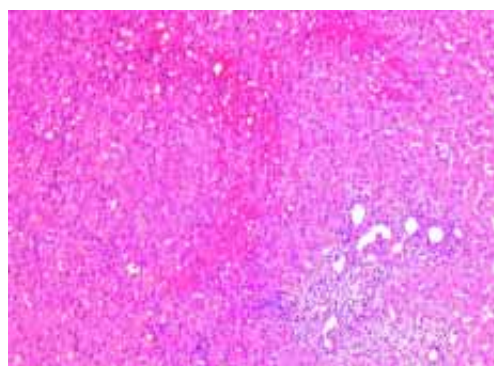
## Images in Hepatology

# Telangiectatic adenoma: a variant of hepatocellular adenoma

Pierre Bedossa<sup>1</sup>



**Figure 1.** Macroscopic view of a telangiectatic adenoma. The outer surface shows several dilated vessels running under the capsula. At cut section, the lesion is well-limited, unencapsulated and displays areas of congestion with haemorrhage.



**Figure 2.** Microscopic findings of a case of telangiectatic adenoma. Few vessels and remnants of portal tracts with some inflammatory cells are observed within hepatic tissue. Note the presence of congestive areas with some degree of sinusoidal dilatation visible at low magnification.

Figure: benign, well-limited hepatocellular tumor with major haemorrhagic foci and telangiectasia on histology.

Beside Focal Nodular Hyperplasia and hepatocellular adenomas, the most frequent benign hepatocellular lesion in the liver, a variant, initially called «telangiectatic focal nodular hyperplasia» now claimed as “telangiectatic adenoma” has been described recently. Initially observed in the context of vascular malformations of various organs and neoplasia of the brain, it appears that this lesion is not so rare.<sup>1</sup> In a large surgical series of benign liver lesions, the previously so-called “telangiectatic focal nodular hyperplasia” accounted for approximately 15% of cases of focal nodular hyperplasia.<sup>2</sup> Based on molecular evidences including clonal analysis and gene expression studies, it now clearly appears that this type of tumour belong to the group of hepatocellular adenomas. This reclassification might have some clinical relevance since such telangiectatic lesion should be aggressively managed, in the same way that hepatocellular adenoma.

## References

1. Wanless IR, Albrecht S, Bilbao J, et al. Multiple focal nodular hyperplasia of the liver associated with vascular malformations of various organs and neoplasia of the brain: a new syndrome. *Mod Pathol* 1989; 2: 456-462.
2. Nguyen BN, Fléjou JF, Terris B, Belghiti J, Degott C. Focal nodular hyperplasia of the liver. A comprehensive pathologic study of 305 lesions and recognition of new histologic forms. *Am J Surg Pathol* 1999; 23: 1441-1454.

<sup>1</sup> Hôpital Beaujon, Service d' Anatomie Pathologique.

Address for correspondence:

Prof. Pierre Bedossa

Hôpital Beaujon, Service d'Anatomie Pathologique

CNRS UMR 8149

100 Boulevard du Général Leclerc

92110 Clichy Cedex – France

E-mail : pbedossa@teaser.fr