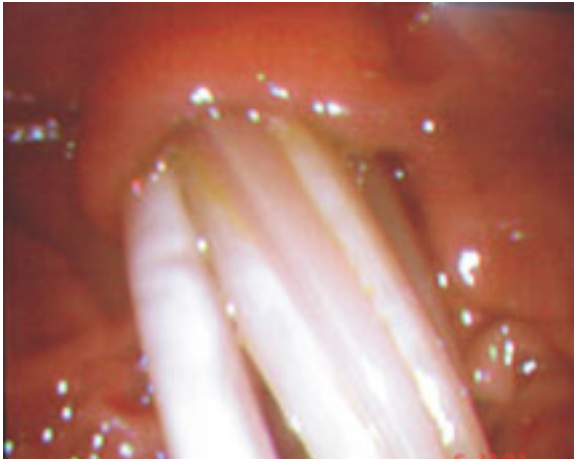
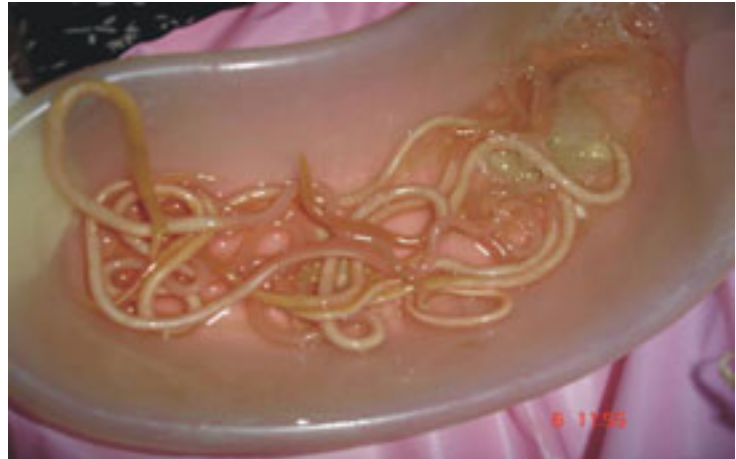



Images in Hepatology

Common bile duct: A retreat for ascariasis!N. Rajesh;¹ A. Murali;¹ S. Joye Varghese;¹ Cherian Jijo V;¹ V. Jayanthi¹**Figure 1.****Figure 2.**

A 29 - year - old lady, presented with upper abdominal pain lasting for 5 days, with radiation to the back. One week prior to the presentation she vomited 3 round worms, with a similar history in childhood. There was no history of fever, jaundice, intestinal colic or bowel distension. Physical examination was unremarkable, except for tenderness in the epigastrium.

Hemogram and liver function tests were normal. Serum amylase was 1,100 U/L. A plain radiograph of the abdomen was normal. Sonogram of the abdomen revealed a normal pancreas and several linear echogenic strips within the distal common bile duct. The duct was 10 mm.

An upper endoscopy revealed multiple round worms lying within the lumen of the second part of the duodenum with their proximal end within the ampulla (*Figure 1*). Fifteen worms were removed using snare after multiple passes (*Figure 2*). The patient was subsequently treated with albendazole. She passed 10 worms in the stool the following two days. Repeat sonogram of the biliary system was normal and patient became asymptomatic.

¹ Department of Medical Gastroenterology, Stanley Medical College Hospital, Chennai, India.

Address for correspondence:

Dr. Joye Varghese S. MD

Department of Medical Gastroenterology,

Stanley Medical College Hospital, Chennai, India – 600 001

E-mail I.D – joyvargese@gmail.com

Manuscript received: 18 May, 2006

and accepted: 20 May, 2006.