

Images in Hepatology

Necrotizing hepatitis and intrahepatic cholestasis associated to *Cryptococcus* sp. and *Pneumocystis carinii*

Nahum Méndez-Sánchez;¹ Raul Pichardo-Bahena;¹ Hilda Villegas Castrejón;² Renato D. Berron-Pérez;¹ Victor M. Hernández-Bautista;¹ Luis Soto-Ramírez;¹ Luis P. Alessio¹

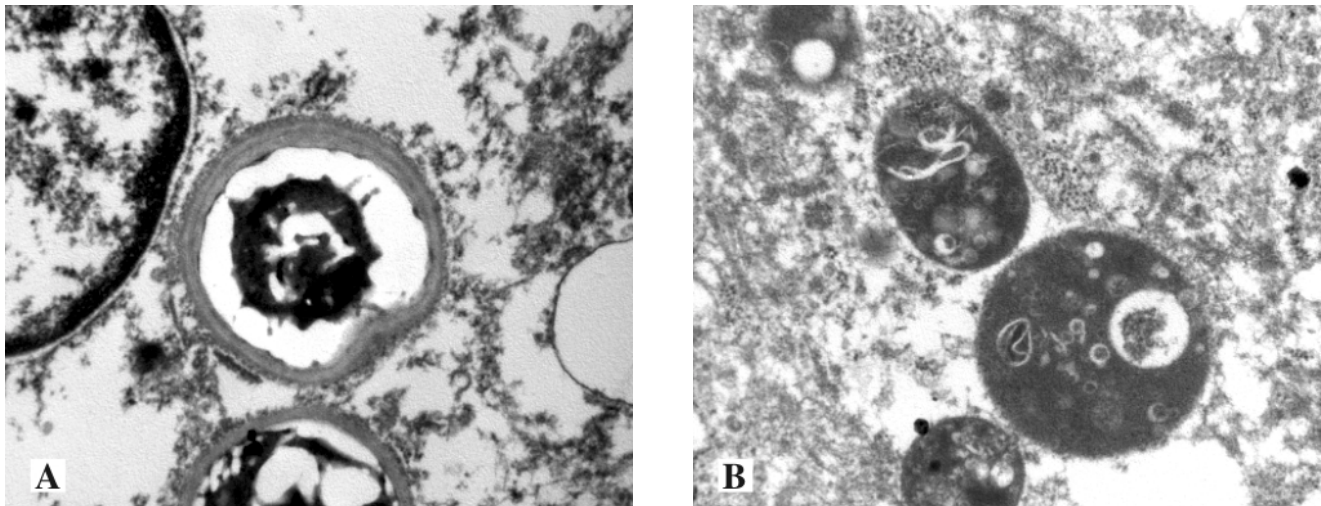


Figure 1. A: Infectious agent with oval form and double coat with medium clear zone. In the interior there are nucleoplasm with granular material. In the external surface there are filament-like structures. This infectious agent is a *Cryptococcus* sp. B: Cystic formations with membranous material in the interior are typical elements of *Pneumocystis carinii*.

21-year-old boy was admitted to this hospital because of fever, jaundice, nausea and vomiting. The patient had systemic lupus erythematosus since 2001 under medical treatment with mycophenolate mofetil 2 g/d and prednisone 25 mg/d. He has been well until one week before admission, when fatigue developed. On physical examination, he had jaundice and hepatomegaly. The peripheral white-cell count was 2,100 cells per cubic millimeter (80 percent neutrophils), and the hematocrit was 40 percent. Platelets 198 (per mm³), Prothrombin time 11.4 (sec), total bilirubin 13.2 mg/dL and conjugated 8.6 mg/dL, Alkaline phosphatase 1,388 (U/liter), Aspartate aminotransferase 469 (U/liter), Alanine aminotransferase 194 (U/liter), Hepatitis B virus (HBV) and hepatitis C virus (HCV) infections were overruled by the detection of HBV antigens, anti-HBV antibodies and HCV-RNA which were negative. Also human immunodeficiency virus (HIV) types 1 and 2 were negative. Abdominal ultrasound was reported normal. Percutaneous liver biopsy was performed and analyzed by an expert

¹ Medica Sur Clinic & Foundation, Mexico City, Mexico.

² Departamento de Morfología Celular y Molecular, Centro Nacional de Rehabilitación, Secretaría de Salud. Mexico City, Mexico.

Address for correspondence:

Nahum Méndez-Sánchez, M.D., Ph.D. Departments of Biomedical Research, Gastroenterology & Liver Research Unit, Medica Sur Clinic & Foundation, Puente de Piedra 150, Col. Toriello Guerra, Mexico City, Mexico. Phone: (+525) 55606-6222, ext. 4215. Fax: (+525) 55666-4031 and 55606-1651; E-mail: nmendez@medicasur.org.mx

pathologist who reported necrotizing hepatitis and intrahepatic cholestasis associated to *Cryptococcus sp* and *Pneumocystis carinii*. In the tissue was found two types of microorganisms with different size and histochemical affinity. In the electron microscopy was found two microorganisms. The first one consisted with cysts with membranous material in the interior, characteristic of *Pneumocystis carinii*. On the other hand, we saw oval structures with double membrane with central clear band. In the interior we observed another nuclear-like structures and nucleoplasm while in the external surface filamentous-like structures. These structures corresponded to *Cryptococcus sp* (Figure 1).