



Case Report

Giant hydatid liver cyst. Management of residual cavity

Nikolaos S. Salemis¹

Abstract

The management of the residual cavity during surgical intervention for giant hydatid liver cysts is often a challenging problem. Herein, is described the case of a 55-year-old female patient who was diagnosed with a giant hydatid cyst occupying almost the entire left lobe of the liver. After partial cystectomy, the residual cavity was managed by combination of suture obliteration with omentoplasty. The patient had an uneventful post-operative course and was discharged eight days later. The clinical presentation, diagnostic work-up and surgical management of the patient are discussed, along with a review of the literature.

Key words: Hydatid liver cyst, echinococcosis, giant, residual cavity.

Introduction

Hydatid disease or echinococcosis is a parasitic infection caused by the larval form of tapeworm of genus *Echinococcus*. The disease is endemic in the Mediterranean region, the Middle East and South America.¹ In the vast majority of the cases (95%) the disease is secondary to *Echinococcus granulosus* and is confined to a single organ.² Humans are accidentally infected as intermediate hosts after the ingestion of the parasitic eggs from infected animals. Hydatidosis occurs more frequently in the liver (50-70% of the cases), followed by the lungs (20-

30%).³ Surgery remains the gold standard approach, but in some cases it is challenging as patients present with manifestations of giant liver cysts.

Case presentation

A 55-year old female was admitted with a 1-month history of intermittent right upper quadrant and epigastric pain, fullness and general fatigue. The pain, which was radiating to the back, had become progressively worse over the last week and was associated with nausea and a few episodes of vomiting. Her past medical history was unremarkable. On clinical examination, a large approximately 15 cm in diameter, firm non tender mass was palpated in the epigastrium. The hemogram, the rest laboratory investigation and tumor markers were all within normal range. Plain abdominal radiograph was unremarkable, while ultrasonography and contrast enhanced computed tomography (CT) scans revealed a huge well defined cystic mass occupying almost the entire left liver lobe measuring 16 cm in diameter containing inhomogeneous fluid content and several endocysts (*Figure 1*). At surgery the abdomen was exposed through an extended right subcostal incision. After a huge hydatid cyst occupying the whole left liver lobe was found, a thorough investigation of all abdominal viscera was performed for possible sites of dissemination. The operative field was then packed with swabs soaked with hypertonic sodium chloride solution. The cyst was punctured at its dome and the fluid content was aspirated with a 14 gauge needle connected to high pressure suction. The cavity was refilled with hypertonic (20%) sodium chloride solution for 10 minutes and then opened through a wide incision at its protruding dome. All the contents of the cyst including the laminated membrane were then evacuated and a thorough inspection revealed the presence of a biliary communication (*Figure 2*) which was sutured with fine non absorbable sutures. Intraoperative cholangiography performed due to the presence of the biliary communication revealed no pathological findings. The cavity of the cyst was then scrubbed with swabs soaked with povidone-iodine. Following partial cystectomy, the residual cavity was partially obliterated by suturing together the outer cyst's edges with a series of mattress sutures after manual compression of the liver parenchyma was main-

¹2nd Department of Surgery, Army General Hospital, Athens, Greece.

Address for correspondence:
Nikolaos S. Salemis, MD, PhD
Consultant Surgical Oncologist
Address: 19 Taxiarchon Str,
19014 Kapandriti
Athens - Greece
Tel: +30 22950 23559
Mob: +30 6932528444
Fax: +30 210 6140808
Email: nikos_salemis@hotmail.com

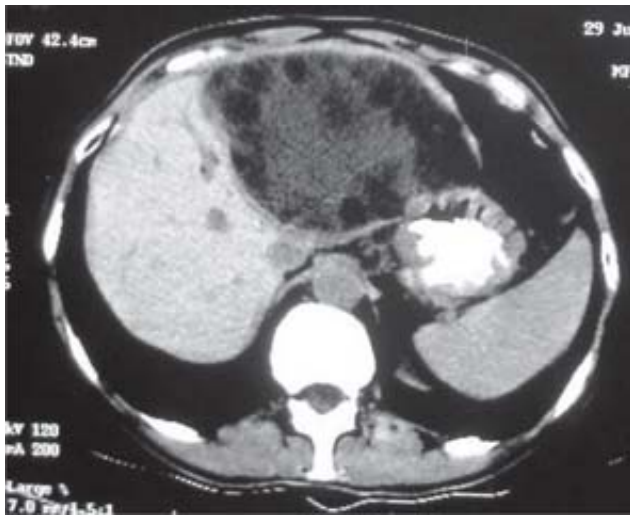


Figure 1. Contrast enhanced computed tomography scan showing a giant hydatid cyst occupying almost the entire left liver lobe. It contains inhomogeneous fluid and several daughter cysts.

tained toward the cavity's midline. Using these sutures, a significant obliteration of the initial giant cavity was achieved and the final residual cavity was filled with a pedicled omental flap, whereas a drainage tube was left in place. The drain was removed on the sixth postoperative day and the patient was discharged two days later after an uneventful clinical course. She was prescribed albendazole (10 mg/kg daily) for 4 weeks. Follow-up investigations revealed no signs of recurrence, three years after surgery.

Discussion

The main management strategies against hydatid liver disease include medical therapy, percutaneous therapy and surgical intervention. Medical therapy alone using benzimidazole compounds (mebendazole and albendazole) has a less than 30% success rate.¹ In a systematic review by Dziri *et al*⁴ it was concluded that chemotherapy alone is not effective and needs to be combined either with percutaneous therapy or surgical intervention.

Regarding percutaneous therapy, Smego *et al*⁵ using meta-analysis methodology compared the clinical outcomes of 769 patients who were treated with percutaneous aspiration-injection-reaspiration (PAIR) plus albendazole or mebendazole, with 952 era-matched historical control subjects who underwent surgery. They concluded that the group of patients with the PAIR intervention plus chemotherapy had lower mortality, morbidity and recurrence rates, shorter hospital stay and greater clinical and parasitologic efficacy.

Surgery remains the gold standard treatment for hydatid liver disease.^{6,7} The aim of surgical intervention is to inactivate the parasite, to evacuate the cyst along with resection of the germinal layer, to prevent peritoneal

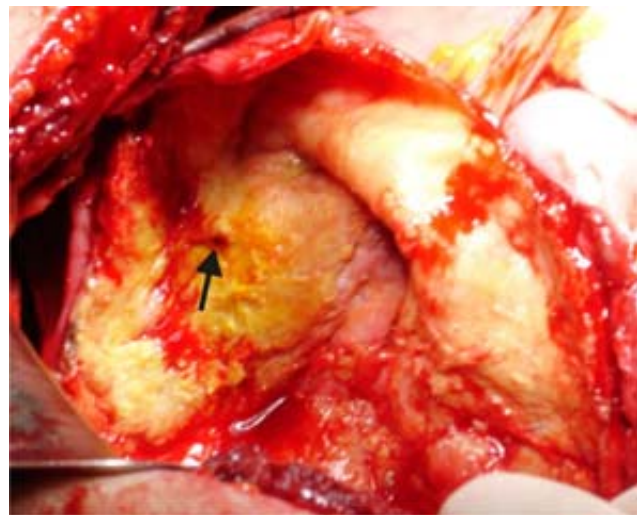


Figure 2. Intraoperative photo showing the giant hydatid cyst before management of the residual cavity. Note the site of biliary communication (arrow).

spillage of scolices and to obliterate the residual cavity.^{2,5} Surgical treatment can be divided into radical or conservative approaches.¹ A radical approach may include total cystectomy, or liver resection.^{6,8} Laparoscopic approach has also been reported with good results in selected patients.⁹⁻¹¹ However, there are no randomized trials comparing the laparoscopic with the open approach.⁶

The management of the residual cavity is a challenging problem especially in patients who present with giant hydatid cysts, as in this case. Furthermore, cyst size has been identified as a significant predictor of morbidity and mortality,¹² and large residual cavities are associated with an increased infection risk.¹³ Various techniques have been described for the management of residual cavities, such as marsupialization, external drainage, capitonage, introflexion and omentopexy.⁷ In our case, omentoplasty alone was not sufficient to fill the giant residual cavity. Thus, we performed a modified capitonage by suturing together the outer edges of the cystic wall. The approximation was relatively easy because the liver had been adequately mobilized and additionally there was no calcification or rigidity of the cystic wall. A similar technique has been reported earlier by Losanoff *et al*¹³ for the obliteration of giant residual cavities in 8 patients after simple cystectomy. Prior to suturing the fibrous capsule, they additionally used omentoplasty or gelatine sponges to fill the dead space. They reported no septic complications, postoperative bile leak or other long term adverse effects. Ezer *et al*,¹⁴ used a similar technique called 'sandwich method' for the obliteration of a large dead space following the removal of a giant cyst.

Percutaneous drainage has been reported in the management of giant hydatid liver cysts.^{15,16} This method was not considered because the cyst was multivesicular containing several daughter cysts, whereas the cyst con-

tent was likely undrainable. Men *et al*,¹⁵ performed percutaneous treatment in 13 giant liver cysts which were all univesicular with pure fluid content. They concluded that the approach was effective as it resulted to the elimination of the parasite and the mass effect and alleviation of symptoms. However, the procedure was associated with a long catheterization time.

References

1. Goldblatt MI, Pit HA. *Hepatic echinococcosis*. In: Cameron JL, ed. *Current Surgical Therapy*, 8th ed. Philadelphia: Elsevier Mosby, 2004; 306-311
2. Hofstetter C, Segovia E, Vara-Thorbeck R. Treatment of uncomplicated hydatid cyst of the liver by closed marsupialization and fibrin glue obliteration. *World J Surg* 2004; 28: 173-8.
3. Khuroo MS, Wani NA, Javid G, Khan BA, Yattoo GN, Shah AH, Jeelani SG. Percutaneous drainage compared with surgery for hepatic hydatid cysts. *N Engl J Med* 1997; 337: 881-7.
4. Dziri C, Haeuet K, Fingerhut A. Treatment of hydatid cyst of the liver: where is the evidence? *World J Surg* 2004; 28: 731-6.
5. Smego RA Jr, Bhatti S, Khaliq AA, Beg MA. Percutaneous aspiration-injection-reaspiration drainage plus albendazole or mebendazole for hepatic cystic echinococcosis: a meta-analysis. *Clin Infect Dis* 2003; 37: 1073-83.
6. Yagci G, Ustunsoz B, Kaymakcioglu N, Bozlar U, Gorgulu S, Simsek A, Akdeniz A, Cetiner S, Tufan T. Results of surgical, laparoscopic, and percutaneous treatment for hydatid disease of the liver: 10 years experience with 355 patients. *World J Surg* 2005; 29: 1670-9.
7. Kayaalp C, Sengul N, Akoglu M. Importance of cyst content in hydatid liver surgery. *Arch Surg* 2002; 137: 159-63.
8. Balik AA, Başoğlu M, Celebi F, Oren D, Polat KY, Atamanalp SS, Akçay MN. Surgical treatment of hydatid disease of the liver: review of 304 cases. *Arch Surg* 1999; 134: 166-9.
9. Chen W, Xusheng L. Laparoscopic surgical techniques in patients with hepatic hydatid cyst. *Am J Surg* 2007; 194: 243-7.
10. Baskaran V, Patnaik PK. Feasibility and safety of laparoscopic management of hydatid disease of the liver. *JSLS* 2004; 8: 359-63.
11. Ertem M, Karahasanoglu T, Yavuz N, Erguney S. Laparoscopically treated liver hydatid cysts. *Arch Surg* 2002; 137: 1170-3.
12. Daradkeh S, El-Muhtaseb H, Farah G, Sroujeh AS, Abu-Khalaf M. Predictors of morbidity and mortality in the surgical management of hydatid cyst of the liver. *Langenbecks Arch Surg* 2007; 392: 35-9.
13. Losanoff JE, Richman BW, Jones JW. Organ-sparing surgical treatment of giant hepatic hydatid cysts. *Am J Surg* 2004; 187: 288-90.
14. Ezer A, Nursal TZ, Noyan T, Moray G. Giant hepatic hydatid cyst: a case report. *World J Gastroenterol* 2007; 13: 2388-9.
15. Men S, Yücesoy C, Edgüer TR, Hekimoğlu B. Percutaneous treatment of giant abdominal hydatid cysts: long-term results. *Surg Endosc* 2006; 20: 1600-6.
16. Battyány I, Herbert Z, Rostás T, Vincze A, Fülöp A, Harmat Z, Gasztonyi B. Successful percutaneous drainage of a giant hydatid cyst in the liver. *World J Gastroenterol* 2006; 12: 812-4.