

Annals
of
Hepatology

Concise Review

Cavoportal hemitransposition for the simultaneous thrombosis of the caval and portal systems - A review of the literature

Dietmar H. Borchert¹

Abstract

Portal venous thrombosis was originally considered to be a contraindication for liver transplantation. Currently, several methods exist to re-establish blood flow to the hepatic portal system. Cavoportal hemitransposition is a surgical procedure that can be used in liver transplantation when the portal venous system is thrombosed and portal flow cannot be re-established from the mesenteric venous system. In cavoportal hemitransposition the blood flow from the inferior vena cava of the recipient is directed to the portal vein of the donor liver to compensate for the lost portal venous supply. This can either be done by end-to-end or end-to-side anastomosis. Seventy-one cases of cavoportal hemitransposition have been reported worldwide. All patients reported had been in a critical and life-threatening condition, presenting with either end-stage-liver disease or acute hepatic failure combined with severe vascular pathology. Of the cases reported, 32 patients died for reasons non-related to the surgical procedure. Seven of the 71 patients had Budd-Chiari syndrome complicated by thrombosis of the portal-venous system. This means thrombosis in two different venous systems at the same time, the mesenteric and main venous system. To date this «two-system» venous thrombosis of both the caval and portal system has only been re-

viewed together with the possible medical, radiological and non-transplant treatment options. This article evaluates the available literature and reviews the evolution of the surgical procedure of cavoportal hemitransposition emphasising its role in combined thrombosis of the hepatic veins and portal venous systems.

Key words: CPHT cavoportal hemitransposition, PCHT portocaval hemitransposition, CPT cavoportal transposition, BCS Budd-Chiari Syndrome, PVT portal vein thrombosis, liver disease, liver failure; transplantation.

Introduction

The Budd-Chiari Syndrome (BCS) is caused by hepatic venous outflow obstruction. This obstruction can be at different levels and present as a complete or incomplete obstruction. The venous obstruction can be continuous from or localized at the levels of the small hepatic veins, the large hepatic veins, the hepatic inferior vena cava (IVC), or the suprahepatic IVC up to the right atrium (*Figure 1*, on red). In 1990, Ludwig et al. classified the different types of Budd-Chiari-Syndrome and this classification is seen as the standard today.¹ It excludes veno-occlusive disease (also known as sinusoidal obstruction) and hepatic outflow obstruction due to impaired function of the heart.²

Large series of patients undergoing treatment for BCS have been reported, especially from Asian countries.^{3,4} Smaller studies on the epidemiology and treatment of BCS exist from western countries.⁵⁻⁷ Menon et al. had recently produced an extensive review of the presentation, pathogenesis, treatment and prognosis of BCS.⁸ The chronic form of BCS dominates over the acute presentation (fulminant form). Thus treatment strategies vary according to the type of presentation of BCS and when associated to liver failure it becomes a well-recognized indication for liver transplantation.⁹ If left untreated, the stasis in the outflow tract of the liver may lead to increased pressure in the hepatic sinusoids and portal hypertension. This in turn may result in subsequent portal vein thrombosis.^{10,11}

¹ St. Bartholomew's Hospital, Directorate of Surgery & Anaesthesia, London, UK.

Address for correspondence:
Dietmar H. Borchert, MD
St. Bartholomew's Hospital
Directorate of Surgery & Anaesthesia
West Smithfield
London, EC1A 7BE
Tel.: 0044 (0)20 7601 8394
Fax.: 0044 (0)20 7601 7844
dietmar.borchert@bartsandthelondon.nhs.uk
dietmar.borchert@doctors.org.uk

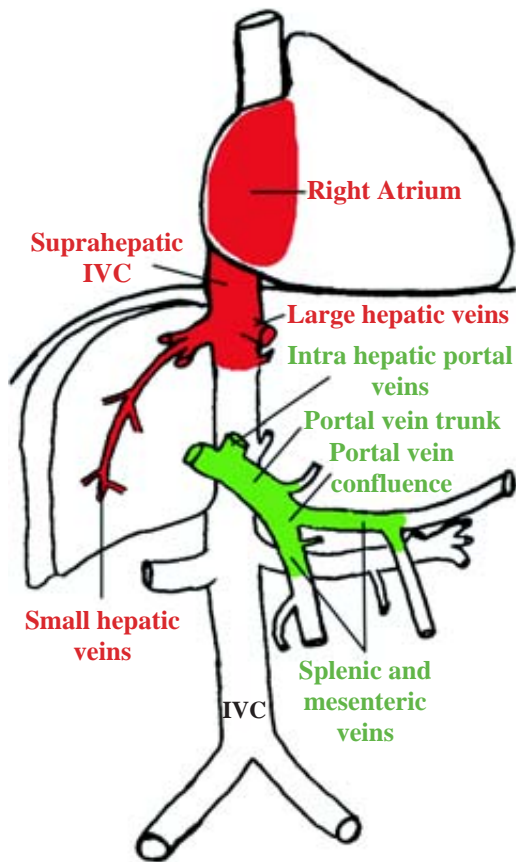


Figure 1. Combined thrombosis of the main venous tree (on red) (according to Ludwig et al. classification on BCS) and portal - mesenteric system (on green), indicating different levels of thrombosis. IVC, inferior vena cava. Figure designed and produced by Dr. D.H. Borchert © 2005.

Thrombosis of the portal venous system

Portal vein thrombosis (PVT) is a partial or complete obstruction of the trunk of the portal vein (Figure 1, on green). But similar to BCS it can occur at different levels and extend distally (in direction of flow) into the left and right hepatic portal veins and further up into the segmental intrahepatic branches or it may extend proximally into the splenic vein, superior and inferior mesenteric vein. Whenever the thrombosis is not confined to the portal vein trunk the term «portal venous system thrombosis» should be used.¹²

PVT has been classified surgically as «complete segmental», «complete and complex» and «complete and extensive» thrombosis including portal vein tributaries by Stieber et al.¹³ Another classification described PVT as a spectrum of «partial thrombosis» (< 50% of vessel lumen) to «complete thrombosis including the superior mesenteric vein».¹⁴ A more simplified system described any PVT with less than 90% occlusion as partial PVT and occlusion above 90% as complete PVT regardless of further involvement of the portal vein tributaries.¹⁵

The extent of PVT can only be reliably evaluated by thorough dissection *in situ* or in autopsy studies.¹⁶⁻¹⁸ Data from autopsy reports in general hospital settings state an overall incidence in the range of 0.05-0.5% for PVT.¹⁹ In patients with end-stage liver disease, the incidence of PVT in those undergoing liver transplantation, is much higher: between 2% and 19%^{15,20} A study on 379 transplant patients found 39 patients with PVT. The thrombosis was extending to or beyond the confluents in two thirds of patients and a third had cavernous transformation of the portal vein. This study also found a high incidence of spontaneous splenorenal shunts (31%) among patients with PVT. Moreover patients with PVT have mesenteric oedema and mesenteric varices in up to 50% of the cases.¹⁶

Two - system thrombosis

Combined thrombosis of the inferior vena cava and portal-venous system is a rare and considered a severe condition. The combined thrombosis (BCS-PVT) can involve both venous systems to a varying extent and can be either acute or chronic in nature (Figure 1). Data on the prevalence of this two-system-thrombosis are sparse; however, Nonami et al. reported nine patients with Budd-Chiari syndrome in a liver transplant population of 885 patients. Of these nine, two patients had complete thrombosis of the portal-venous-system.²¹ In a recent North-Indian study by Saxena et al., four patients out of 57 (with BCS) had complete thrombosis of both the inferior vena cava (IVC) and portal-venous system.²² Mahmoud et al. found thirteen patients with portal-venous thrombosis out of 51 with BCS as the main diagnosis.²³ A recent multicenter study found 33 cases of combined BCS-PVT among 282 patients with the primary diagnosis of BCS. In this study 70% of patients with combined BCS-PVT were female. Patients with combined BCS-PVT tended to have a worse prognosis compared to patients with BCS only, but this was statistically not significant.²⁴

In a histopathological study on BCS, involvement of the portal system of the liver was not a prognostic factor.²⁵ However, obstruction of the intrahepatic portal system seems to be common in BCS and was found in all of 17 livers in one study and in 12 of 15 livers in another study from patients with BCS undergoing liver transplantation.^{10,11} Thrombosis of the portal vein system was also found to be associated with a more acute onset and a shorter pre-transplant course.

The aetiological factors for BCS and PVT are similar with two exceptions. Both are results of acute or chronic thrombotic processes due to mechanic obstruction, inflammation or coagulation disorders. However, in the paediatric population infections, (especially umbilical vein sepsis and appendicitis), agenesis or atretic portal vein and previous portoenterostomy (Kasai procedure) for biliary atresia are the cause for PVT. In older pa-

tients pancreatic cancer comprises the second aetiological subgroup, which is different regarding underlying pathology compared to other causes for BCS. Murad et al. also described predominance in local factors like cirrhosis, abdominal tumours and inflammation as well as previous abdominal surgery for PVT.²⁴ Increasingly acquired or inherited coagulation disorders are found in association with other factors in BCS and PVT. Often the aetiological factors of BCS-PVT seem to be multifactorial and the severity of the disease increases with multifactorial aetiology.

Method of review

A literature search was used to identify all cases of cavoportal hemitransposition (CPHT) using the keywords cavoportal hemitransposition, portocaval hemitransposition, portal vein thrombosis, Budd Chiari Syndrome and liver transplantation. Standard publications on liver transplantation and medical management of patients with liver disease were reviewed for indications and treatment options. More recent interventional radiological methods in treating acute thrombotic disease were retrieved from standard publication databases. A total of 23 out of 25 publications with reports on cavoportal hemitransposition only have been used to assess experience with this procedure.^{15,17,18,26-47} In one case report the surgical procedure was started in attempt to perform a cavoportal hemitransposition, but was not finished as such.³¹ In another review the patient had been reported previously by another team.¹⁵ These reports were excluded from the analysis. Furthermore we excluded reno-portal anastomosis in contrast to a recent review.⁴⁸ We extracted demographic patient data, indication for liver transplantation, previous surgical procedures, signs of portal hypertension, postoperative complications, morbidity and mortality.

Surgical techniques

Indication for liver transplantation depends on several factors. The most important factor being irreversible and progressive liver failure.⁴⁹⁻⁵¹ The patients described in this article presented with either acute-on-chronic liver failure complicated by vascular diseases or with acute liver failure due to vascular pathology. If the hepatic veins were thrombosed, as in BCS, and liver function was irreversibly damaged, liver transplantation was indicated. In this situation, Sennings procedure (a direct hepatoatrial anastomosis) has also been used.⁵² If only the portal vein is thrombosed, there are several surgical techniques, which can be used to restore the blood flow to the *porta hepatis*. First, a simple portal thrombectomy can be performed if possible. If the thrombus is organized and the portal vein cannot be re-canalized alternative methods are used. Several shunt and bridging techniques exist

to prevent or treat developing portal hypertension.⁵³⁻⁵⁵ If liver transplantation is indicated, the blood flow to the portal vein can be restored by one of several methods: anastomosis of the donor portal vein to the recipient superior mesenteric vein; anastomosis of the donor portal vein to the recipient splenic vein; or a venous jump graft to any suitable mesenteric tributary vein. When the portal venous system is only partially thrombosed, the blood flow can be increased by arterializing the portal vein.⁵⁶

If the portal vein, splenic vein and mesenteric veins are all occluded, there are three feasible techniques for restoring blood flow to the donor portal vein in liver transplantation. In this situation, liver transplantation can be combined with small bowel transplantation, cavoportal hemitransposition (*Figure 2*), or renoportal anastomosis.⁵⁷ Suprahepatic caval and arterial anastomoses are carried out in the usual manner. Delayed abdominal closure has to be anticipated in view of mesenteric oedema.

Cavoportal hemitransposition

History – Evolution of a technique

The ancestors of cavoportal hemitransposition, the so-called «Eck-Fistula», and several other shunt techniques, were developed since 1877 and used to treat portal hypertension, ascites and oesophageal varices due to chronic liver disease.^{58,59} The basic principle of the «Eck-Fistula» is ligation of the portal vein at the hepatic hilum and anastomosis of the distal portal vein to the inferior vena cava (*Fig. 2/1* dog liver). Pawlow et al. used this procedure and published their classical paper of «meat intoxication» in 1893.⁶⁰ The «Eck-Fistula» was used to study the physiology of liver regeneration and to search for the «hepatotropic factor». This was to clarify the question as to whether a hepatotropic factor exists in the portal venous blood. C.G. Child developed the technique of «portacaval transposition» in dogs in 1953 (*Fig. 2/2* dog liver).⁶¹ Later in 1964 Starzl et al., followed in 1966 by Riddell et al., used the «portacaval transposition» or «portal diversion» in non-transplant patients with glycogen storage disease and familial hyperlipidaemia (*Fig. 2/3*, these patients are not included in this review).⁶² This non-transplant procedure was preceded by several experiments in animals.^{61,63,64} In «portacaval transposition» the distal portal vein is anastomosed to the proximal part of the inferior vena cava and the distal inferior vena cava is anastomosed to the proximal part of the portal vein. Thus, the two systems are changed over (*Fig. 2/3*). The anastomosis are performed in an area between the confluents of the hepatic vein and the renal veins. The complete transposition used in three patients with glycogen storage disease in the early 1970's pioneered the concept of using caval blood flow to compensate for the lost portal inflow to the liver. As this technique was developed fur-

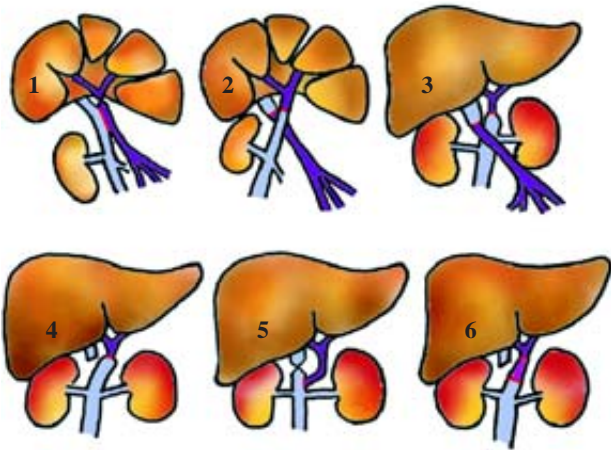


Figure 2. Evolution of cavoportal hemitransposition (vena cava on light blue, portal vein on purple, venous graft on pink, anastomosis on red): **1.**1877, Eck – Fistula in canine liver; **2.** 1953 (CG Child), cavoportal transposition in canine liver; **3.** 1964 (Starzl), cavoportal transposition in glycogen storage disease; **4.** 1998 (Tzakis), cavoportal hemitransposition end-to-end for PVT +/- BCS; **5.** 1998 (Tzakis), cavoportal hemitransposition end-to-side; **6.** 2005 (Ceulemans), cavoportal hemitransposition with interposition iliac vein graft. Figure designed and produced by Dr. D.H. Borchert © 2005.

ther, it was noted by Starzl et al. that the full transposition was not needed, the anastomosis between the distal portal vein and the proximal part of the inferior vena cava could safely be spared and a hemitransposition might be sufficient.⁶⁵ This led to the development of «cavoportal hemitransposition», which involves only half of the original, complete transposition of the portal vein and vena cava. The complete «cavoportal transposition» can only be performed, if both the IVC and the portal venous system are patent. CPHT was introduced for patients in urgent need of a liver transplantation, who have complete thrombosis of the portal-venous system following a report by Tzakis et al. in 1998 (Fig. 2/4 and 5). In this first publication on CPHT the experience of four transplant centres was summarized.¹⁸

Nomenclature

Tzakis et al. used the term *cavoportal hemitransposition* (CPHT) in the title of their original report, but also coined the term *portocaval hemitransposition* together with abbreviation «PCHT». Both terms were used interchangeably in the original article. The term *portocaval hemitransposition* was also used by Weeks et al. (2000), Wang et al. (2000), Pinna et al. (2001) and Lipshutz et al. (2006). In seventeen publications the authors used the term *cavoportal hemitransposition*. One author titled the procedure *cavoportal transposition*.²⁹ Historically the term *cavoportal hemitransposition* is correct, because it describes the procedure as being only half of the original *cavoportal transposition*.

Current technique

Cavoportal hemitransposition is indicated in the presence of complete thrombosis of the portal venous system, with or without Budd–Chiari syndrome. In cavoportal hemitransposition, the donor portal vein stump is anastomosed to the recipient inferior vena cava, above the renal veins. The lower end of the donor inferior vena cava (IVC) is unused and ligated (Fig. 2/4). If conventional hepatectomy precedes cavoportal hemitransposition, blood flow can be restored using the donor portal vein for an end-to-end anastomosis to the recipient IVC. If preceded by piggy-back hepatectomy, cavoportal hemitransposition can be carried out using the donor portal vein for end-to-side anastomosis to the recipient IVC (Fig. 2/5). In one case, an iliac vein graft was used for interposition between the donor portal vein and the recipient IVC to allow for the difference in size of the vessels (Fig. 2/6).⁴¹ In eleven cases an iliac vein graft was used as a conduit, from the recipient IVC to the donor portal vein, in an end-to-side technique.^{27-29,37,41,43} In end-to-side cavoportal hemitransposition, the recipient IVC is tied off above the anastomosis. In end-to-end anastomosis there may be a considerable difference in the size of the IVC and the donor portal vein.

Advantages and pitfalls (Benefits and problems)

Advantages

The technique of CPHT has developed over more than a century from the Eck-Fistula to the report of Tzakis et al. Since the first multicentre report in 1998 seventy-one cases have been reported in the international literature. Liver failure combined with complete portal venous system thrombosis has been regarded as an untreatable condition for a long time. CPHT is the surgical procedure that has successfully proven that liver transplantation is not contraindicated in the presence of portal vein system thrombosis. But the situations where portal venous inflow can not be re-established by any other means are rare and in these instances CPHT is a «last resort» procedure.^{17,48} Thus the advantage of CPHT is to rescue a patient, where no other strategies are available. A cornerstone of CPHT is to divert flow of the IVC completely to the donor portal vein to achieve a good portal inflow and to prevent re-thrombosis. So far in seven cases recurrence of portal vein thrombosis has been mentioned as a complication after CPHT.^{33;35;37;41;45;46} But eight patients developed thrombosis of the IVC below or above the renal veins after CPHT. If good flow through the donor portal vein is not achieved, then thrombosis of the portal vein is likely to happen as demonstrated by the case report of Ho et al. In complete thrombosis of the mesenteric venous system multivisceral transplantation is an alternative option to CPHT. Compared to CPHT, multiviscer-

al transplantation is technically and immunologically more challenging. Another advantage of CPHT is to prevent extensive dissection of mesenteric veins. This can cause pancreatitis and increase damage to the mesenteric venous and arterial supply.^{13,16} However this is only possible if a decision is made preoperatively. This might not always be possible and in some centres extensive mesenteric dissection is thought to be essential to find any suitable mesenteric vein for reconnection to the portal system.^{17,18} In case of re-transplantation, CPHT can be regarded as a last resort procedure as well, if the vascular situation is deranged to a degree leaving no other option to re-establish portal inflow. CPHT has been used as a salvage procedure in re-transplantation in seven cases so far.^{17,18,29,36,37,43} CPHT does not correct or cure portal hypertension, but may attenuate its severity. Authors reported the presence of signs of portal hypertension at least in 31 cases prior to CPHT (*Table I*). These signs persisted reportedly in 18 patients. In seven patients author's explicitly stated the disappearance of the symptoms of portal hypertension.

Pitfalls

During recipient hepatectomy access to the portal pedicle can be complicated when there has been longstanding thrombosis of the portal-venous system and numerous collaterals have developed. Four authors reported the existence of portal cavernoma, which can complicate the procedure and lead to significant bleeding.^{30,40,41,44} Some authors have considered the existence of these cavernomas and collateral vessels, a contraindication for liver transplantation.¹⁴ Patients undergoing CPHT presented in several cases with symptoms and signs of portal hypertension. Given the risk of bleeding from oesophageal and gastric varices, several

authors attempted to decompress the portal system or prevent gastro-oesophageal bleeding either before, during or following liver transplantation. In eight cases, a splenectomy was performed during transplantation,^{37,39,41} in five cases gastric devascularization was carried out; and in seven cases, the portal system was drained using interpositional grafts, or collaterals for shunting the venous blood back to the liver (*Table II*).^{36,37,41} In attempts to redirect venous flow, portal hypertension persisted especially in patients where it existed already preoperatively.⁴⁴

Despite refashioning the venous circulation in cavoportal hemitransposition in a non-anatomical way, no immediate problems with venous return or blood pressure have been reported. Even so, long-term changes in the venous system are possible after this operation. The development of a collateral venous circulation has been noted from previous experience with CPHT in animals and humans.⁶⁵ In their initial report, Tzakis et al. proposed ligation of the right adrenal vein to prevent this from occurring and this has been also reported by Gerunda et al.^{18,30} In the remaining twenty-one reports, no information is given about preventing the formation of collaterals to the IVC. Whether this is necessary or not remains a question of patient follow-up. As partial or complete re-thrombosis of the portal venous system after CPHT has been reported in seven cases so far, embolization of the portal vein from thrombi of the lower extremities remain a threat. This has been clearly shown in the reports by Weeks et al and Shrotri et al. To date no reports exist on the preoperative evaluation of lower leg and/or pelvic thrombosis in CPHT and the use of perioperative calf compression and caval filter. Moreover pulmonary embolism is not banned due to ligation of the IVC. Instead at least three cases of upper extremities thromboembolism causing pulmonary artery emboli have been reported.^{18,37,39}

Table I. Demographic data, underlying liver disease and preoperative status.

Demographic data		Underlying disease + PVT/N		Pretransplant condition/N	
Male/N	34 ^{15,18,26,28,30,33,35,37,39,41-44,47,47}	HCV	9 ^{18,35,38,39,42}	Ascites pre Tx	37 ^{18,26,29,30,33,37,39,44,47}
		HBV	10 ^{18,30,33,41,45,47}	Encephalopathy pre Tx	30 ^{26,27,33,39,47}
Female/N	35 ^{18,29,35-37,39,39-42,44,47,47}	Other viral	6	Signs of portal hypertension	31 ^{18,26,27,29,30,32,33,37-39,41,42,47}
sex unknown	2 ^{32,34}	Cryptogenic	9 ^{18,26,29,35,39}	Decision for CPHT pre Tx	38 ^{18,26,29,30,35,38-42}
recipient-age range/years	0.5-71 ^{18,29,35,37,41,44}	EtOH	7 ^{28,30,35,41,44}	Decision for CPHT intraop	21 ^{18,30,32,33,35,41,43,47}
Donor age range/years	3.5-82	Biliary atresia	8 ^{17,18,32,43}	Paediatric portoenterostomy	9 ^{17,32,36,43}
CPHT for previous Oltx	7 ^{17,18,27,29,37,43}	Budd Chiari	7 ^{18,29,39,40}	Portosystemic shunt pre Tx	6 ^{18,30,37,39}
CPHT for previous CPHT	5 ^{17,35,36,41}	Coagulation disorder	4 ^{39,40,43,44}	Variceal bleeding pre Tx	24 ^{26,33,38,39,44,47}
		Other	9	Gastric devascular pre Tx	8 ^{18,33,37}
		Hospital/ICU	28	Splenectomy pre Tx	10 ^{33,37,39,47}
				Peritonitis prior to Tx	3 ^{18,27,30}

Abbreviations: Bold numbers if not stated otherwise are numbers of cases; CPHT cavoportal hemitransposition; oLTX standard orthotopic liver transplantation; HCV hepatitis C virus cirrhosis; HBV hepatitis B virus cirrhosis; EtOH alcohol related liver disease; pre Tx prior to transplantation.

Table II. Surgical technique and postoperative complications.

Collateral circulation & bleeding/N		Complications/N		Thrombotic events & anticoagulation/N	
Adrenal vein ligated	11 ^{18,30}	Ascites postop	43 ^{18,26,29,30,32,33,35,37-39,41,43,47}	Donor Re-PVT	7 ^{33,35,37,41}
Adrenal vein not mentioned/cases	60 ^{15,17,26,28,29,32-45,47}	«No signs of liver stasis»	5 ^{18,39,41,42,47}	Hepatic artery thrombosis	5 ^{35,39,41}
Splenectomy at Tx	8 ^{37,39,40}	oLTX-Re-CPHT	7 ^{17,18,27,29,37,43}	Hepatic vein thrombosis/Re-BCS	2 ^{33,45}
Gastric devasc. at Tx	5 ³⁷	CPHT-Re-CPHT	5 ^{17,35,36,41}	IVC	8 ^{33,35,39,45}
Drainage of portal system at Tx	7 ^{36,41,42}	Graft non/delayed function	6 ^{17,18,43}	thrombosis	3 ^{18,37,39}
CPHT with iliac vein interposition	11 ^{26,28-30,35,37,38}	Rejection	10 ^{18,26,29,30,36,39,47}	Leg or pelvic thrombosis	6 ^{35,37}
Cava not ligated but calibrated	2 ^{18,26}	Delayed abdo closure	7 ^{32,35,37,43}	Other thrombosis	2 ^{39,40}
Whole cadaveric graft	62	Renal impairment	29 ^{18,26,29,30,35,37,38,43,44,47}	Routine anticoag	12 ^{26,29,36,38-41,44,47}
Left lateral segment graft	7	Pneumonia	5 ^{26,30,35,38}	Anticoag. No statement	6 ^{18,26,30,35,37,42,45}
Cold ischaemia range/hours	5-13	Variceal bleed postop	17 ^{26,29,30,35,37-39,47}	Restricted diet	2 ⁴⁴
Warm ischaemia range/mins	49-70	Hypersplenism postop	9 ^{17,32,37,41,43,44}	Peritonitis	2 ^{30,32}
Duration of Tx range/hours	9-22	Hospital stay range/days	17-145 days	Collaterals diverting blood away from PV	4 ^{17,33,45}
Blood transfusion rang/Units	2-16 ^{32,41,43}	Death	32 ^{17,18,26,28-30,34,35,37,39,41,45,47}	Signs of portal hypertension postop	18 ^{18,26,29,30,37,38,41,43,44}

Abbreviations: Bold numbers if not stated otherwise are numbers of cases; IVC inferior vena cava; PVT portal vein thrombosis; PV portal vein; oLTX – Re-CPHT retransplantation after orthotopic liver transplantation using CPHT; CPHT – Re-CPHT retransplantation after CPHT using CPHT.

Patients reviewed

Demography

In the reviewed reports on CPHT, the median age of recipient ranged from 0.5 month to 71 years and donor age ranged from 3.5 to 82 years (*Table I*). In 35 cases the patients were female, in 34 cases male and in two case the gender was not given.^{32,34} Eleven patients out of seventy-one reported are paediatric patients. Thirty-four cases have been operated on in the USA, thirty-one in Europe, five in Asia and one in Australia. All of these patients had extensive thrombosis of the portal venous system. The majority of patients presenting with portal venous thrombosis had end stage liver disease due to viral disease, hepatitis B and C, ethanol related and cryptogenic cirrhosis. Seven had combined portal vein thrombosis and Budd Chiari syndrome. In only five of the patients an underlying or associated coagulation disorder was diagnosed.^{39,40,43,44} Paediatric patients presented with atretic portal vein, portal vein agenesis or portal vein thrombosis after previous portoenterostomy. Several patients had surgical and endoscopic procedures for sequelae of portal hypertension before CPHT. Reflecting the severity of the underlying condition more than half of the patients have been hospitalised and on ITU prior to CPHT. Patients displayed symptoms of end stage liver failure and portal hy-

perension in the majority of cases and were described as moribund by several authors.

Indication and selection

The presence of thrombosis of the portal-venous system, Budd-Chiari syndrome or both at the same time, may lead to the complications of portal hypertension or either acute or chronic liver failure. Cavoportal hemitransposition is used as a life-saving procedure when the portal venous system is thrombosed and inflow into the hepatic portal system cannot be established by any other technique. Patients in the reviewed reports presenting with thrombosis of the portal venous system or congenital absence of appropriate portal inflow, were critically ill. In these patients, portal inflow needs to be re-established as a matter of urgency. If the liver is severely damaged they may undergo urgent liver transplantation. Thrombosis of the portal-venous system is technically no longer a contraindication for liver transplantation.⁶⁶ In Budd-Chiari syndrome, the venous outflow from the liver is compromised. When this occurs in addition to thrombosis of the portal-venous system, posthepatic liver failure results. Patients with this condition deteriorate even more rapidly and need urgent surgery to rectify the underlying cause. Thus, the main selection criteria for cavoportal hemitransposition are thrombosis of the portal

venous system, either alone, or in combination with Budd–Chiari syndrome; and more importantly, the associated liver failure. Selection criteria in cavoportal hemitransposition are based on individual cases and experience. In most case reports, adult patients were preoperatively selected for cavoportal hemitransposition upon findings from radiological imaging. In nine out of eleven paediatric patients the decision for CPHT was made intraoperatively. Thrombosis of the portal-venous system was commonly related to underlying viral disease (N = 25), cryptogenic cirrhosis (N = 9), alcoholic cirrhosis (N = 7), or other liver disease (N = 30) (*Table I*). Seven patients have undergone CPHT as a re-transplantation procedure for a failing liver graft from prior orthotopic liver transplantation.^{17,18,27,29,37,43} In five cases CPHT was followed by CPHT as a retransplantation procedure.^{17,35,36,41} In at least 38 patients, it was known prior to transplantation, that the portal–venous system was thrombosed and CPHT was planned as the surgical procedure. In 21 patients, the decision to use CPHT was made intraoperatively.

The consequences of deteriorating liver function and portal hypertension, such as ascites, encephalopathy and variceal bleeding, were not a contraindication to CPHT for most surgical teams. However, the «absence of ascites» and «absence of serious gastroscopic signs of portal hypertension» were reported by Urbani et al. as selection criteria for the procedure.⁴¹ In all the other reports, patients presented with classical features of portal hypertension associated with liver disease and deteriorating liver function. Ascites was reported in 37 patients, and encephalopathy in 30 patients prior to transplantation. Several patients presented with complications of portal hypertension prior to transplantation and underwent surgical procedures to correct these (*Table I*). Six patients had shunts from the portal vein to systemic veins, twenty-four had variceal bleeding, eight patients had gastric devascularization and ten patients underwent splenectomy prior to transplantation. Further factors influencing selection for CPHT are preoperative renal impairment or renal failure; extensive previous abdominal surgery;^{18,35} previous irradiation for malignancy; spontaneous bacterial peritonitis;³⁰ and a history of a coagulation disorder.^{35,39,40,44} The most important factor however is the vascular status of the donor as diagnosed pre- and intraoperatively. The size, flow and fragility of the vessel wall from any portal - mesenteric veins will lead to a decision for or against CPHT. In cases where CPHT was used as a re-transplantation procedure the previous standard orthotopic liver transplantation either used a corrected hypoplastic portal vein or its confluents, or thrombectomy from the portal - mesenteric system was performed and the anastomosis done in an anatomical way. In these cases the result was rethrombosis, leaving CPHT as the only viable option at re-transplantation to establish adequate inflow into the graft portal system.^{18,27,43}

Surgical differences

The technique of CPHT has been used in situations where the vascular status allowed no other reconstruction than use of the IVC to achieve adequate portal inflow to the graft. The connection between the IVC and the graft portal system can be done in mainly two ways; an end-to-end or an end-to-side anastomosis between donor portal vein and recipient suprarenal IVC. The end-to-side anastomosis can be done either using the donor portal vein directly or using an interposition graft (donor iliac vein). To perform the end-to-end anastomosis, the IVC has to be size adjusted to the donor portal vein or iliac vein graft. End-to-end anastomosis were used in fifty-one cases and end-to-side anastomosis in twenty cases and from these, iliac vein grafts were used in eleven cases. Numbers may slightly differ here from the true numbers of patients and operations, as this figure could not be exactly differentiated in the partial double reporting of Tzakis et al. and Pinna et al.

Another important step in liver transplantation with CPHT is the use of conventional hepatectomy or piggy-back technique. If the native vena cava is preserved the IVC can be tied off above the cavoportal anastomosis or calibrated with a sleeve or clip. If the IVC was left open, the donor portal vein is likely to thrombose as the flow is diverted away along the anatomical venous return to the right heart. In sixty-two cases a whole cadaveric liver graft was used for CPHT and in six cases a left lateral segment for paediatric transplantation. CPHT corrects liver failure but does not reverse portal hypertension. In seven cases authors combined CPHT with drainage of the portal - mesenteric system. Urbani et al created surgical shunts in five of their patients and Varma et al. anastomosed a retroperitoneal varix to the donor portal vein to provide drainage. In the report from Varma et al. the shunt was patent one month after the operation.

Twelve authors started their patients on postoperative anticoagulation, and this was inherent to some of the liver transplant protocols.^{17,26,27,29,36,38-41,44,46,47} Another nine authors did not mention anticoagulation at all.^{18,28,30,32-35,37,42}

Complications

The complications caused by thrombosis of the portal and mesenteric venous system should be divided into three groups: pre-, intra- and postoperative. The preoperative symptoms should be rectified by the surgical procedure, so the recurrence of these symptoms postoperatively can be used as a measure of the effectiveness of cavoportal hemitransposition as a treatment for these critically ill patients.

The main preoperative complications arise from liver failure and portal hypertension. Gastroesophageal varices, haemorrhage and ascites are nearly universal in

theses patients. In at least 31 of the cases, patients displayed signs of portal hypertension preoperatively. In seven cases authors specifically reported the absence of these symptoms. Preoperatively, surgical portosystemic shunts were carried out in six patients; twenty-four patients had endoscopies for variceal bleeding; eight patients underwent gastric devascularization; and ten had splenectomies. Postoperatively; seventeen patients had gastro-oesophageal bleeding^{26,29,30,35,37-39,47} and in nine patients hypersplenism developed or persisted.^{32,37,41,43,44} The majority of patients had varying degrees of recurrent ascites post-transplantation (N = 43) (Table II).^{18,32,33,35,37-39,41,43,44,47} Only one author mentioned the continued need for diuretic therapy and restricted diet after cavoportal hemitransposition.⁴⁴

Intraoperative complications include bleeding from extensive collaterals and massive bowel oedema, leading to delayed closure of the abdomen, as reported in seven cases.^{32,35,37,43} Postoperatively increased blood supply to the liver can be expected immediately after CPHT. Four groups reported, explicitly, that there were no signs of congestion in the transplanted organ.^{18,35,41,42} This is similar to living donor liver transplantation, where there is increased portal inflow into the grafted liver lobe and congestion is usually not observed.^{67,68} However, in small-for-size grafts, portal hyperperfusion can lead to early graft failure.^{69,70} «Portal hyperperfusion injury» is theoretically possible in full-sized liver grafts, as reported elsewhere.^{71,72} Thrombotic events form a further category of postoperative complications. Donor portal vein thrombosis was reported in seven cases.^{33,35,37,41,45} In two cases similar symptoms for donor portal vein thrombosis have been reported. These two patients were both found to have left lower/upper quadrant pain and fever and both had apparently emboli from lower leg thrombosis to the portal vein.^{40,46} Hepatic artery thrombosis has been reported in five cases;^{35,39,41} thrombosis of the inferior vena cava in eight cases; lower limb or pelvic thrombosis in six cases;^{35,37} pulmonary embolism in three cases^{18,37,39} and other thrombotic events in two cases.^{39,40} Recurrence of hepatic vein thrombosis (Re-BCS, table II) has been reported in two case leading to a situation, where the hepatic artery was the only blood supply to the liver and the blood flow reversed in the portal vein as the only vessel draining the liver.^{33,45} The first of these cases reported in 2005 from Peking University died from recurrent and metastatic liver disease after ten month but did not display liver dysfunction or signs of Budd-Chiari syndrome according to the authors. The second case reported in 2008 from Sichuan University is well and alive after one and a half years follow-up. Cavoportal hemitransposition has challenged the understanding of liver physiology in these two cases. Re-transplantation was carried out in seven cases for previous standard orthotopic liver transplantation and in five cases for previous CPHT.^{17,18,27,29,35-37,41,43} Ten episodes of rejection have

been reported.^{18,26,29,30,33,36,39} The majority of patients developed varying degrees of renal impairment (N = 29) and four patients needed dialysis. Five episodes of pneumonia in the immediate post-transplant hospital stay have been documented in the reports. Nearly half of patients, published from 1998 – 2008, have died (N = 32).^{18,26,28-30,34,35,37,39,41,45,47} In the majority of the remaining patients, postoperative complications have settled, suggesting that CPHT can be regarded as an effective treatment for thrombosis of the portal-venous system.

Outcome of patients

The peri – and postoperative complications resulting from cavoportal hemitransposition are not unique to this procedure, but resemble the spectrum of complications from liver transplantation. The surviving patients are mainly «alive and well», including three paediatric patients, as reported in the available literature. Surviving patients returned to normal activities and had normal liver function tests. Their conditions range from «patient remains at home»²⁶ to «enjoying normal life»⁴¹ to «excellent condition».¹⁸ Dietary restrictions were mentioned in one report. The main symptoms from portal hypertension, such as ascites and bleeding from gastro-oesophageal varices, had resolved. The series of Ceulemans et al., showed a slow recovery from pre-transplant portal hypertension and prolonged hospital stay. Thirty-two out of 71 patients did not survive. Two patients died from primary non-function of the liver graft, and one died of primary dysfunction of the liver after four weeks.^{17,18} Other causes of death were rejection (2),^{26,30} pulmonary embolism (2),^{18,37} sepsis/multi-organ failure (7, (18;29;35;37;41)) and cardiac failure (2).^{28,37} Late deaths also occurred at seven months, ten months and one year post-transplantation. Twelve patients died within four weeks of the operation, indicating the severity of the underlying disease. In the report of Lipshutz et al. two paediatric patients out of seven are longterm survivors with 4 and 8 years posttransplant respectively.

Collateral circulation

In cavoportal hemitransposition, the venous flow from the IVC is diverted to the liver to substitute for the lost venous inflow from the portal-venous system. Experimental studies in dogs and portacaval transposition for inherited liver disease have shown that this technique is feasible. It allows for normal liver function and cure of the underlying disease without causing hepatic congestion from increased venous inflow.^{61,73} One of the long-term problems with this technique is that blood flow can be diverted away from the liver again, through developing collaterals. Preexisting collateral pathways, such as the azygos system, may enlarge.⁶³ Both Tzakis et al. and Gerunda et al. noted that they were careful to

ligate the right adrenal vein.^{18,30} In one case the caval flow was diverted through the azygos system after six months despite intraoperative ligation of the right adrenal vein.³⁰ Cavoportal collateral pathways have been reported in chronic obstruction of the inferior vena cava by several groups, including Dahan et al.. This group described the following collateral pathways: a) cavo – superficial – umbilical – portal, b) cavo – mammary – phrenic – hepatic capsule – portal, c) cavo – mesenteric – portal, d) cavo – renal – portal and cavo – retroperitoneal – portal and e) intrahepatic cavoportal pathways.⁷⁴ This suggests that the development of collateral pathways is unpredictable. So far, there have been no reports of problems associated with the haemodynamic changes that occur following ligation of the IVC, proximal to the cavoportal anastomosis. Similarly, there have been no negative reports of the effect of collaterals diverting venous flow away from the liver, after cavoportal hemitransposition. In this regard the significance of the drainage of the portal system in CPHT as reported in seven cases remains to be elucidated. Bypassing venous flow to the liver can lead to symptoms similar to those prior to transplantation. Conversely persisting extensive collateral veins may contribute to the success of CPHT, bypassing and forwarding enough blood from the infra-anastomotic area to support cardiac output.³⁸ Due to the relatively rare and young nature of cavoportal hemitransposition, no state of the art technique has been described, which would allow surgery to be carried out in a standardized manner. This is reflected by the different surgical approaches described in the published case reports, for example Varma et al. divided the IVC just above the right renal vein, whereas Shrotri et al. divided the IVC 7 cm above the right renal vein. Most of the authors did not report ligation of the adrenal veins. Investigations on development of collaterals postoperatively are missing in most reports. Anatomically, collateral pathways can vary considerably, especially those involving the azygos and hemiazygos system.⁷⁵ In a study of the anatomy of the adrenal venous system, Monkhouse et al. found the right adrenal vein to be located at an average of 45 mm (range 0 – 85 mm) above the entry of the right renal vein.⁷⁶ The right adrenal vein can be duplicated or triplicated, and there can be connections of accessory veins with the right renal vein and the inferior phrenic vein. The situation with the left adrenal vein is even more complicated. In 42 out of 57 cadavers, studied by Monkhouse et al., venous communications from the adrenal glands to the renal, lumbar and azygos/hemiazygos system were found. In another study, twenty-one different patterns of the lumbar and azygos vein system were reported.⁷⁷ Therefore, the development of collaterals is unpredictable, even following ligation of the right adrenal vein. The longterm effects of diversion of venous blood away from the porta hepatis in these patients has not been assessed.

Unresolved questions

So far, no consensus has been reached about the surgical technique of CPHT. This will probably be difficult to achieve, as cases are rare with unique individual situations and treatment options depend on local expertise and knowledge. This situation is similar for the treatment of the two-system thrombosis of BCS-PVT. Despite thrombosis as the underlying clinical feature in all cases anticoagulation seems not to be an agreed postoperative treatment strategy. Still individual steps in treatment strategies are already established and might become more accepted internationally with continued research. Pinna et al. reported that none of their patients who underwent intraoperative splenectomy developed recurrent bleeding from gastro-oesophageal varices postoperatively. The follow-up report from the same group six years later stated that splenectomy at the time of transplantation has been abandoned because of a case with lethal overwhelming post-splenectomy infection.³⁹ As postoperative haemorrhage is a severe complication, it may be possible to prevent postoperative bleeding further by evaluating oesophagogastric varices intraoperatively. This could be an important step towards improvement of the technique. But preventing postoperative bleeding by gastric devascularization or splenectomy may increase the risk of recurrence of portal–venous thrombosis. Two authors reported recurrence of portal–venous thrombosis in patients who had undergone splenectomy. Several groups, including Settmacher et al., reported splenectomy as a risk factor for portal–venous thrombosis following liver transplantation.^{37,41,78} From a pathophysiological point of view the development and effect of major collateral vessels, bypassing venous flow through the azygos system, remains another question to be answered by patient follow-up. Patients who develop collateral circulation need to be compared with patients where the venous flow from the IVC through the liver is completely preserved. Gerunda et al. reported that one of their patients developed collateral flow through the azygos systems, even so the right adrenal vein had been ligated.³⁰ Given the complex anatomy of adrenal veins and other collateral systems, the likelihood of diverting blood away from the liver through these collaterals is very high. Regarding the selection criteria for CPHT, the question remains as to what extent portal tributaries should be evaluated and used to preserve the complete IVC or if CPHT is used, shunts should be performed using these tributaries to drain the portal – mesenteric system. Moreover, careful postoperative anticoagulation is necessary due to a high incidence of posttransplant thromboembolic events (*Table II*). This is even more important as coagulation disorders associated with the pre-transplant thrombotic events may still be undiagnosed after transplantation. Anticoagulation should probably also be continued if underlying diseases like antithrombin III or protein C deficiency were seem-

ingly cured by liver transplantation. This is because existing lower leg or pelvic thrombosis may be a threat to the donor portal system in CPHT and in view of a high incidence of multiple factors contributing to BCS-PVT, individual or local factors may have been undiagnosed and/or persisting.²⁴ Given the two reports about embolization of the donor portal vein by emboli from lower leg or pelvic thrombosis, the use of caval filters in patients undergoing CPHT should be discussed.

The case reports of Wang et al. and Li et al. on compensatory blood supply through the hepatic artery in cases of new-onset or recurrent BCS-PVT after CPHT raise an interesting question.^{10,33,45} If liver function can be maintained by arterial perfusion only in a situation where hepatic venous outflow is obstructed and the portal vein is hypoperfused or even draining the liver, could then liver transplantation be performed without an attempt to restore portal venous flow at all? This question should certainly be subject to experimental research in the future.

The geographic distribution of cavoportal hemitransposition as a surgical procedure is confined to USA, Canada, Italy, France, Belgium, England, Denmark, Sweden, China and Australia. Despite reports from Asian countries about significant numbers of BCS and PVT only three reports about the use of this surgical procedure are available from the eastern hemisphere (all reports to date are from China).

Emerging radiological approaches

Radiological interventional techniques are replacing surgical techniques in several areas. In many case reports transjugular portosystemic shunting (TIPS) and fragmentation or thrombolysis have been shown to be an effective rescue procedure in acute combined BCS/PVT.⁷⁹⁻⁸³ Even in re-thrombosis after CPHT thrombolysis has been used as a rescue procedure in two cases.^{33,84} However, this might not be possible in organized thrombosis of either of the two venous systems, or if severe liver failure is present. Even adequate radiological facilities might fail to establish the diagnosis and if radiological intervention is used as a first line treatment option, surgical back-up is needed. In the multicenter study of Murad et al. only four out thirtythree patients with combined BCS/PVT had a TIPS inserted. In one of these patients TIPS failed and a rescue cavoportal (without transplantation) shunt was needed.²⁴

Conclusion

So far seventy-one patients have been reported to have had CPHT as a surgical procedure worldwide. This operation has been used in situations where urgent liver transplantation was the only way to save patient life and it was not possible to re-establish blood flow to the do-

nor *porta hepatis* by any other method. Thrombosis of the IVC and portal-venous system is associated with a variety of underlying diseases. Despite improved diagnostic techniques, this condition may only be discovered for the first time intraoperatively. In at least twenty-one cases, the decision to carry out CPHT was made intraoperatively. Budd-Chiari syndrome associated with thrombosis of the portal system is rare and is associated with rapid deterioration. CPHT has proved to be a successful alternative to combined small bowel and liver transplantation. The reviewed cases point towards the establishment of a sequential therapeutic approach. Where liver function allows, interventional radiology might be used as first-line treatment. Failure of this approach to re-establish blood flow might lead to severe liver damage and failure. This would also document the severity of thrombosis in both venous systems, and would need to be followed by a second-line treatment such as CPHT, or combined small bowel and liver transplantation.

Conflict of interests: None

Acknowledgements: The author was able to study two patients after CPHT in the Department of Surgery at Addenbrookes Hospital, Cambridge University, Cambridge, UK (one of these cases was published by Shrotri et al.).

I am very grateful for repeated discussion of the manuscript with Dr. H. Vilca-Melendez, consultant transplant surgeon at Kings College Hospital, Denmark Hill, London, UK.

References

1. Ludwig J, Hashimoto E, McGill DB, van Heerden JA. Classification of hepatic venous outflow obstruction: ambiguous terminology of the Budd-Chiari syndrome. *Mayo Clin Proc* 1990; 65(1): 51-5.
2. European Network for the vascular disease of the liver. Guidelines for the management of patients with Budd-Chiari syndrome. www.mh-hannover.de/kliniken/gastro/vasc/guideline_BCS.pdf, 1-33. 2005.
3. Feng LS, Peng QP, Li K, et al. Management of severe Budd-Chiari syndrome: report of 147 cases. *Hepatobiliary Pancreat Dis Int* 2004; 3(4): 522-5.
4. Xu PQ, Ma XX, Ye XX et al. Surgical treatment of 1360 cases of Budd-Chiari syndrome: 20-year experience. *Hepatobiliary Pancreat Dis Int* 2004; 3(3): 391-4.
5. Jamieson NV, Williams R, Calne RY. Liver transplantation for Budd-Chiari syndrome, 1976-1990. *Ann Chir* 1991; 45(4): 362-5.
6. Orloff MJ, Daily PO, Orloff SL, et al. A 27-year experience with surgical treatment of Budd-Chiari syndrome. *Ann Surg* 2000; 232(3): 340-52.
7. Ulrich F, Steinmuller T, Lang M, et al. Liver transplantation in patients with advanced Budd-Chiari syndrome. *Transplant Proc* 2002; 34(6): 2278.
8. Menon KV, Shah V, Kamath PS. The Budd-Chiari syndrome. *N Engl J Med* 2004; 350(6): 578-85.
9. Srinivasan P, Rela M, Prachalias A, et al. Liver transplantation for Budd-Chiari syndrome. *Transplantation* 2002; 73(6): 973-7.
10. Cazals-Hatem D, Vilgrain V, Genin P, et al. Arterial and portal circulation and parenchymal changes in Budd-Chiari syndrome: a study in 17 explanted livers. *Hepatology* 2003; 37(3): 510-9.

11. Tanaka M, Wanless IR. Pathology of the liver in Budd-Chiari syndrome: portal vein thrombosis and the histogenesis of veno-centric cirrhosis, veno-portal cirrhosis, and large regenerative nodules. *Hepatology* 1998; 27(2): 488-96.
12. European Network for the vascular disease of the liver. Guidelines for the management of patients with portal vein thrombosis. www.mh-hannover.de/kliniken/gastro/vasc/guideline_PVT.pdf. 2005.
13. Stieber AC, Zetti G, Todo S, et al. The spectrum of portal vein thrombosis in liver transplantation. *Ann Surg* 1991; 213(3): 199-206.
14. Yerdel MA, Gunson B, Mirza D, et al. Portal vein thrombosis in adults undergoing liver transplantation: risk factors, screening, management, and outcome. *Transplantation* 2000; 69(9): 1873-81.
15. Bertelli R, Nardo B, Montalti R, et al. Liver transplantation in recipients with portal vein thrombosis: experience of a single transplant center. *Transplant Proc* 2005; 37(2): 1119-21.
16. Brancatelli G, Federle MP, Pealer K, Geller DA. Portal venous thrombosis or sclerosis in liver transplantation candidates: preoperative CT findings and correlation with surgical procedure. *Radiology* 2001; 220(2): 321-8.
17. Lipshutz GS, Patel S, Hiatt JR, et al. Portocaval hemitransposition in pediatric liver transplant recipients: a single-center experience. *Liver Transpl* 2006; 12(7): 1097-103.
18. Tzakis AG, Kirkegaard P, Pinna AD, et al. Liver transplantation with cavoportal hemitransposition in the presence of diffuse portal vein thrombosis. *Transplantation* 1998; 65(5): 619-24.
19. Cohen J, Edelman RR, Chopra S. Portal vein thrombosis: a review. *Am J Med* 1992; 92(2): 173-82.
20. Shaked A, Busuttill RW. Liver transplantation in patients with portal vein thrombosis and central portacaval shunts. *Ann Surg* 1991; 214(6): 696-702.
21. Nonami T, Yokoyama I, Iwatsuki S, Starzl TE. The incidence of portal vein thrombosis at liver transplantation. *Hepatology* 1992; 16(5): 1195-8.
22. Bhattacharyya M, Makharia G, Kannan M, et al. Inherited prothrombotic defects in Budd-Chiari syndrome and portal vein thrombosis: a study from North India. *Am J Clin Pathol* 2004; 121(6): 844-7.
23. Mahmoud AE, Helmy AS, Billingham L, Elias E. Poor prognosis and limited therapeutic options in patients with Budd-Chiari syndrome and portal venous system thrombosis. *Eur J Gastroenterol Hepatol* 1997; 9 (5): 485-9.
24. Murad SD, Valla DC, de Groen PC, et al. Pathogenesis and treatment of Budd-Chiari syndrome combined with portal vein thrombosis. *Am J Gastroenterol* 2006; 101(1): 83-90.
25. Tang TJ, Batts KP, de Groen PC, et al. The prognostic value of histology in the assessment of patients with Budd-Chiari syndrome. *J Hepatol* 2001; 35(3): 338-43.
26. Azoulay D, Hargreaves GM, Castaing D, Bismuth H. Caval inflow to the graft: a successful way to overcome diffuse portal system thrombosis in liver transplantation. *J Am Coll Surg* 2000; 190(4): 493-6.
27. Bakthavatsalam R, Marsh CL, Perkins JD, et al. Rescue of acute portal vein thrombosis after liver transplantation using a cavoportal shunt at re-transplantation. *Am J Transplant* 2001; 1(3): 284-7.
28. Bernardos A, Serrano J, Gomez MA, et al. Portal vein thrombosis: an emergency solution for blood flow in liver transplantation. *Transpl Int* 2003; 16(8): 500-1.
29. Ceulemans B, Aerts R, Monbaliu D, et al. Liver Transplantation using cavoportal transposition: An effective treatment in patients with complete splanchnic venous thrombosis. *Transplant Proc* 2005; 37(2): 1112-4.
30. Gerunda GE, Merenda R, Neri D, et al. Cavoportal hemitransposition: a successful way to overcome the problem of total portosplenomesenteric thrombosis in liver transplantation. *Liver Transpl* 2002; 8(1): 72-5.
31. Ho MC, Hu RH, Lai HS, et al. Liver transplantation in a patient with diffuse portal venous system thrombosis. *Transplant Proc* 2000; 32(7): 2174-6.
32. Kumar N, Atkison P, Fortier MV, et al. Cavoportal transposition for portal vein thrombosis in a pediatric living-related liver transplantation. *Liver Transpl* 2003; 9(8): 874-6.
33. Li FG, Yan LN, Wang WT. Extensive thrombosis of the portal vein and vena cava after orthotopic liver transplantation with cavoportal hemitransposition: a case report. *Transplant Proc* 2008; 40(5): 1777-9.
34. Llado L, Fabregat J, Castellote J, et al. Management of portal vein thrombosis in liver transplantation: influence on morbidity and mortality. *Clin Transplant* 2007; 21(6): 716-21.
35. Olausson M, Norrby J, Mjornstedt L, et al. Liver transplantation using cavoportal hemitransposition - A life-saving procedure in the presence of extensive portal vein thrombosis. *Transplant Proc* 2001; 33(1-2): 1327-8.
36. Ozden I, Suoglu OD, Aydogan A, et al. Successful living-donor liver transplantation and retransplantation with cavoportal hemitransposition: a case report. *Exp Clin Transplant* 2006; 4(2): 562-6.
37. Pinna AD, Nery J, Kato T, et al. Liver transplant with portocaval hemitransposition: experience at the University of Miami. *Transplant Proc* 2001; 33(1-2): 1329-30.
38. Santaniello W, Ceriello A, Defez M, et al. Liver transplant with cavoportal hemitransposition for portal and mesenteric thrombosis: case report. *Transplant Proc* 2001; 33(1-2): 1488-9.
39. Selvaggi G, Weppler D, Nishida S, et al. Ten-year experience in porto-caval hemitransposition for liver transplantation in the presence of portal vein thrombosis. *Am J Transplant* 2007; 7(2): 454-60.
40. Shrotri M, Sudhindran S, Gibbs P, et al. Case report of cavoportal hemitransposition for diffuse portal vein thrombosis in liver transplantation. *Transplant Proc* 2003; 35(1): 397-8.
41. Urbani L, Cioni R, Catalano G, et al. Cavoportal hemitransposition: patient selection criteria and outcome. *Transplant Proc* 2002; 34(8): 3331-3.
42. Varma CR, Mistry BM, Glockner JF, et al. Cavoportal hemitransposition in liver transplantation. *Transplantation* 2001; 72(5): 960-3.
43. Verran D, Crawford M, Stormon M, Shun A. Liver retransplantation in an infant requiring cavoportal hemi transposition. *Pediatr Transplant* 2004; 8(4): 416-9.
44. Vincent C, Pomier-Layrargues G, Dagenais M et al. Cure of gastric antral vascular ectasia by liver transplantation despite persistent portal hypertension: a clue for pathogenesis. *Liver Transpl* 2002; 8(8): 717-20.
45. Wang C, Zhang T, Song S, et al. Liver transplant with portocaval hemitransposition: blood supply with only hepatic artery is possible? *Transplant Proc* 2005; 37(5): 2163-5.
46. Weeks SM, Alexander JR, Sandhu J, et al. Mechanic and pharmacologic treatment of a saddle embolus to the portal vein after liver transplantation and portacaval hemitransposition. *AJR Am J Roentgenol* 2000; 175(2): 537-9.
47. Yan ML, Zeng Y, Li B, et al. Postoperative complications after liver transplantation with cavoportal hemitransposition. *Hepatobiliary Pancreat Dis Int* 2008; 7(3): 322-4.
48. Paskonis M, Jurgaitis J, Mehrabi A, et al. Surgical strategies for liver transplantation in the case of portal vein thrombosis—current role of cavoportal hemitransposition and renportal anastomosis. *Clin Transplant* 2006; 20(5): 551-62.
49. Klupp J, Kohler S, Pascher A, Neuhaus P. Liver transplantation as ultimate tool to treat portal hypertension. *Dig Dis* 2005; 23(1): 65-71.
50. Loinaz C, Gomez R, Jimenez C, et al. Liver transplantation in patients with portal thrombosis: results in 76 patients. *Transplant Proc* 2002; 34(1): 248-9.
51. Wang ZF, Liu C. Liver retransplantation: indications and outcomes. *Hepatobiliary Pancreat Dis Int* 2004; 3(2):75-8.
52. Sauvanet A, Panis Y, Valla D, et al. Budd-Chiari syndrome with extensive portal thrombosis: treatment with Senning's procedure. *Hepato-gastroenterology* 1994; 41(2): 174-6.
53. Hannoun L, Hugué C, Delva E, et al. Results of portal shunts for intractable ascites in patients with cirrhosis. 57 cases. *Chirurgie* 1988; 114(6): 497-501.

54. Huguet C, Hannoun L, Nordlinger B, et al. Selective distal spleno-renal shunt. A report of 14 patients (author's transl). *Nouv Presse Med* 1979; 8(47): 3881-4.
55. Watanabe H, Shinzawa H, Saito T, et al. Successful emergency treatment with a transjugular intrahepatic portosystemic shunt for life-threatening Budd-Chiari syndrome with portal thrombotic obstruction. *Hepatogastroenterology* 2000; 47(33): 839-41.
56. Stange B, Glanemann M, Nussler NC, et al. Indication, technique, and outcome of portal vein arterialization in orthotopic liver transplantation. *Transplant Proc* 2001; 33(1-2): 1414-5.
57. Azoulay D, Adam R, Castaing D, et al. Liver transplantation with cavoportal or renoportal anastomosis: a solution in cases of diffuse portal thrombosis. *Gastroenterol Clin Biol* 2002; 26(4): 325-30.
58. Eck NV. K voprosu o perevyazkie vorotnois veni: Predvaritelnoye soobschjentye. *Voen Med J* 1877; 130: 1-2.
59. Starzl TE, Porter KA, Francavilla A. The Eck fistula in animals and humans. *Curr Probl Surg* 1983; 20(11): 687-752.
60. Hahn M, Massen O, Nencki M, Pawlow J. Die Eck'sche Fistel zwischen der unteren Hohlvene und der Pfortader und ihre Folgen für den Organismus. *Arch Exp Pathol Pharmacol* 1893; 32: 161-210.
61. Child CGI, Barr D, Holswade GR, Harrison CS. Liver regeneration following portacaval transposition in dogs. *Ann Surg* 1953; 138(4): 600-8.
62. Riddell AG, Davies RP, Clark AD. Portacaval transposition in the treatment of glycogen-storage disease. *Lancet* 1966; 2(7474): 1146-8.
63. Meyer WH, Jr., Starzl TE. The reverse portacaval shunt. *Surgery* 1959; 45: 660-.
64. Silen W, Mawdsley DL, Weirich WL, Harper HA. Studies of hepatic function in dogs with Eck fistula or portacaval transposition. *AMA Arch Surg* 1957; 74(6): 964-70.
65. Starzl TE, Putnam CW, Porter KA, et al. Portal diversion for the treatment of glycogen storage disease in humans. *Ann Surg* 1973; 178(4): 525-39.
66. Jamieson NV. Changing perspectives in portal vein thrombosis and liver transplantation. *Transplantation* 2000; 69(9): 1772-4.
67. Eguchi S, Yanaga K, Sugiyama N, et al. Relationship between portal venous flow and liver regeneration in patients after living donor right-lobe liver transplantation. *Liver Transpl* 2003; 9(6): 547-51.
68. Garcia-Valdecasas JC, Fuster J, Charco R, et al. Changes in portal vein flow after adult living-donor liver transplantation: does it influence postoperative liver function? *Liver Transpl* 2003; 9(6): 564-9.
69. Lo CM, Liu CL, Fan ST. Portal hyperperfusion injury as the cause of primary nonfunction in a small-for-size liver graft-successful treatment with splenic artery ligation. *Liver Transpl* 2003; 9(6): 626-8.
70. Sugimoto H, Kaneko T, Hirota M, et al. Critical progressive small-graft injury caused by intrasinusoidal pressure elevation following living donor liver transplantation. *Transplant Proc* 2004; 36(9): 2750-6.
71. Henderson JM, Gilmore GT, Mackay GJ, et al. Hemodynamics during liver transplantation: the interactions between cardiac output and portal venous and hepatic arterial flows. *Hepatology* 1992; 16(3): 715-8.
72. Paulsen AW, Klintmalm GB. Direct measurement of hepatic blood flow in native and transplanted organs, with accompanying systemic hemodynamics. *Hepatology* 1992; 16(1): 100-11.
73. Starzl TE, Putnam CW, Porter KA, Benichou J. Portacaval shunt for glycogen storage disease and hyperlipidaemia. *Ciba Found Symp* 1977; (55): 311-25.
74. Dahan H, Arrive L, Monnier-Cholley L, et al. Cavoportal collateral pathways in vena cava obstruction: imaging features. *AJR Am J Roentgenol* 1998; 171(5): 1405-11.
75. Abrams HL. The vertebral and azygos venous systems, and some variations in systemic venous return. *Radiology* 1957; 69(4): 508-26.
76. Monkhouse WS, Khalique A. The adrenal and renal veins of man and their connections with azygos and lumbar veins. *J Anat* 1986; 146: 105-15.
77. Seib GA. Azygos System of Veins in American White and American Negroes, Including Observations on Inferior Caval Venous System. *Am J Phys Anthropol* 1934; 19: 39-163.
78. Settmacher U, Nussler NC, Glanemann M, et al. Venous complications after orthotopic liver transplantation. *Clin Transplant* 2000; 14(3): 235-41.
79. *Novel procedure: percutaneous, via TIPS, portal vein thrombectomy in patients with Budd-Chiari syndrome complicated by acute portal vein thrombosis*. Tel-Aviv, Israel.: 2005.
80. Leebeek FW, Lameris JS, van Buuren HR, et al. Budd-Chiari syndrome, portal vein and mesenteric vein thrombosis in a patient homozygous for factor V Leiden mutation treated by TIPS and thrombolysis. *Br J Haematol* 1998; 102(4): 929-31.
81. Mancuso A, Watkinson A, Tibballs J, et al. Budd-Chiari syndrome with portal, splenic, and superior mesenteric vein thrombosis treated with TIPS: who dares wins. *Gut* 2003; 52(3): 438.
82. Opitz T, Buchwald AB, Lorf T, et al. The transjugular intrahepatic portosystemic stent-shunt (TIPS) as rescue therapy for complete Budd-Chiari syndrome and portal vein thrombosis. *Z Gastroenterol* 2003; 41(5): 413-8.
83. Pfammatter T, Benoit C, Cathomas G, Blum U. Budd-Chiari syndrome with spleno-mesenteric-portal thrombosis: treatment with extended TIPS. *J Vasc Interv Radiol* 2000; 11(6): 781-4.
84. Haider HH, Froud T, Moon J, et al. Successful percutaneous pulse spray thrombolysis of extensive acute portocaval hemitransposition thrombosis. *Transpl Int* 2006; 19(11): 941-4.