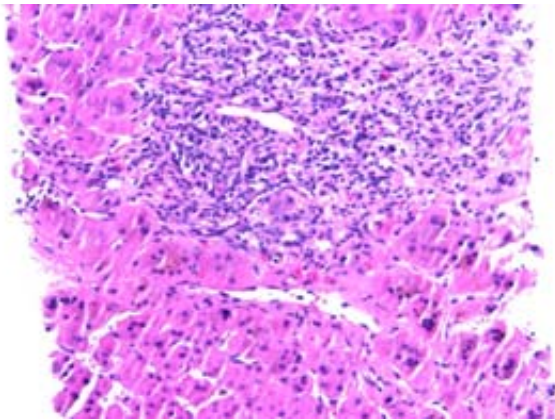


## Images in Hepatology

## Recurrent giant cell hepatitis in an 18 year old liver transplant patient

Justin A. Shah,<sup>1</sup> Urs P. Steinbrecher,<sup>1</sup> Siegfried R. Erb,<sup>1</sup> Susan P. L. Tha,<sup>2</sup> Yoshida EM<sup>1</sup>



### Description of photograph:

Liver biopsy showing scattered multinucleate hepatocyte giant cells. No obvious etiology seen on histology. Portal tracts are expanded, fibrotic, and inflamed, accompanied by mild lobular inflammation.

### Background:

Giant cell hepatitis (GCH) is a rare form of hepatitis that has a generally poor prognosis.<sup>1</sup> The disease often takes a progressive course, with the development of cirrhosis within months requiring transplantation or leading to death in a high percentage of cases.<sup>2</sup> Diagnosis of GCH is made when hepatocellular multinucleate giant cells are found on liver biopsy.<sup>2</sup>

The etiology is unclear but is thought to include viruses including typical viral hepatitis, cytomegalovirus,

rubella, parvovirus, paramyxovirus, human herpes virus, and human papilloma virus. Other postulated etiologies include autoimmune disorders, drug toxicities, alpha 1-antitrypsin deficiency, and haemosiderosis.<sup>1,2</sup>

Therapy for GCH is controversial although successful treatment with ribavirin and/or interferon has been described in both non-transplant and transplant patients.<sup>1</sup>

### Case:

18 year old man who underwent liver transplantation at the age of 10 months due to GCH. He was well for several years after transplantation with a maintenance regimen of prednisone, azathioprine, and cyclosporine. At age 18, he developed an elevation of his liver enzymes: ALT 228 IU/L, bilirubin 40 mmol/L. Workup was negative and subsequent liver biopsy showed recurrent GCH with no obvious etiology. No treatment was initiated and his liver enzyme abnormalities improved but did not return to normal. Ribavirin 1200 mg daily was subsequently started and his ALT normalized after four months of therapy. As of last follow-up, he continues on ribavirin and his liver function remains largely intact.

### References

1. Liu JJ, Piper JK, Glickman JN, Francis A, Farraye FA. Successful treatment of giant cell hepatitis with Rebetrone (interferon/ribavirin) *Am J Gastroenterol* 200;98:223-4
2. Kuntzen T, Friedrichs N, Fischer HP, Eis-Hubinger AM, Sauerbruch T, Spengler U. Postinfantile giant cell hepatitis with autoimmune features following a human herpesvirus 6-induced adverse drug reaction. *Eur J Gastroenterol Hepatol*. 2005;17:1131-4.

<sup>1</sup> Division of Gastroenterology and

<sup>2</sup> Department of Pathology, University of British Columbia, Vancouver, Canada.

Address for correspondence:  
Dr. Eric M. Yoshida  
Division of Gastroenterology  
Gordon and Leslie Diamond Health Care Centre  
5153- 2775 Laurel Street  
Vancouver, BC  
V5Z 1M9, CANADA  
E-mail: Eric.Yoshida@vch.ca