



## Case Report

## Subcapsular liver hematoma after endoscopic retrograde cholangiopancreatography in a liver transplant recipient

Andrés Cárdenas;<sup>1</sup> Gonzalo Crespo;<sup>1</sup> Domingo Balderramo;<sup>1</sup> Josep M. Bordas;<sup>1</sup> Oriol Sendino;<sup>1</sup> Josep Llach<sup>1</sup>

### Abstract

**Endoscopic Retrograde Cholangiopancreatography (ERCP) is commonly performed in patients after liver transplantation. The most common indications for ERCP include treatment of bile leaks and anastomotic and nonanastomotic biliary strictures. In this report we describe an unusual complication of ERCP in a liver transplant recipient with a bile leak two months after orthotopic liver transplantation (OLT). After confirming a bile leak, a hydrophilic guide wire was placed in the intrahepatic duct, an endoscopic sphincterotomy was performed, and a biliary plastic stent was successfully placed over the wire across the bile leak. Within the following 24 hours the patient developed a sharp right-sided upper quadrant pain and a drop in his hemoglobin level. An abdominal CT scan demonstrated a subcapsular hepatic hematoma that was successfully managed conservatively.**

**Key words:** Endoscopic retrograde cholangiopancreatography (ERCP), subcapsular hepatic hematoma, liver transplantation, bile leak, biliary complications.

### Case

A 54-year-old man with a past history of decompensated cirrhosis secondary to hepatitis C and alcohol abuse

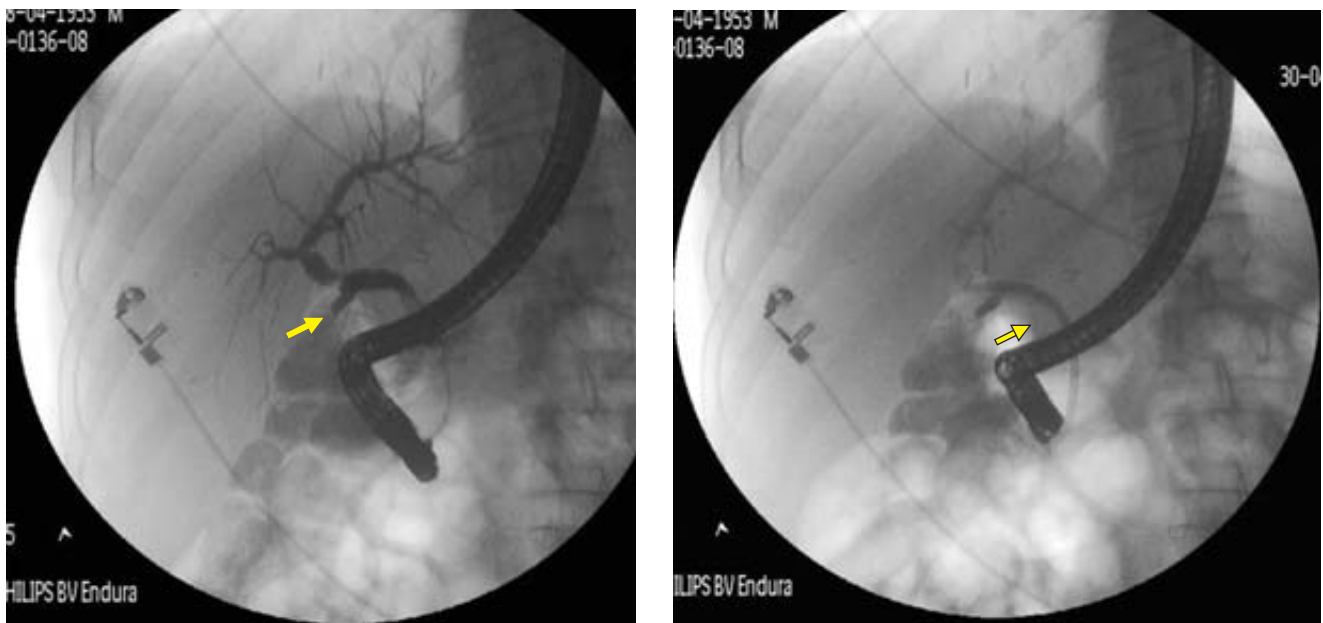
underwent successful OLT on February 2008. The surgical procedure was uneventful and biliary reconstruction was performed with duct-to-duct choledocho-choledochostomy and T-tube placement. The patient was discharged home after 10 days on tacrolimus, sirolimus and prednisone. He was closely followed in the Liver Transplant clinic and was subsequently electively admitted for removal of the T-Tube 10 weeks post-liver transplantation. A T-tube cholangiogram prior to its removal showed a normal biliary tree with good drainage of contrast into the duodenum. One hour after its removal, the patient complained of sharp pain in the right upper quadrant and mid-abdomen. On exam the patient was in significant distress and developed abdominal guarding; however vital signs were normal. An abdominal ultrasound and CT scan showed a moderate amount moderate amount of free intraabdominal fluid. Blood work revealed a hemoglobin level of 12 g/dL, white cell count  $5.8 \times 10^9/L$ , serum C-reactive protein 6.7 mg/dL (normal < 0.8 mg/L), platelet count  $66 \times 10^9/L$ , AST 31 U/L, ALT 82 U/L, serum bilirubin 1.7 mg/dL, alkaline phosphatase 202 U/L, albumin 3.2 g/dL, prothrombin time 12 seconds, blood urea nitrogen 13 mg/dL and serum creatinine 0.8 mg/dL.

An ERCP was performed and a cholangiogram revealed a bile leak at the mid-common bile duct in the area where the T-Tube was previously located (*Figure 1*). A 0.035-inch diameter, 450-cm length straight-tip guidewire (Jagwire, Boston Scientific, Newton, USA) was advanced into the left biliary tree and an endoscopic biliary sphincterotomy performed over the guidewire; afterwards a plastic 10 French x 7cm biliary stent was successfully placed across the bile leak (*Figure 1*).

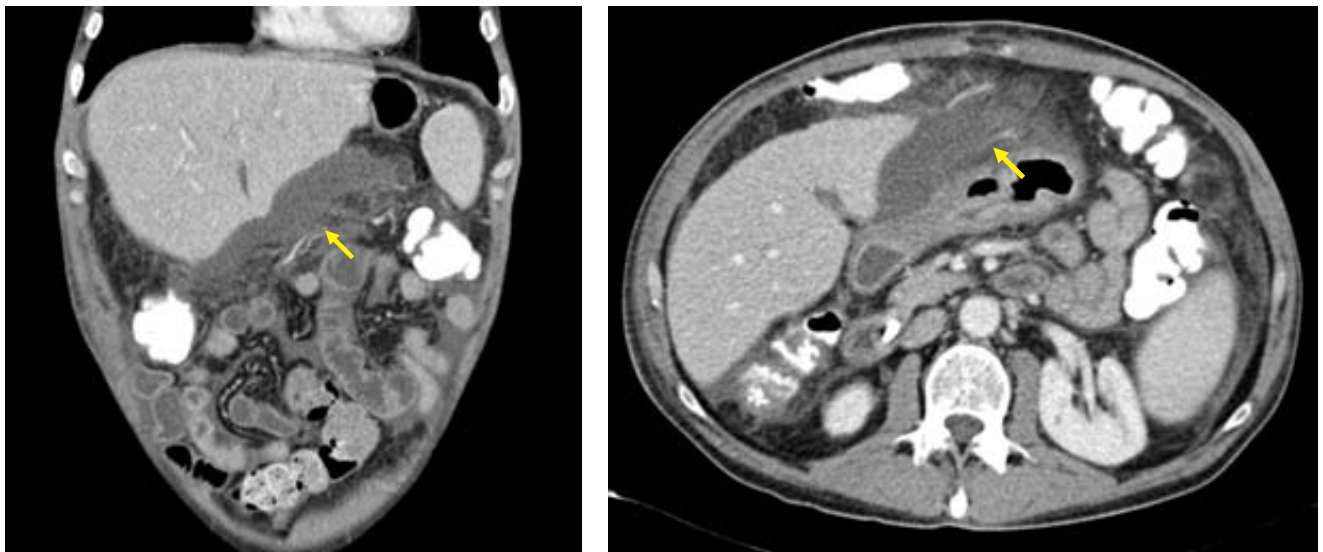
Over the following 24 hours the patient developed mild mid-abdominal pain without nausea, vomiting, or fever. The abdomen was soft, non-tender, non-distended with normal bowel sounds. His hemoglobin level dropped to 8.8 mg/dL, serum C-reactive protein rose to 27 mg/dl (normal <1 mg/L), and amylase and lipase levels were normal. White blood cell and platelet count, prothrombin time, liver tests and renal function remained stable. An abdominal CT scan showed a 9 x 2 cm subcapsular liver hematoma on the surface of the left lobe of liver (*Figure 2*).

<sup>1</sup> GI/Endoscopy Unit, Institut de Malalties Digestives i Metabòliques, Hospital Clínic and University of Barcelona, Institut d'Investigacions Biomèdiques August Pi-Sunyer (IDIBAPS), Ciber de Enfermedades Hepáticas y Digestivas (CIBERHED), Barcelona, Spain

Address for correspondence:  
Andrés Cárdenas, MD, MMSc  
Institut de Malalties Digestives i Metabòliques  
University of Barcelona  
Hospital Clínic - Villarroel 170  
08036 Barcelona, Spain  
Tel: (+34) 93 227 5418  
Fax: (+34) 93 227 9850  
E-mail: acardena@clinic.ub.es



**Figure 1.** A/Bile leak in the mid-common bile duct B/Plastic biliary stent successfully placed across the bile leak.



**Figure 2.** Abdominal CT scan showing a 9 x 2 cm hematoma in the subcapsular area left lobe of the liver. A/Coronal view, B/Axial view.

The patient was treated conservatively with analgesia, intravenous antibiotics, and intravenous fluids. He did not require a blood transfusion. A follow-up ultrasound 4 weeks later did not reveal a hematoma. A follow up ERCP was performed for removal of the plastic stent 6 weeks later showing resolution of the bile leak.

## Discussion

The estimated incidence of biliary complications after liver transplantation ranges between 10 and 25 percent in various reports, although rates seem to be decreasing in re-

cent years.<sup>1</sup> The majority of complications include biliary tract strictures, bile leaks, and bile duct stones. Most can be managed successfully with ERCP. ERCP is the treatment of choice for patients with bile leaks. A biliary sphincterotomy and placement of a plastic stent in the common bile duct is successful in treating 90 percent of bile leaks.<sup>1,2</sup>

This case describes an uncommon complication of ERCP that may occur in patients that undergo therapeutic ERCP with guidewire placement. Few cases of subcapsular hepatic hematoma after ERCP have been reported.<sup>3-11</sup> However, to our knowledge this is the first case de-

scribed in a liver transplant recipient. In this case, like in others, the hematoma likely developed as a result of guidewire trauma during the ERCP as there were no other procedures or trauma after the ERCP to explain the hematoma. Other plausible contributing factors in this particular case might include the presence of a low platelet count before the procedure and his immunosuppression. In the reported literature management of hepatic hematoma after ERCP has varied from conservative therapy to percutaneous drainage or arterial embolization. In one case the hematoma got infected with *Citrobacter freundii* requiring CT drainage and antibiotics.<sup>3</sup> In another case of a patient with obstructive jaundice due to metastasis, an ERCP for stent placement caused a very large hematoma that required selective embolization of the hepatic artery.<sup>4</sup> In one case immediately following ERCP, the patient developed right upper abdominal pain and collapsed requiring intensive resuscitation; a CT scan revealed a large hematoma that required percutaneous drainage.<sup>5</sup> In the other reports the hematoma was managed conservatively with intravenous fluids, antibiotics, and analgesia without surgery.<sup>6-11</sup> In all the described cases the guidewire has been implicated as the cause of hematoma. Guidewire trauma can occur when the wire is advanced deep into the intrahepatic ducts causing rupture of small blood vessels in the hepatic parenchyma, thereby causing subcapsular hematoma formation. In cases of cholangitis or common bile duct obstruction, infection of the biliary tree can act as a nidus for infection and abscess formation. In this case there was no infection and the patient responded well with conservative management without requiring blood products or any other interventions.

The development of subcapsular hepatic hematoma may occur after therapeutic ERCP; however its occurrence seems to be rare. This is the first reported case of hepatic

hematoma after ERCP in a liver transplant recipient. Physicians taking care of liver transplant recipients should be aware of this complication as its timely diagnosis and management with analgesia, intravenous fluids and antibiotics in selected cases are of critical importance in order to avoid the need for surgical re-intervention.

## References

1. Londoño MC, Balderramo D, Cárdenas A. Management of biliary complications after orthotopic liver transplantation: The role of endoscopy. *World J Gastroenterol* 2008; 14: 493-7.
2. Morelli, J, Mulcahy, HE, Willner, IR, Baliga P, Chavin KD, Patel R, et al. Endoscopic treatment of post-liver transplantation biliary leaks with stent placement across the leak site. *Gastrointest Endosc* 2001; 54: 471.
3. Ortega Deballon P, Fernández Lobato R, García Septiem J, Nieves Vázquez MA, Martínez Santos C, Moreno Azcoita M. Liver hematoma following endoscopic retrograde cholangiopancreatography. *Surg Endosc* 2000; 14: 767.
4. Chi KD, Waxman I. Subcapsular hepatic hematoma after guide wire injury during endoscopic retrograde cholangiopancreatography: management and review. *Endoscopy* 2004; 36: 1019-1021.
5. Bhati CS, Inston N, Wigmore SJ. Subcapsular intrahepatic hematoma: an unusual complication of ERCP. *Endoscopy* 2007; 39 Suppl 1: E150.
6. Papachristou GI, Baron TH. Complication of therapeutic endoscopic retrograde cholangiopancreatography. *Gut* 2007; 56: 854-868.
7. Horn TL, Pena LR. Subcapsular hepatic hematoma after ERCP: case report and review. *Gastrointest Endosc* 2004; 59: 594-596.
8. Ertugrul I, Parlak E, Ibis M, Altıparmak E, Sa'maz N, Sahin B. An unusual complication of endoscopic retrograde cholangiopancreatography. *Dig Dis Sci* 2006; 51: 1167-1168.
9. Poon CM, Lee FY, Ko CW, Lai PB, Lau WY. A rare complication of intra-abdominal hematoma after ERCP. *Gastrointest Endosc* 2002; 56: 307.
10. Bhandarkar DS, Katara AN, Shah RS. Intrahepatic subcapsular hematoma complicating laparoscopic cholecystectomy. *Surg Endosc* 2004; 18: 868-70.
11. McArthur KS, Mills PR. Subcapsular hepatic hematoma after ERCP. *Gastrointest Endosc* 2008; 67: 379-80.