

Incisional intercostal hernia with prolaps of the liver

Marc-Alexander Ohlow,* Michael Hocke**

* Zentralklinik Bad Berka, Bad Berka, Germany. ** Klinikum Meiningen, Meiningen, Germany.

CASE

A 61-year-old obese woman (body-mass-index 44) presented to our clinic with a 4 year history of recurrent discomfort and pain at the lateral edge of a lumbar incision. On physical examination there were no specific findings beside of a diffuse tenderness at the lateral edge of the lumbar incision. The patient had a history of right-sided nephrectomy five years ago due to an angiomyolipoma. An ultrasound and a computed tomography image revealed the liver protruding through a 5 x 7 cm hernial orifice between the eleventh and twelfth rib (Figure 1). Hernia repair using a low weight and large pored polypropylene compound mesh (Ultrapro) in combination with approximation of the ribs with absorbable single sutures (polyglactin, Vicryl) was performed. The postoperative course was uneventful, at 6 months follow-up the patient had no complaints and no evidence for hernia recurrence was found.

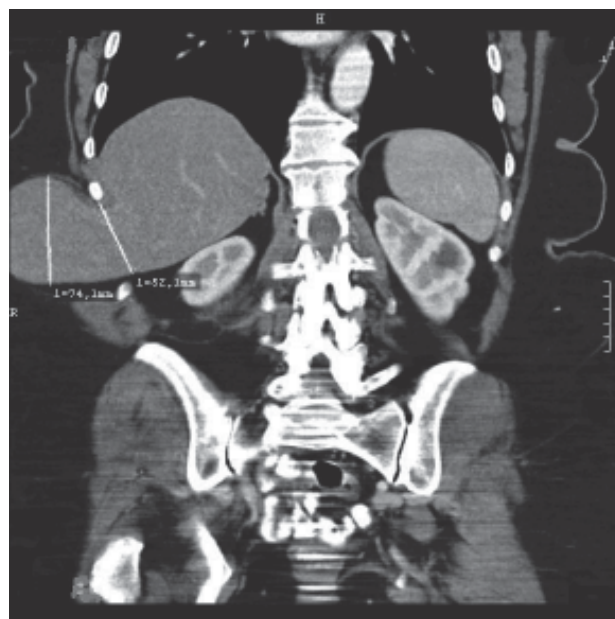


Figure 1. Computed tomography of the abdomen and pelvis.