

Massive avascular malformations causing life threatening portal hypertension

Aman Arya,* Nirmal Kakani,** Nabil Hussain,** Natasha Chandok*

* Department of Medicine. ** Department of Radiology.
Western University, London, Ontario, Canada.

ABSTRACT

We present an unusual case of extensive avascular malformations (AVMs) causing non-cirrhotic portal hypertension. This phenomenon, though previously described, is a rare clinical entity which, in the setting of life threatening portal hypertension, may require vascular decompression either by surgery or a transjugular intrahepatic portosystemic shunt.

Key words. Avascular malformation. Portal hypertension. Ascites. Variceal hemorrhage.

CASE REPORT

A 44-year-old woman presented with a 1 month history of progressive abdominal girth and profound intermittent rectal bleeding. Investigations were significant for normal coagulation, serum albumin 35 g/L, total bilirubin 19 mmol/L, normal aspartate and alanine amino-transferases, alkaline phosphatase 256 U/L, platelet count 92×10^9 cells/mL, normal renal function, serum to ascites albumin gradient of 13 g/L, negative serology for schistosomiasis, normal echocardiogram and gastroscopy, and colonoscopy compatible with portal hypertensive colopathy. A full-body CT scan (and subsequent abdominal angiogram) revealed multiple massive arteriovenous malformations (AVMs) confined in the abdomen and pelvis, the largest measuring 5.3 by 7.1 cm (Figures 1A-1D). A hepatic venogram measured a portosystemic gradient of 27 mmHg, and transvenous liver biopsy was normal.

AVMs are an uncommon cause of non-cirrhotic portal hypertension, although the phenomenon has been best described in the Asian literature.¹⁻³ Mana-

gement may involve symptomatic treatment, including diuretics, paracentesis and consideration for transjugular intrahepatic portosystemic shunt (as in the case of our patient following a near fatal lower gastrointestinal bleed) or surgical decompression. In cases where vascular decompression cannot be performed due to the extensive nature of the AVMs, consideration for multi-organ transplantation should be made as a treatment for life-threatening complications of portal hypertension.

Figures 1A-1D: Arterial and portal phase images (A, B C) demonstrate multiple aneurysmal arterioportal malformations involving the splenic and superior mesenteric veins, with a partial thrombus in the dominant aneurysmal vessel at the junction of the superior mesenteric vein and splenic vein. The coronal and sagittal (B and C) images show multiple arterio-portal malformations of varying sizes throughout the bowl mesentery. The main portal vein seen on the coronal image is of normal calibre. The intense contrast enhancement of these aneurysmal AVMs in the arterial phase demonstrates the abnormal high flow arterio-portal shunting causing increased pressure and portal hypertension.

CONFLICT OF INTEREST

None for all authors.

Written informed consent for publication of the materials presented herein was obtained from the patient described in this case, and this submission was approved by the Institutional Review Board of Western University.

Correspondence and reprint request: Natasha Chandok, MD, MPH.
Assistant Professor of Medicine, Multi-Organ Transplant Program, Western University.
London, Ontario, Canada
Fax: 519-663-3858
E-mail: nchandok@uwo.ca

Manuscript received: April 18, 2012.
Manuscript accepted: May 05, 2012.

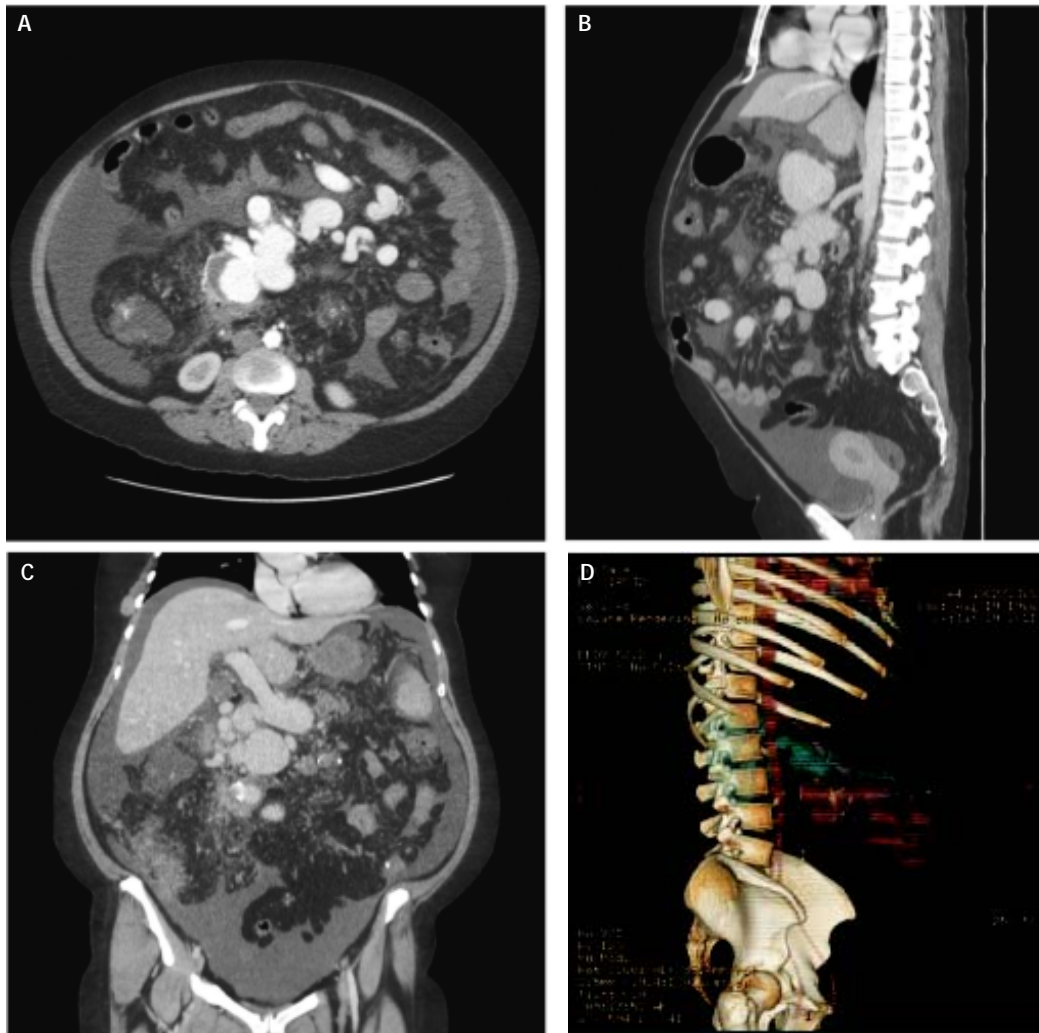


Figure 1. A. Axial phase. B. Sagittal, PV phase. C. Coronal, PV phase. D. 3D reformat.

REFERENCES

1. Loria LE, Tsuchiya R, Harada N, Tomioka T, Izawa K, Ura K, Ozeki K, et al. Congenital mesenteric arterio-portal fistula: Report of a case. *Jpn J Surg* 1988; 18: 351-8.
2. Mugica F, Merino JL, Merino S, Huarte I, Goenaga MA, Egana JM, Munagorri A. Arteriovenous malformation of the superior mesenteric artery with secondary portal hypertension. *Gastroenterol Hepatol* 1995; 18: 420-4.
3. Tsumura A, Tamori A, Nakamura S, Takeda T, Nishiguchi S, Shiomi S, Seki S, et al. A case of mesenteric arteriovenous malformation with portal hypertension. *Nihon Shokakibyo Gakkai Zasshi* 2002; 99: 489-92.