

## Pulmonary complications of treatment with pegylated interferon for hepatitis C infection-Two case reports

Vinod S. Hegade,\* Ruchit Sood,\* Dinesh Saralaya,\*\* Sulleman Moreea\*\*\*

\*Specialist Registrar in Gastroenterology, Yorkshire and the Humber Deanery, United Kingdom.

\*\*Consultant Respiratory Physician, Bradford Teaching Hospitals NHS Foundation Trust, Bradford, United Kingdom.

\*\*\*Consultant Hepatologist, Bradford Teaching Hospitals NHS Foundation Trust, Bradford, United Kingdom.

### ABSTRACT

Pegylated interferon (Peg-IFN) in combination with ribavirin is the standard of care in the treatment of chronic hepatitis C (HCV). Peg-IFN is known to have a number of side effects but severe respiratory complications are uncommon. We report two cases, one of Peg-IFN induced interstitial pneumonitis (IP) and the other of bronchiolitis obliterans organising pneumonia (BOOP) in patients with chronic hepatitis C infection. In general, respiratory complications of Peg-IFN are mild and resolve with withdrawal of Peg-IFN. However, as illustrated in our first case fatal interstitial pneumonitis can occur. We present a review of the available literature on Peg-IFN induced lung toxicity. In conclusion, pulmonary toxicity with Peg-IFN is rare but fatality can occur. We highlight the importance of maintaining a high index of suspicion for early diagnosis and prompt treatment, which includes withdrawal of Peg-IFN and consideration of corticosteroid treatment.

**Key words.** Interstitial pneumonitis. Bronchiolitis obliterans. HCV.

### INTRODUCTION

Approximately 200 million people worldwide are infected with the hepatitis C virus (HCV) with chronic infection in up to 85 percent, resulting in significant morbidity and mortality. Interferon based regimes have been the mainstay treatment of HCV for many years with pegylated interferon alpha (Peg IFN- $\alpha$ ) replacing standard interferon in recent times. Pulmonary side effects of standard interferon are well known but rarely documented in the case of Peg IFN- $\alpha$ .

We present two cases of patients with chronic HCV commenced on anti-viral therapy for HCV who developed pulmonary toxicity. In case 1, the patient developed severe interstitial pneumonitis with subsequent acute respiratory distress syndrome

(ARDS), resulting in death and in case 2 the patient presented with bronchiolitis obliterans organising pneumonia that responded to treatment.

### CASE REPORTS

#### Case 1

A 45-year-old Caucasian male was referred to the outpatient hepatology clinic for management of HCV genotype 1. He had a smoking history of 25 pack years and was thought to have acquired HCV through previous intravenous drug use. Clinical examination was unremarkable with no stigmata of chronic liver disease. Biochemical investigations showed normal liver function tests (LFT), and HCV PCR viral load of  $4.8 \times 10^2$  IU/mL [Roche COBAS® TaqMan® HCV Test v2.0]. Liver biopsy revealed Ishak stage 3 fibrosis. He was initiated on combination treatment of once weekly subcutaneous injection of Peg IFN- $\alpha 2b$  1.5  $\mu$ g/kg [Viraferon Peg®, Schering-Plough] and twice-daily oral ribavirin [Rebetol®, Schering-Plough]. He was monitored on a weekly basis in the specialist nurse led clinic. On the 9th week of treatment, he presented to the emergency department with sudden onset severe dysp-

**Correspondence and reprint request:** Vinod S. Hegade M.D. MRCP  
Department of Hepatology, Bradford Royal Infirmary, Bradford Teaching Hospitals NHS Foundation Trust  
Duckworth Lane, Bradford BD9 6TB, United Kingdom  
Phone: 0044-1274-364463. Fax: 0044-1274-364363  
E-mail: vinodhegade@yahoo.com

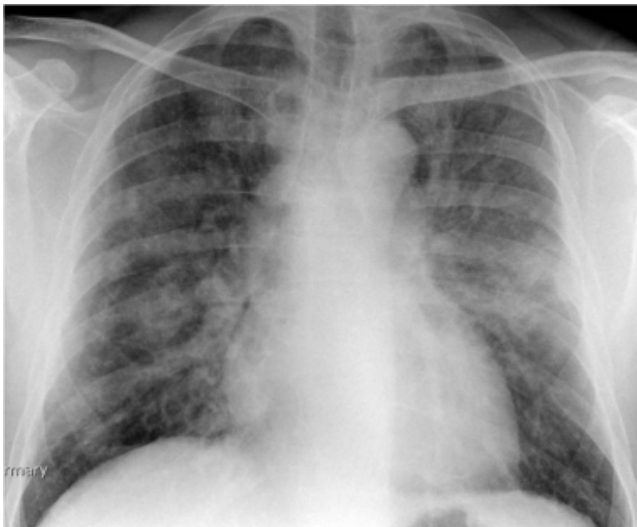*Manuscript received: June 23, 2012.  
Manuscript accepted: August 17, 2012.*

noea, cough and fever. Clinical and biochemical investigations showed that he was in acute type 2 respiratory failure, respiratory acidosis and hemodynamic instability. He was intubated, ventilated and transferred to the intensive care unit for cardio-respiratory support. Chest X ray (Figure 1) and a high resolution computed tomography (HRCT) scan (Figure 2) showed features of diffuse extensive bilateral ground glass opacification suggestive of interstitial pneumonitis. Peg IFN- $\alpha$  and ribavirin were discontinued and he was treated with intravenous hydrocortisone. A battery of investigations was negative including a septic screen (blood, urine and sputum culture), urinary legionella antigen, PCR of broncho-alveolar lavage for respiratory

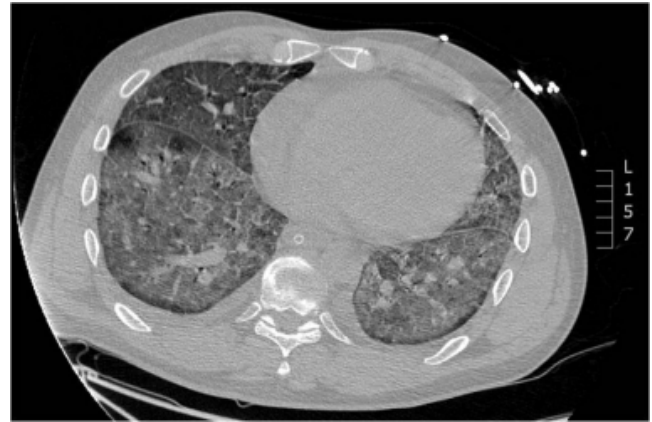
viruses and serum mycoplasma immunoglobulin M antibody test. The patient continued to deteriorate and developed multisystem failure and died on the 16th day of hospitalisation. A *post mortem* examination concluded that the patient died from severe bilateral interstitial pneumonitis caused by Peg IFN- $\alpha$ 2b, resulting in ARDS and subsequent multi-organ failure.

### Case 2

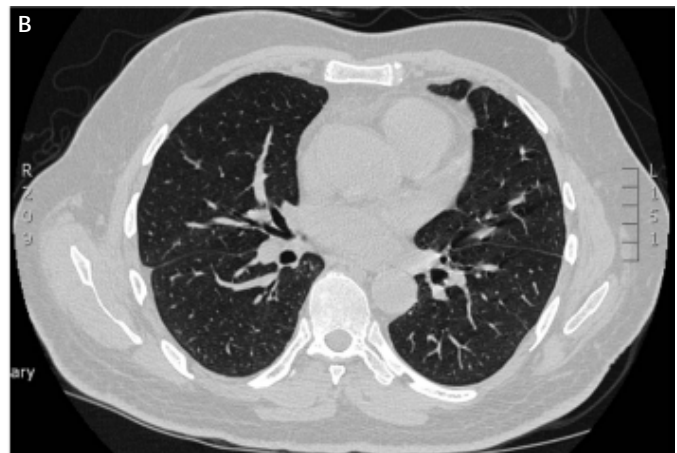
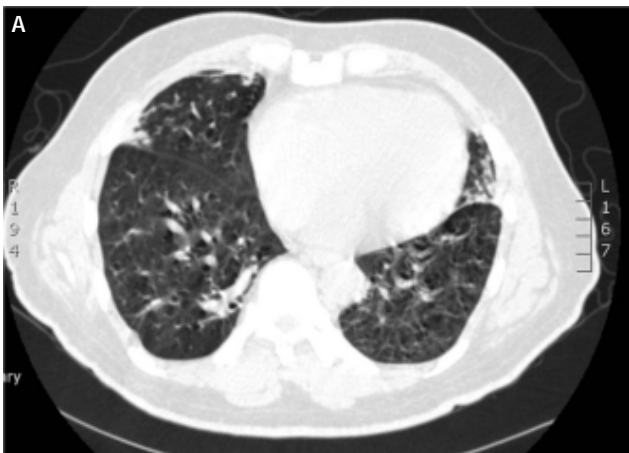
A 62-year-old Asian man was seen in the outpatient hepatology clinic for co-infection with chronic hepatitis B virus (HBV) and HCV genotype 3. There was no other significant medical history. Biochemical and viral studies showed ALT 105 iu/L ( $< 40$  iu/L), HBV DNA PCR  $< 20$  IU/mL [Roche COBAS®



**Figure 1.** Case 1. Chest X ray showing diffuse bilateral lung opacities.



**Figure 2.** Case 1. High resolution computed tomography scan showing diffuse extensive ground glass opacification throughout the lungs suggestive of bilateral interstitial pneumonitis.



**Figure 3.** Case 2. **A.** HRCT scan showing bronchial wall thickening and mosaic pattern of attenuation suggestive of bronchiolitis obliterans. **B.** Follow up HRCT scan one year later showing complete resolution of the abnormalities.

TaqMan® HBV Test v2.0] and HCV PCR of  $3.1 \times 10^6$  IU/mL. Percutaneous liver biopsy revealed Ishak stage 6 fibrosis (cirrhosis). He was initiated on combination treatment with once weekly subcutaneous injection of Peg IFN- $\alpha$ 2a 180  $\mu$ g/week [Pegasys®, Roche] and twice-daily oral ribavirin [Copegus®, Roche]. He tolerated the treatment well and developed only minimal side effects of headache and lethargy.

During the 15th week of his treatment, he complained of gradual onset dry cough, wheeze and exertional dyspnoea and clinical examination confirmed the presence of bilateral rhonchi. A subsequent chest X-ray was unremarkable. Despite treatment with salbutamol inhalers for two weeks his symptoms persisted with increasing severity of dyspnoea. In view of his progressive symptoms, he underwent a HRCT scan (Figure 3A). Based on the typical features of bronchial wall thickening and mosaic pattern of attenuation seen on the HRCT images, a diagnosis of bronchiolitis obliterans organising pneumonia (BOOP) was established and treatment with oral corticosteroids, prednisolone 30 mg once daily, was commenced. Over the next few weeks, the patient's symptoms improved dramatically and a tapering dose of prednisolone was continued for a total of 20 weeks. He was able to complete the full 48 weeks of treatment with Peg IFN- $\alpha$  and ribavirin, and achieved sustained virological response (SVR). A repeat HRCT scan 1 year later confirmed complete resolution of the previously noted abnormalities (Figure 3B).

## DISCUSSION

Hepatitis C (HCV) is a significant health problem worldwide with the burden of the disease predicted to increase in the next two decades. In England alone, approximately 6,400 new patients with chronic HCV are diagnosed annually and approximately 2,900 patients are commenced on anti-HCV treatment.<sup>1</sup> With the availability of new generation protease inhibitors (PI), the number of patients qualifying for treatment is expected to increase. Growing number of patients are receiving either dual therapy (Peg-IFN plus ribavirin) or triple therapy (Peg-IFN plus ribavirin plus PI) and it is therefore imperative to be aware of the spectrum of possible complications.

Interferon is a naturally occurring glycoprotein that has antiproliferative, anti-inflammatory and immunomodulatory properties. Peg IFN- $\alpha$  has increased half-life compared to standard interferon,

which allows for once weekly administration. The combination of Peg IFN- $\alpha$  and ribavirin is the approved and well-accepted standard of care (SoC) for chronic hepatitis C.<sup>2</sup> Currently there are two Peg IFN- $\alpha$  molecules in use, Peg IFN- $\alpha$ 2a and Peg IFN- $\alpha$ 2b. The pharmacokinetics of these compounds differ but there is no conclusive evidence that one Peg IFN- $\alpha$  should be preferred to the other.<sup>2</sup> Sustained virological response (SVR), the current measure of successful therapy, is defined as an undetectable serum HCV RNA at 24 weeks after cessation of treatment. With the current SoC, SVR can be achieved in up to 80% of patients with genotype 2 & 3 HCV and up to 50 % in genotype 1 HCV. The most common side effects of Peg IFN- $\alpha$  are headache, nausea, influenza-like symptoms, gastrointestinal upset, lethargy, anorexia and neuropsychiatric problems. Rare and severe complications include cardiac arrhythmias, cardiomyopathy and pancreatitis.

Pulmonary toxicity, although well described in the literature with standard interferon appears rare with Peg IFN- $\alpha$ . The spectrum of pulmonary complications associated with Peg IFN- $\alpha$  includes interstitial pneumonitis (IP), bronchiolitis obliterans organising pneumonia (BOOP), sarcoidosis, pleural effusion, exacerbation of asthma and acute respiratory distress syndrome. The mechanism of interferon- $\alpha$  induced pulmonary toxicity has not been elucidated, although two possible mechanisms postulated include direct toxicity to the pulmonary organ and indirect toxicity via immunological pathways.<sup>3</sup>

The overall incidence of pulmonary complications with Peg IFN- $\alpha$  is < 1%.<sup>4</sup> Currently available information related to pulmonary complications with peg IFN therapy comes from case reports and the true incidences of IP and BOOP are not known. Though physicians treating HCV should be aware of these complications, it may be debatable whether patients should be consented for the possibility of pulmonary complications occurring at any stage of the HCV therapy. However, it is now our practice to inform our patients of these complications.

There are eleven reported cases in the literature of interstitial pneumonitis (IP) in association with Peg IFN.<sup>4-13</sup> Patients were treated with Peg IFN- $\alpha$ 2a in five cases<sup>4-8</sup> and Peg IFN- $\alpha$ 2b in six cases.<sup>9-13</sup> All five reported cases of Peg IFN- $\alpha$ 2a had favourable outcome following discontinuation of the drug with or without steroid therapy. Of the six reported cases of IP associated with Peg IFN- $\alpha$ 2b, despite discontinuation of the Peg IFN and steroid therapy, three had fatal outcomes, i.e. IP associated with mortality was exclusively seen with Peg IFN- $\alpha$ 2b.

**Table 1.** Characteristics of case reports of interstitial pneumonitis (IP) associated with pegylated interferon therapy alpha 2a (Peg IFN- $\alpha$ 2a) and alpha (Peg IFN- $\alpha$ 2b) for hepatitis C virus (HCV).

Reference	Age/Sex	Type of Peg-IFN	Duration of therapy (wk)	Management	Outcome
4	71/F	Peg IFN- $\alpha$ 2a	20	Stopped	Resolution
5	48/F	Peg IFN- $\alpha$ 2a	6	Stopped + corticosteroids	Resolution
6	58/F	Peg IFN- $\alpha$ 2a	12	Stopped	Resolution
7	39/F	Peg IFN- $\alpha$ 2a	36	Stopped + corticosteroids	Resolution
8	68/M	Peg IFN- $\alpha$ 2a	36	Stopped + corticosteroids	Resolution
6	58/F	Peg IFN-2b	12	Stopped + corticosteroids	Resolution
9	51/M	Peg IFN-2b	4	Stopped + corticosteroids	Resolution
10	47/F	Peg IFN-2b	10	Stopped + corticosteroids	Resolution
11	49/M	Peg IFN-2b	2	Stopped + corticosteroids	Death
12	51/M	Peg IFN-2b	5	Stopped + corticosteroids	Death
13	43/F	Peg IFN-2b	48	Stopped + corticosteroids	Death

Table 1 summarises the characteristics of the reported cases of IP in association with Peg IFN. In general, IP tends to develop early on in the treatment cycle, usually between week 2 and week 16 treatment.<sup>8</sup> The mean treatment time with Peg IFN prior to the diagnosis of IP was less than 12 weeks in 73% cases.<sup>14</sup> Exceptionally it can occur later in the course of the treatment. Common presenting symptoms of IP are dyspnoea, dry cough and fever; less common symptoms include fatigue, arthralgia, myalgia and anorexia.<sup>14</sup> HRCT is the most important non-invasive tool for in diagnosis of IP with ground glass and reticular opacities as the most common radiographic features.<sup>15</sup> Treatment strategy includes discontinuation of Peg IFN- $\alpha$  with or without corticosteroid therapy. There are currently no guidelines recommending dosage and length of corticosteroid therapy.

Bronchiolitis obliterans organising pneumonia (BOOP) caused by Peg IFN- $\alpha$  appears to be even rarer with only two previously documented cases.<sup>5,16</sup> In these cases, infiltrates resolved with discontinuation of Peg IFN- $\alpha$  and corticosteroids treatment. Features of BOOP on HRCT scans are expiratory air trapping, mosaic pattern of attenuation and bronchial wall thickening.<sup>17</sup>

Interstitial lung diseases have also been reported with Albinterferon- $\alpha$  2b (albIFN; Zalbin/Joulferon, Human Genome Sciences, Rockville, MD/Novartis, Basel, Switzerland), a novel, longer acting interferon formulation. AlbIFN had held promise with safety and efficacy in phase II trials. However, in phase III trials, increased pulmonary adverse events were seen with 1,200  $\mu$ g of albIFN.<sup>18,19</sup> The pulmonary complications associated with the higher doses of albIFN, including two deaths from interstitial lung disease and bacterial pneumonia<sup>19</sup> caused sig-

nificant concerns to the drug regulating agencies in the US and EU, resulting in discontinuation of the development of albIFN.<sup>20-22</sup>

In conclusion, pulmonary toxicity with pegylated interferon alpha is rare, but fatal pneumonitis can occur during the treatment of chronic hepatitis C. Mortality has been seen exclusively with Peg IFN- $\alpha$ 2b. Physicians involved in the treatment of hepatitis C should be aware of pulmonary complications and need to maintain a high index of suspicion in patients presenting with respiratory symptoms. Prompt withdrawal of the therapy is the mainstay of treatment but steroid treatment may be essential.

## ABBREVIATIONS

- **ARDS:** acute respiratory distress syndrome.
- **BOOP:** bronchiolitis obliterans organising pneumonia.
- **HBV:** hepatitis B virus.
- **HCV:** hepatitis C virus.
- **HRCT:** high resolution computed tomography.
- **LFT:** liver function tests.
- **PCR:** polymerase chain reaction.
- **Peg IFN- $\alpha$ :** pegylated interferon alpha.
- **SoC:** standard of care.
- **SVR:** sustained virological response.

## REFERENCES

1. Hepatitis C in the UK: 2011 report, Health Protection Agency, www.hpa.org.uk. Accessed on 04.04.2012.
2. European Association for the Study of the Liver. EASL Clinical Practice Guidelines: Management of hepatitis C virus infection. *J Hepatol* 2011; 55: 245-64.
3. Tilg H. New insights into the mechanisms of interferon alfa: an immunoregulatory and anti-inflammatory cytokine. *Gastroenterology* 1997; 112: 1017-21.



4. Midturi J, Sierra-Hoffman M, Hurley D, Winn R, Beissner R, Carpenter J. Spectrum of pulmonary toxicity associated with the use of interferon therapy for hepatitis C: case report and review of the literature. *Clin Infect Dis* 2004; 39: 1724-9.
5. Kumar KS, Russo MW, Borczuk AC, Brown M, Esposito SP, Lobritto SJ, Jacobson IM, et al. Significant pulmonary toxicity associated with interferon and ribavirin therapy for hepatitis C. *Am J Gastroenterol* 2002; 97: 2432-40.
6. Renou C, Germain S, Harafa A, Martin S, Larroque O, Muller P, Bertrand JJ, et al. Interstitial pneumonia recurrence during chronic hepatitis C treatment. *Am J Gastroenterol* 2005; 100: 1625-6.
7. Ji FP, Li ZX, Deng H, Xue HA, Liu Y, Li M. Clinical features of interstitial pneumonitis due to interferon alpha therapy for chronic hepatitis C. *Nan Fang Yi Ke Da Xue Xue Bao* 2009; 29: 667-70.
8. Atug O, Akin H, Alahdab YO, Ceyhan B, Tozun N, Ozdogan O. Interstitial pneumonitis associated with pegylated interferon-alpha 2a and ribavirin for chronic hepatitis C infection: a case report. *Cases J* 2009; 10: 6464.
9. Slavenburg S, Heijdra YF, Drenth JP. Pneumonitis as a consequence of (peg) interferon-ribavirin combination therapy for hepatitis C: a review of the literature. *Dig Dis Sci* 2010; 55: 579-85.
10. Chen YC, Lu SN, Lin MC. Interstitial pneumonitis after combination therapy with pegylated interferon alpha-2b and ribavirin for chronic hepatitis C. *Chang Gung Med J* 2007; 30: 92-7.
11. Abi-Nassif S, Mark EJ, Fogel RB, Hallisey RK Jr. Pegylated interferon and ribavirin-induced interstitial pneumonitis with ARDS. *Chest* 2003; 124: 406-10.
12. Fuhrmann V, Kramer L, Bauer E, Laferl H, Tucek G, Dekan G, Schenk P. Severe interstitial pneumonitis secondary to pegylated interferon alpha-2b and ribavirin treatment of hepatitis C infection. *Dig Dis Sci* 2004; 49: 1966-70.
13. Carrillo-Esper R, González-Avila D, Uribe-Ríos M, Méndez-Sánchez N. Interstitial pneumonitis associated with pegylated interferon alpha-2b therapy for chronic hepatitis C: case report. *Ann Hepatol* 2008; 7: 87-90.
14. Ji FP, Li ZX, Deng H, Xue HA, Liu Y, Li M. Diagnosis and management of interstitial pneumonitis associated with interferon therapy for chronic hepatitis C. *World J Gastroenterol* 2010; 16(35): 4394-9.
15. Hartman TE, Swensen SJ, Hansell DM, Colby TV, Myers JL, Tazelaar HD, Nicholson AG, et al. Nonspecific interstitial pneumonia: variable appearance at high-resolution chest CT. *Radiology* 2000; 217: 701-5.
16. Trullas Vila JC, Padilla López DR, Bisbe Company V, Soler Simón S, Cortés Hausmann P, Bisbe Company J. Organizing pneumonia associated with the use of pegylated interferon alfa. *Arch Bronconeumol* 2008; 44: 173-4.
17. Jensen SP, Lynch DA, Brown KK, Wenzel SE, Newell JD. High-resolution CT features of severe asthma and bronchiolitis obliterans. *Clin Radiol* 2002; 57: 1078-85.
18. Nelson DR, Benhamou Y, Chuang WL, Lawitz EJ, Rodriguez-Torres M, Flisiak R, Rasenack JW, et al. Albinterferon Alfa-2b was not inferior to pegylated interferon-a in a randomized trial of patients with chronic hepatitis C virus genotype 2 or 3. *Gastroenterology* 2010; 139(4): 1267-76.
19. Zeuzem S, Sulkowski MS, Lawitz EJ, Rustgi VK, Rodriguez-Torres M, Bacon BR, Grigorescu M, et al. Albinterferon alfa-2b was not inferior to pegylated interferon-á in a randomized trial of patients with chronic hepatitis C virus genotype 1. *Gastroenterology*.2010; 139(4): 1257-66.
20. Pockros PJ. Why do we need another interferon? *Gastroenterology* 2010; 139(4): 1084-6.
21. Human Genome Sciences announces preliminary feedback from FDA on Zalbin BLA for chronic hepatitis C [press release]. Rockville, MD: Human Genome Sciences, Inc.; June 14, 2010.
22. Human Genome Sciences announces withdrawal of European Marketing Authorization Application for Jouferon® Zalbin™ for the treatment of chronic hepatitis C [press release]. Rockville, MD: Human Genome Sciences, Inc; April 19, 2010.