

## Patients with hyponatremic cirrhosis have low-grade cerebral edema and poor quality-of-life

Motoh Iwasa,\* Ryosuke Sugimoto,\* Yoshiyuki Takei\*

\* Department of Gastroenterology and Hepatology, Mie University Graduate School of Medicine, Japan.

### TO THE EDITOR:

Recently, Wunsch, *et al.* reported that hyponatremia, psychometric hepatic encephalopathy (HE) score, critical flicker frequency and severity of liver disease affect health-related quality-of-life (HRQOL) in patients with cirrhosis.<sup>1</sup> In addition, Ahluwalia, *et al.* evaluated the contribution of hyponatremia to impairment HRQOL, cognitive dysfunction and brain magnetic resonance (MR) spectroscopy parameters in cirrhotic patients independently of HE.<sup>2</sup> They showed that cirrhotic patients with hyponatremia had worse HRQOL despite better cognition and the poor HRQOL was associated with decreased myoinositol. Based on these observations, they concluded that hyponatremia worsens HRQOL due to changes in brain osmolarity in subjects with hyponatremia compared to those without it.

HE has recently been suggested to represent low-grade cerebral edema in association with osmotic imbalance in astrocytes.<sup>3</sup> MR spectroscopy shows increases in glutamine derived from ammonia metabolism and decrease in myoinositol in cirrhotic patients.<sup>4</sup> Changes in osmolytes are suggestive of brain edema. Diffusion-weighted MR imaging allows assessment of intra- and extracellular water content of the brain. We previously measured apparent diffusion coefficient (ADC) in various regions of the brain of patients with cirrhosis and investigated the significance of ADC to assess low-grade HE.<sup>5</sup> We found that, the mean ADC is significantly increased in white matter of the frontal and parietal lobes in cirrhotic patients with minimal HE compared to

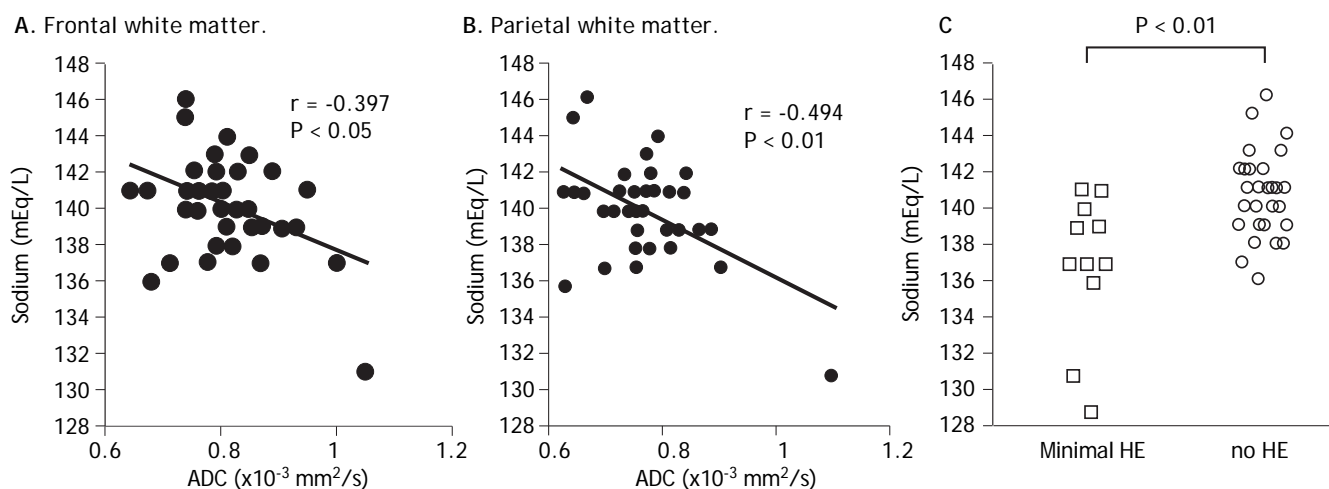
patients with no HE. Moreover, ADC was significantly correlated with the trail-making A and digit symbol tests.

Hyponatremia is a frequent complication in patients with advanced cirrhosis; it also affects the osmotic balance in brain cells, owing to a reduction in the osmolality of the extracellular fluid.<sup>6</sup> In hyponatremic encephalopathy, ADCs vary at different stages of the disease; ADC is decreased in the early stages and increase of ADC may represent vasogenic edema in late stages.<sup>7</sup> The significance of ADC abnormalities in the presence of HE and hyponatremia remains unclear; no study has been undertaken to clarify the relationship between serum sodium levels and brain ADC values in patients with cirrhosis. We measured ADC in the brain white matter of patients with cirrhosis and investigated the relationship of the levels of plasma ammonia and serum sodium with the brain ADC values and with the neuropsychological performance.

Forty patients with liver cirrhosis were recruited for the study. The cirrhosis grade was Child-Pugh A in 12 patients, B in 25 and C in three patients. MR imaging was performed using 1.5-T (Signa, CV/I; GE Medical Systems, Milwaukee, WI). Diffusion-weighted imaging was conducted using single-shot echo-planar imaging (TR/TE, 9999/70 ms; 1 acquisition; 20 sections of 5-mm thickness; 1-mm gap, the matrix of 128 x 128). Cognitive function was assessed using a combination of trail making A test and digit symbol test. Spearman or Pearson coefficients were used to compare quantitative variables. The Mann-Whitney U test was used to evaluate the statistical difference in clinical or laboratory variables. No patients showed signs of overt HE. Among the 40 cirrhotic patients, 10 showed impairment on neuropsychological tests and were therefore included in the minimal HE group. Higher ADC in the white matter was associated with hyperammonemia ( $P < 0.01$ ) and low serum sodium (Figure 1A; frontal,  $P < 0.05$ ; parietal,  $P < 0.01$ ). In addition, the mean serum sodium level was significantly decreased in cirrhotic patients with minimal HE

Correspondence and reprint request: Motoh Iwasa, M.D.  
Department of Gastroenterology and Hepatology, Mie University Graduate School of Medicine,  
Edobashi 2-174, Tsu, Mie, 514-8507, Japan  
Fax: +81-59-231-5223  
E-mail: motoh@clin.medic.mie-u.ac.jp

Manuscript received: January 22, 2014.  
Manuscript accepted: February 27, 2014.



**Figure 1.** Correlations between ADC for frontal (A) ( $P < 0.05$ ) and parietal-lobe (B) ( $P < 0.01$ ) white matter and serum sodium. Higher ADC in the white matter was associated with low serum sodium. Serum sodium levels in 40 cirrhotic patients with and without minimal HE (C). All patients underwent neuropsychological tests and were classified into patients with minimal HE ( $\square$ ) or no HE ( $\circ$ ). Serum sodium level was significantly decreased in cirrhotic patients with minimal HE compared to patients with no HE ( $P < 0.01$ ). ADC: apparent diffusion coefficient. HE: hepatic encephalopathy.

compared to patients with no HE (Figure 1B;  $137.0 \pm 3.8$  mEq/L vs.  $140.7 \pm 2.2$  mEq/L,  $P < 0.01$ ).

In summary, previous and our results support the hypothesis that hyponatremia is a second osmotic hit to astrocytes in the cirrhotic brain, that it aggravates intracellular edema and that the low-grade cerebral edema causes neuronal excitability and enhanced neurotransmission resulting in the clinical picture of HE in association with poor HR-QOL. This observation suggests that treatment of hyponatremia and low-grade cerebral edema may improve the clinical manifestations in patients with cirrhosis, and that ADC may constitute a reliable tool to assess low-grade edema.

### FINANCIAL SUPPORT

No external financial support was received for this work.

### CONFLICT OF INTEREST

The authors who have taken part in this study declared that they do not have anything to disclose

regarding funding or conflict of interest in relation to this manuscript.

### REFERENCES

1. Wunsch E, Naprawa G, Koziarska D, Milkiewicz M, Nowacki P, Milkiewicz P. Serum natremia affects health-related quality of life in patients with liver cirrhosis: a prospective, single centre study. *Ann Hepatol* 2013; 12: 448-55.
2. Ahluwalia V, Wade JB, Thacker L, Kraft KA, Sterling RK, Stravitz RT, Fuchs M, et al. Differential Impact of Hyponatremia and Hepatic Encephalopathy on Health-Related Quality of Life and Brain Metabolite Abnormalities in Cirrhosis. *J Hepatol* 2013; 59: 467-73.
3. Lemberg A, Fernández MA. Hepatic encephalopathy, ammonia, glutamate, glutamine and oxidative stress. *Ann Hepatol* 2009; 8: 95-102.
4. Sawara K, Kato A, Yoshioka Y, Suzuki K. Brain glutamine and glutamate levels in patients with liver cirrhosis: assessed by 3.0-T MRS. *Hepatology* 2004; 30: 18-23.
5. Sugimoto R, Iwasa M, Maeda M, Urawa N, Tanaka H, Fujita N, Kobayashi Y, et al. Value of the apparent diffusion coefficient for quantification of low-grade hepatic encephalopathy. *Am J Gastroenterol* 2008; 103: 1413-20.
6. Ginès P, Guevara M. Hyponatremia in cirrhosis: pathogenesis, clinical significance, and management. *Hepatology* 2008; 48: 1002-10.
7. Förster A, Nölte I, Wenz H, Al-Zghoul M, Kerl HU, Brockmann C, Brockmann MA, et al. Value of diffusion-weighted imaging in central pontine and extrapontine myelinolysis. *Neuroradiology* 2013; 55: 49-56.