

SPONTANEOUS PNEUMOMEDIASTINUM IN nCOVID-19 INFECTION: A CASE REPORT

KARLA-ELIZABETH LÓPEZ-LÓPEZ¹, DENISSE SÁNCHEZ-PRIETO² HERIBERTO TOSCA-CÓRDOVA³,
CRYSTELL-GUADALUPE GUZMÁN-PRIEGO⁴, GUADALUPE-DEL-CARMEN BAEZA-FLORES⁵,
JESÚS-ARTURO RUIZ-QUIÑONES⁶

Recibido para publicación: 05-11-2020 - Versión corregida: 23-12-2020 - Aprobado para publicación: 15-01-2021

López-López KE, Sánchez-Prieto D, Tosca-Córdova H, Guzmán-Priego CG, Baeza-Flores GC, Ruiz-Quiñones JA. **Spontaneous Pneumomediastinum in nCOVID-19 infection: a case report.** *Arch Med (Manizales)*. 2021; 21(2):634-637.
<https://doi.org/10.30554/archmed.21.2.4058.2021>

Summary

Spontaneous pneumomediastinum (SP) is a clinical entity characterized by the presence of interstitial air in the mediastinum. The purpose of this study was to further examine a rare SP case in a 60-year-old male, with COVID-19. In conclusion, SP is an uncommon complication in COVID-19, and the recognition of clinical characteristics is crucial since early identification plays a significant role in the maintenance or recovery of the disease.

Keywords: *pneumomediastinum; dyspnea; coronavirus.*

Archivos de Medicina (Manizales) Volumen 21 N° 2, Julio-Diciembre 2021, ISSN versión impresa 1657-320X, ISSN versión en línea 2339-3874, López-López KE, Sánchez-Prieto D, Tosca-Córdova H, Guzmán-Priego CG, Baeza-Flores GC, Ruiz-Quiñones JA.

- 1 Residente en Medicina Interna. Hospital Regional de Alta Especialidad "Dr. Juan Graham Casasús", Villahermosa, Tabasco, México. ORCID: <https://orcid.org/0000-0002-9448-8953>. E-mail: karlalopez0491@gmail.com
- 2 Residente en Medicina Interna. Hospital Regional de Alta Especialidad "Dr. Juan Graham Casasús", Villahermosa, Tabasco, México. ORCID: <https://orcid.org/0000-0002-1791-6299>. E-mail: denisse_sanchez90@gmail.com
- 3 Especialista en Imagenología. Hospital Regional de Alta Especialidad "Dr. Juan Graham Casasús", Villahermosa, Tabasco, México. ORCID: <https://orcid.org/0000-0003-0162-9700>. E-mail: htoscac@ujat.mx
- 4 Doctora En Ciencias. Laboratorio de Cardiometabolismo. Universidad Juárez Autónoma de Tabasco. División Académica de Ciencias de la Salud, Villahermosa, Tabasco, México. ORCID: <https://orcid.org/0000-0002-8228-1314>. E-mail: crystell_guzman@hotmail.com
- 5 Maestra En Ciencias. Hospital de Alta Especialidad "Dr. Juan Graham Casasús", Laboratorio Diagnóstico Molecular, Villahermosa, Tabasco, México. ORCID: <https://orcid.org/0000-0002-6587-8565>. E-mail: ba_lupitabaeza@hotmail.com
Corresponding author.
- 6 Especialista en Infectología. Hospital de Alta Especialidad "Dr. Juan Graham Casasús", Laboratorio Diagnóstico Molecular, Villahermosa, Tabasco, México. ORCID: <https://orcid.org/0000-0002-3723-333X>. E-mail: drjesusrui@gmail.com. Corresponding autor.

Pneumomediastino espontáneo en la infección por nCOVID-19: un reporte de caso

Resumen

El neumomediastino espontáneo (NE) es una entidad clínica caracterizada por la presencia de aire intersticial en el mediastino. El propósito de este estudio fue examinar más a fondo un caso raro de NE en un hombre de 60 años con COVID-19. En conclusión, el NE es una complicación poco común de COVID-19 y el reconocimiento de las características clínicas es crucial, ya que su identificación temprana juega un papel importante en el mantenimiento y recuperación de la enfermedad.

Palabras clave: neumomediastino; disnea; coronavirus.

Introduction

Coronavirus disease 2019 (COVID-19), caused by the virus SARS-CoV-2, is defined as a pandemic respiratory infection that causes fever, cough, dyspnea, and pulmonary interstitial damage [1]. Unfortunately, SARS-CoV-2 is fastly transmissible between humans and affected approximately 4.81 million people worldwide. As of May 2020, the World Health Organization (WHO) reported 54,346 confirmed cases in Mexico. In Tabasco, a state located in the southeast of Mexico reported 2,716 cases for COVID-19 from 01 March to 30 April.

It is noteworthy to emphasize the clinical presentation in patients infected with SARS-CoV-2: symptoms might range from asymptomatic to critical [2]. Radiological findings on undergoing Chest Computed Tomography (CCT) are bilateral peripheral ground-glass opacities with or without consolidations predominantly affecting lower lobes. Less common findings include fine reticular opacities, vascular thickening, reverse halo sign, air bronchogram, interlobular septal thickening, pleural thickening, lymphadenopathy, cystic changes, and pleural effusion [1].

On the other hand, a review study about Spontaneous Pneumomediastinum (SP) defines it as a rare entity due to the presence of air into the mediastinum in healthy subjects [3]. Heretofore, as mentioned in some studies,

SP has been considered an unusual complication in COVID-19 infection [4-6]. Given the infrequency of this complication, we decided to report a case observed in our institution.

Case presentation

A 60-year-old male patient attended the emergency department with fever, dry cough, asthenia, dyspnea, and adynamia of 4 days of evolution. He was not in contact with COVID-19 patients, and he had not recently traveled.

Physical examination. His vital signs were: temperature 36°C, cardiac frequency 89 beats/min, blood pressure 123/87 mmHg, respiratory frequency 20 breaths/min, SaO₂ 92%. The patient lied in a supine position, chest with increased work of breathing, and use of accessory muscles. Heart sounds were unable to auscultate due to personal protective equipment. During palpation, the right subclavicular region produces subcutaneous crepitation.

Laboratory studies showed leukocytes 17.5x10³/μl (leukocytosis); the white blood cell differential count showed: neutrophils 92.5%, lymphocyte 3%, and monocytes 4%. The red blood cell count was 4.74x10⁶/μl, hemoglobin concentration 14.6 g/dL, hematocrit 43.3%, and platelets count was 334x10³/μ. As for coagulation functions, prothrombin time was 13.9 seconds, activated partial thromboplastin time (APTT)

was 20.50 seconds, INR 1.13, D-dimer testing was 26.28 mg/L and fibrinogen 430.9 mg/dl.

Hematological parameters of C-reactive protein showed an increase (29.6 mg/L), ferritin 1045 ng/ml, lactic dehydrogenase 657 UI/L, and procalcitonin 0.125ug/L.

Arterial blood gases: pH 7.43, pO₂ 78.3 mmHg, pCO₂ 23.0 mmHg, HCO₃ 14.8 mmol/L, EB -8.1mmol/L, oxygen saturation 96%, and lactate 2.9 mmol/L. RT-PCR analysis confirmed the infection of the SARS-CoV-2 virus.

Imaging: an urgent chest computed tomography was requested and showed subcutaneous emphysema (Figure 1), bilateral ground-glass opacities with peripheral distribution, also air into the hilum and pericardial pleura (Figure 2).

The patient was admitted and closely monitoring. He received oxygen therapy, darunavir/cobicistat, as well as azithromycin, and hydroxychloroquine.

Clinical course: after 24 hours, the subject needed advanced airway management despite medical management, and the patient developed Acute Respiratory Distress Syndrome

(ARDS), and refractory hypoxemia. The patient died 48 hrs after admission.

Discussion

Spontaneous pneumomediastinum is an uncommon medical condition with an incidence of 0.001-0.01%; defined as free air in the mediastinum caused by non-traumatic and non-iatrogenic mechanisms in the absence of pre-existing parenchymal or obstructive lung disease [3]. The main differential diagnoses include esophageal perforation, acute coronary syndrome, pericarditis, pneumothorax, musculoskeletal disorders, pulmonary embolism, and recently, COVID-19.

A study finds out that SP was diagnosed in adults between the ages of 18-33 years. In this regard, the main symptoms were: thoracic pain, dyspnea, cough, nasal voice, cervical pain, dysphagia, anxiety, and fever [7]. Our patient was an older adult, and he showed early symptoms of COVID-19.

SP is generally considered a benign disease of clinical importance, with a good prognosis that improves without invasive management [3].

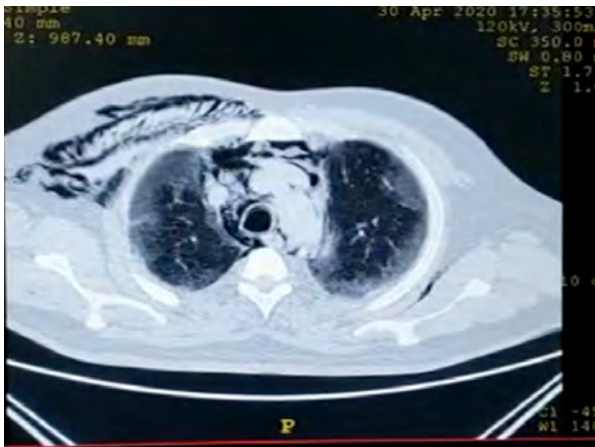

Figure 1. Axial image in standard mediastinal window showing air at the subclavicular and right axillary region. Mediastinum with air in the retrosternal space, aortopulmonary, subcarinal window, and around the trachea.

Source: Imaging service Hospital Regional de Alta Especialidad Dr. Juan Graham Casasús.

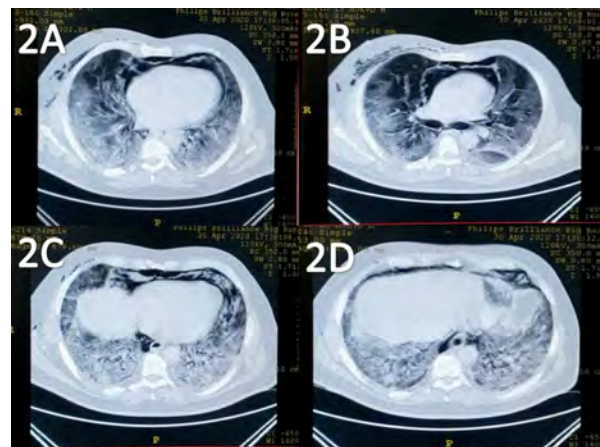


Figure 2. Chest CT features. Axial pulmonary window obtained without intravenous contrast. Panel 2A,2B showed air dissect from the hilum, and the pericardial pleura Panel 2C, 2D showed bilateral pulmonary parenchyma with ground-glass opacities.

Source: Imaging service Hospital Regional de Alta Especialidad Dr. Juan Graham Casasús.

As for the hospital stay, the length of it reported a range of 1-9 days [8]. The diagnosis of SP was confirmed by computed tomography once clinical suspicion was established with the examination. The management was conservative. Notwithstanding the medical care, our patient died after 48 hours of admission. Similar cases where the patients presented an unsatisfactory clinical evolution have been reported [9]. A possible explanation for this outcome was pathophysiology COVID-19, as it has reported by Kolani, and coworkers [6].

Until now, there are some international reports concerning the occurrence of SP in COVID-19, and its data are also in line with the fact that the precise mechanism is unknown [6,9-

12], in this regard, a few groups of researchers suggest that the possible mechanism is related to the increase of alveolar pressure [6,9]. Circulation, infection, or respiratory pathology may be involved [10].

In conclusion, SP is an uncommon complication in COVID-19, and the recognition of clinical characteristics is crucial since early identification plays a significant role in the maintenance or recovery of the disease.

Conflicts of interest: authors have no conflict of interest.

Sources of funding: the research was financed by the Hospital Regional de Alta Especialidad Dr. Juan Graham Casasús.

Cited literature

1. Ye Z, Zhang Y, Wang Y, Huang Z, Song B. **Chest CT manifestations of new coronavirus disease 2019 (COVID-19): a pictorial review.** *Eur Radiol.* 2020; 30:4381-4389. <https://doi.org/10.1007/s00330-020-06801-0>
2. Yuki K, Fujioji M, Koutsogiannaki S. **COVID-19 pathophysiology: A review.** *Clin Immunol.* 2020; 215:1-8. DOI: 10.1016/j.clim.2020.108427
3. Kouritas VK, Papagiannopoulos K, Lazaridis G, Baka S, Mpoukovinas I, Karavasilis V, et al. **Pneumomediastinum.** *J Thorac Dis.* 2015; 7(Suppl 1):S44-S49. DOI: 10.3978/j.issn.2072-1439.2015.01.11
4. Chekkoth SM, Supreeth RN, Valsala N, Kumar P, Raja RS. **Spontaneous pneumomediastinum in H1N1 infection: uncommon complication of a common infection.** *J R Coll Physicians Edinb.* 2019; 49(4):298-300. DOI: 10.4997/jrcpe.2019.409
5. Wang J, Su X, Zhang T, Zheng C. **Spontaneous Pneumomediastinum: A Probable Unusual Complication of Coronavirus Disease 2019 (COVID-19) Pneumonia.** *Korean J Radiol.* 2020; 21(5):627-8. DOI: 10.3348/kjr.2020.0281
6. Kolani S, Nawfal H, Haloua M, Lamrani YA, Boubbou M, Serraj M, et al. **Spontaneous pneumomediastinum occurring in the SARS-COV-2 infection.** *IDCases.* 2020; 21:1-4. DOI: 10.1016/j.idcr.2020.e00806
7. Mondello B, Pavia R, Ruggeri P, Barone M, Barresi P, Monaco M. **Spontaneous Pneumomediastinum: Experience in 18 Adult Patients.** *Lung.* 2007; 185(1):9-14. DOI:10.1007/s00408-006-0002-7
8. Macia I, Moya J, Ramos R, Morera R, Escobar I, Saumench J, et al. **Spontaneous pneumomediastinum: 41 cases.** *Eur J Cardiothorac Sur.* 2007; 31(6):1110-4. DOI: 10.1016/j.ejcts.2007.03.008
9. López-Vega JM, Parra-Gordo ML, Díez-Tascón A, Ossaba-Vélez S. **Pneumomediastinum and spontaneous pneumothorax as an extrapulmonary complication of COVID-19 disease.** *Emerg Radiol.* 2020; 1-4. DOI: 10.1007/s10140-020-01806-0
10. Zhou C, Gao C, Xie Y, Xu M. **COVID-19 with spontaneous pneumomediastinum.** *Lancet Infect Dis.* 2020; 20(4):510-510. DOI: 10.1016/S1473-3099(20)30156-0
11. Mohan V, Tauseen RA. **Spontaneous pneumomediastinum in COVID-19.** *BMJ Case Rep.* 2020; 13(5):e236519. DOI: 10.1136/bcr-2020-236519
12. Wang W, Gao R, Zheng Y, Jiang L. **COVID-19 with spontaneous pneumothorax, pneumomediastinum and subcutaneous emphysema.** *J Travel Med.* 2020; 27(5):1-2. DOI: 10.1093/jtm/taaa062

