

Immunoscintigraphy and Radioimmunotherapy in Cuba: Experiences with Labeled Monoclonal Antibodies for Cancer Diagnosis and Treatment (1993–2013)

Yamilé Peña MD PhD, Alejandro Perera PhD, Juan F. Batista MD

ABSTRACT

INTRODUCTION The availability of monoclonal antibodies in Cuba has facilitated development and application of innovative techniques (immunoscintigraphy and radioimmunotherapy) for cancer diagnosis and treatment.

OBJECTIVE Review immunoscintigraphy and radioimmunotherapy techniques and analyze their use in Cuba, based on the published literature. In this context, we describe the experience of Havana's Clinical Research Center with labeled monoclonal antibodies for cancer diagnosis and treatment during the period 1993–2013.

EVIDENCE ACQUISITION Basic concepts concerning cancer and monoclonal antibodies were reviewed, as well as relevant international and Cuban data. Forty-nine documents were reviewed, among them 2 textbooks, 34 articles by Cuban authors and 13 by international authors. All works published by the Clinical Research Center from 1993 through 2013 were included. Bibliography was obtained from the library of the Clinical Research Center and Infomed, Cuba's national health telematics network, using the following keywords: monoclonal antibodies, immunoscintigraphy and radioimmunotherapy.

RESULTS Labeling the antibodies (ior t3, ior t1, ior cea 1, ior egf/r3, ior c5, h-R3, 14F7 and rituximab) with radioactive isotopes was a basic line of research in Cuba and has fostered their use as diagnostic

and therapeutic tools. The studies conducted demonstrated the good sensitivity and diagnostic precision of immunoscintigraphy for detecting various types of tumors (head and neck, ovarian, colon, breast, lymphoma, brain).

Obtaining different radioimmune conjugates with radioactive isotopes such as ^{99m}Tc and ^{188}Re made it possible to administer radioimmunotherapy to patients with several types of cancer (brain, lymphoma, breast). The objective of 60% of the clinical trials was to determine pharmacokinetics, internal dosimetry and adverse effects of monoclonal antibodies, as well as tumor response; there were few adverse effects, no damage to vital organs, and a positive tumor response in a substantial percentage of patients.

CONCLUSIONS Cuba has experience with production and radiolabeling of monoclonal antibodies, which facilitates use of these agents. Studies in Cuba conducted by the Clinical Research Center over the past 20 years have yielded satisfactory results. Evidence obtained suggests promising potential of monoclonal antibodies and nuclear medicine, with immunoscintigraphy and radioimmunotherapy techniques providing alternatives for cancer diagnosis and treatment in Cuba.

KEYWORDS Immunoscintigraphy, radioimmunotherapy, radioimmune conjugate, labeling, monoclonal antibody, immunochromatography, radioimmunodetection, radiolabeled immunoscintigraphy, Cuba

INTRODUCTION

Cancer is the leading cause of death in Cuba. In 2012, the cancer mortality rate was 200.3 per 100,000 population, with a total of 22,532 deaths, an increase of 6106 over the number of deaths in 2000.[1] This is similar to the situation in developed countries, where cancer has surpassed cardiovascular disease as the leading cause of death.[2]

Thus, for several years, researchers globally have been keen to formulate new diagnostic and treatment methods for cancer. Development and use of monoclonal antibodies (mAb) have contributed greatly to this quest. For example, over a dozen mAbs have been approved by the USFDA; many others are still in clinical trials.[3]

Monoclonal antibodies are immunoglobulins produced by hybrid cell lines (hybridomas) derived from the fusion of B lymphocytes from previously immunized animals with myeloma cells adapted for growing in culture.[4] At first, all mAbs were obtained from murine (mouse or rat) hybridomas. This posed certain obstacles to their use in humans—first and foremost, these mAbs induced a human-antibody reaction to the alien protein, a phenomenon known as the HAMA response. This was one of the driving forces behind development of second-generation mAbs, especially for therapeutic use.[4]

Second-generation mAbs, or recombinant antibodies, are molecules produced with molecular biology techniques and recom-

binant DNA—that is, the mAbs are generated by immortalizing the genes that code the immunoglobulin molecule rather than the cell that produces the antibody, as in the case of first-generation mAbs.[5] In recombinant antibodies, the variable region of murine immunoglobulin can be retained, while the constant region (Fc) is human (chimeric antibodies). Alternatively, just the hypervariable murine region can be retained, keeping the remainder human (humanized antibodies).[5] This has resulted in better patient response to treatment with mAbs and a marked reduction in adverse reactions.[5]

Monoclonal antibodies have extremely high specificity; monoclonal and recombinant antibodies can be produced that bind specifically to any antigen molecule, a very useful property.[4,5] Two other characteristics contribute to their success. First, they can be prepared in pure form in large quantities under tightly controlled conditions.[4] Second, they are chemically well-defined substances whose nature and structure are well known, making it possible to formulate stable preparations, thus facilitating their conjugation to tracers such as fluorescent substances, enzymes and radioisotopes.[4,5]

Immunoscintigraphy Most tumors sequester specific antigens or overexpress others that differentiate them from healthy adjacent tissues; this provides the basis for an imaging technique known as immunoscintigraphy. Such antigens—in blood or on

the tumor surface itself—constitute tumor markers. Their corresponding mAb is bonded to a radioisotope, a method called labeling. When a labeled antibody against an antigen is injected, the specific location of the tumor is revealed, since the antibody transports the bound radioisotope's radioactivity specifically to tumor cells. This radioactivity can be detected by devices such as gamma cameras, producing highly sensitive images that facilitate diagnosis of several cancer types.[6]

Immunoscintigraphy can produce both flat and tomographic images. The latter have various advantages: they provide better contrast, since superimposed layers are separated; they more precisely locate a lesion; and they better estimate its size. [6] Immunoscintigraphic image interpretation is based on finding "hotspots" for primary tumors, local recurrences, hepatic or extrahepatic metastases, and tumors in lymph nodes (although liver metastases may be "cold" due to necrosis).[6]

Immunoscintigraphy is an effective diagnostic imaging method that offers the following potential for oncology patients:[6,7]

- Detection of a primary tumor when there is clinical suspicion, or when tumor markers are elevated but the tumor cannot be localized with other imaging techniques;
- Detection of primary tumor dissemination to solid organs or lymph nodes (to determine stage and contribute to choice of therapy); and
- Early detection of local or tumor-associated recurrence, when there is clinical suspicion or tumor markers are elevated.

Radioimmunotherapy One of the most important therapeutic advances in cancer treatment in the past 25 years has been immunotherapy with mAbs. In November 1997, USFDA approved the first one, rituximab (Mabthera, Rituxan) for clinical use in cancer treatment. This is a chimeric antibody that targets CD20 antigen in B cells. Its initial indication was for treatment of refractory or recurrent low-grade follicular non-Hodgkin lymphomas.[8] This mAb is now used routinely as first-line monotherapy or added to a chemotherapy cocktail. The addition of rituximab to CHOP therapy (cyclophosphamide, doxorubicin, vincristine and prednisone) has increased overall patient survival by 15%.[9]

In February 2002, USFDA approved the first radiopharmaceutical that combines ⁹⁰Y, a radionuclide emitter of pure β-radiation, with the parental mAb of rituximab—ibritumomab, a murine immunoglobulin G1 (IgG1) kappa that targets the same epitope of the CD20 antigen. The two components, radionuclide and mAb, bind through a tiuxetan molecule (Mx-DTPA), a powerful chelator. The product, ⁹⁰Y-ibritumomab-tiuxetan, is marketed in the USA and Europe under the commercial name Zevalin. Its therapeutic effect is produced by high doses of radiation delivered at the cellular level by antibody-directed ⁹⁰Y β-radiation aimed at the CD20 antigen on tumor cell surfaces.[8]

The binding of a radionuclide with a mAb to form a radio-immune conjugate adds the benefit of ionizing radiation to immune-mediated cytotoxic effects, thus improving immunotherapy effectiveness. Moreover, evidence suggests that the antigen-antibody bond stimulates radiation's pro-apoptotic effect.[10,11]

Radioimmunotherapy has many advantages over conventional cancer therapies:[9]

- radiosensitivity of some malignant cells (the specific bond permits a higher dose of radiation to the target tissue, causing cell death);
- the "crossfire effect" (absent in conventional immunotherapy) permits radiation of adjacent tumor cells that do not have a specific bond;
- synergistic effect of radiosensitization and immunoregulation;
- short treatment duration (one week vs. months of chemotherapy);
- proven efficacy and prolonged effect (up to 10 years) in hematologic tumors; and
- acceptable level of toxicity.

Radioimmunotherapy efficacy has been demonstrated through multiple clinical trials in cancer patients.[9,12–15] Moreover, it has been confirmed that the radiation received by bone marrow during radioimmunotherapy does not limit administration of complete doses of new chemotherapy regimens, an additional benefit. It has also been confirmed that supportive therapy with bone marrow blood cell precursors, harvested prior to administration of radioimmunotherapy and reimplanted after 12–18 days (once radiation has fallen to minimal levels), can minimize myelotoxicity.[15]

Radioactive isotopes used internationally Tables 1 and 2 show some radioactive isotopes used internationally in labeling mAbs for cancer diagnosis and treatment.[16]

Table 1: Selected radioactive isotopes used internationally in cancer diagnosis

Isotope	Type of decay	T _{1/2}	Energy (%γ)
⁶⁷ Ga	EC, IC, γ	3.26 d	93.311 keV (37.9)
			184.577 keV (20.9)
			300.219 keV (16.8)
¹²³ I	EC, IC, γ	13.2 h	158.97 keV (83.3)
¹³¹ I	β ⁻ , IC, γ	8.02 d	364.48 keV (81.2)
¹¹¹ In	EC, γ	2.81 d	171.28 keV (90.9)
			245.39 keV (94.0)
^{99m} Tc	IT	6.007 h	140.5 keV (89.0)
¹⁸ F	β ⁺ , EC	109.71 min	511 keV (0.0)

EC: electron capture IC: internal conversion IT: isomeric transition
keV: kilo electron volt T_{1/2}: half-life

Table 2: Selected radioactive isotopes used internationally in cancer treatment

Isotope	Particle emitted	T _{1/2}	Energy in keV (%)
³² P	β ⁻	14.3 d	Eβ _{max} = 1710 (100)
⁸⁹ Sr	β ⁻	50.5 d	Eβ _{max} = 1492 (100)
⁹⁰ Y	β ⁻	2.7 h	Eβ _{max} = 2283 (99.98)
¹⁵³ Sm	β ⁻	1.9 d	Eβ _{max} = 809 (20.9)
			Eγ = 103 (28)
¹⁷⁷ Lu	β ⁻	6.73 d	Eβ _{max} = 497.3 (78) Eγ = 113 (3) and 208 (11)
¹³¹ I	β ⁻ , IC, γ	8.02 d	Eβ _{max} = 606 (84) Eγ = 364.48 (81.2)
²¹¹ At	α	7.2 h	Eα = 5868 (41) Eγ = 79 (21.3)
²¹² Bi	α	61 min	Eα = 6051 (25) Eγ = 727 (7)

IC: internal conversion Eα: energy of alpha particles
Eβ_{max}: maximum energy of beta particles Eγ: energy of gamma quanta
keV: kilo electron volt T_{1/2}: half-life

Regardless of the method and radioactive isotope used in labeling mAbs, the procedure must meet the following basic requirements:[16]

- speed and simplicity
- high yield (>90%) and specificity
- stability over time of the complex formed
- preservation of mAb biological properties, sustained pharmacokinetic speed and high capture by target tissue
- stability, availability and nontoxicity of reagents

Nuclear medicine is the specialty that largely performs immunoscintigraphy and radioimmunotherapy for cancer research and treatment. These methods, though effective, are complex and relatively new. This argues for review of the concepts involved and sharing of practical experience, as important to achieving greater use of these therapies and with them, better cancer management and outcomes.

OBJECTIVE

Our objective was to review immunoscintigraphy and radioimmunotherapy techniques as practiced in Cuba, and to describe the experience of Havana's Clinical Research Center (CIC, the Spanish acronym), with labeled mAbs for diagnosis and treatment of cancer during the period 1993–2013.

EVIDENCE ACQUISITION

We reviewed 49 documents: 2 textbooks, 34 articles by Cuban authors, and for context, 13 by international authors. All publications by CIC authors from 1993 through 2013 were included. Bibliography was obtained at the CIC library and searches performed through Infomed, Cuba's national health telematics network, using the keywords "monoclonal antibodies," "immunoscintigraphy," "radioimmunotherapy," and their Spanish equivalents. The literature was analyzed, with emphasis on the Cuban experience.

RESULTS

Cuban experience in labeling mAbs In 1994, the Molecular Immunology Center (CIM, its Spanish acronym) was founded in Havana. This was a major step forward in development, production and use of mAbs (first- and second-generation) for cancer diagnosis and treatment in Cuba.[17,18] As in the rest of the international scientific community, availability of these antibodies in Cuba facilitated a series of research projects that aimed first to label mAbs with radionuclides and then to evaluate use of the resulting radioimmune conjugates in different cancers.

Adequate labeling guarantees high degrees of radiochemical purity and stability of the labeled compound without significantly affecting the antibody's immunoreactivity. There are direct and indirect labeling methods. In the direct method, the radionuclide binds directly to the immunoglobulin. In the indirect method, bifunctional chelators are used that at one end have electrophilic groups capable of binding to the protein's amine, sulfhydryl, or carboxyl groups; and at the other, groups whose function consists of strongly binding to the nuclides of interest.[19]

^{99m}Tc is the radionuclide of choice among radiopharmaceuticals used for imaging in nuclear medicine, thanks to certain advantages: an appropriate half-life ($T_{1/2} = 6.02$ h), isomeric transition with gamma radiation emission energy in the highest detection efficiency range of gamma cameras ($E_{\gamma} = 140$ keV), and avail-

ability through $^{99}\text{Mo}/^{99m}\text{Tc}$ generators at affordable prices.[19] The direct method of labeling antibodies with ^{99m}Tc is simpler and permits labeling with high radioactive concentrations of the product.[19] This requires use of a reagent that reduces disulfide bonds, creating four to six sulfhydryl groups in the molecule that bind with the pentavalent technetium.[19] One of the most frequently used methods is Schwarz's, using 2-mercaptoethanol as the reductant;[20,21] however, other reductants have been used successfully—e.g., by Zayas, sodium metabisulfite as a reductant of the immunoglobulin disulfide bridges.[22]

However, some authors note advantages to indirect methods in terms of greater stability of the labeled compound obtained and greater knowledge of the chemistry of the compounds formed. Nicotinic acid derivatives, among them 6-hydrazine-nicotinamide, have been used in biomolecule labeling, although other derivatives of different chelators have been used internationally with success (MAG3, MAG2, diaminodithiols, etc.).[19] One interesting experience at CIC was the use of a new lysine-based DTPA derivative, which can bind to the sulfhydryl groups produced by incubation of antibodies with sulfosuccinimidyl 4-(N-maleimido-methyl) cyclohexane-1-carboxylate. The efficiency of labeling the modified humanized mAb h-R3 with ^{99m}Tc using this method was adequate, as was its stability.[23,24]

Given its physical and chemical suitability, ^{188}Re has been used in developing new radiopharmaceuticals for the treatment of various illnesses. Rhenium and technetium are both in the VIIB group of the periodic table and thus have similar chemical properties. The methods for labeling antibodies with ^{188}Re are analogous to those used for ^{99m}Tc ; however, substantially larger amounts of reductant are needed to reduce rhenium perrhenate to a +5 degree of oxidation for it to bind to the antibody or its chelates.[25]

Clinical trials in Cuba In 1999 an article in the *Revista Cubana de Oncología* demonstrated the importance of immunoscintigraphic diagnosis of carcinomas of the head and neck with ^{99m}Tc -labeled ior egf/r3, a mAb against epidermal growth factor receptor (EGFR). This study evaluated 18 patients with malignant tumors of the head and neck to determine both the diagnostic value of ^{99m}Tc -labeled ior egf/r3 (for the primary tumor, recurring tumors and metastases) and its toxicity. Sensitivity in primary lesions was 50%; in this case, the specificity of the method could not be calculated, since diagnosis had been histologically confirmed in all patients before the study started. In regional metastases, sensitivity was 36% and specificity 71%, which were considered good. No toxic reactions were detected. The authors concluded that immunoscintigraphy was a useful method for diagnosis of metastases of head and neck carcinomas.[26]

An important line of research and development in Cuba has been mAbs with high-affinity recognition for epithelial tumor-related antigens. From 1992 to 1999, Ramos studied patients with epithelial tumors, aged 18–85 years, of both sexes and any ethnicity, and demonstrated that murine mAbs ior c5, ior egf/r3 and humanized mAb hR3 can recognize epithelial tumors through immunoscintigraphy. The mAbs were pre-labeled with ^{99m}Tc , with greater than 95% efficiency. A total of 301 patients were evaluated: 148 with the mAb ior egf/r3, 14 with the mAb hR3, 59 with ior c5, and 80 combining the ior c5 and ior cea 1 in the same patient. Immunoscintigraphic images were obtained (anterior and posterior views of the chest, pelvis, and abdomen) at 2, 4 and 24 hours

following intravenous administration of a bolus of radioimmune conjugates. Diagnostic sensitivity and precision were over 80%. No false positives were found. No adverse events were detected, and it was demonstrated that mAbs ior c5, ior egf/r3 and hR3 are useful in diagnosis of primary epithelial tumors.[27]

The experience with immunoscintigraphy marked the beginning of a new phase in the use of mAbs and a major advance for treatment of certain types of cancers in Cuba. At the National Oncology & Radiobiology Institute, Faxas investigated cancer treatment with “cold” mAbs (mAbs not labeled with radioactive isotopes); in 1999 she published results from her phase I clinical trial with the mAb ior-t1 (anti-CD6) in patients with T-cell lymphoma, using three dosage levels (200, 400, and 800 mg total in a multidose schedule). There were 5 complete and 3 partial remissions among the 10 patients studied. Immunohistologic examination revealed a reduction in malignant cells expressing CD6. The most common adverse reactions were fever and headache. Higher doses were not associated with better clinical response but did produce more serious toxicity, so lower doses were suggested for future clinical trials.[28]

As part of the phase I clinical trial of the murine mAb ior-t1 with repeated doses (200–800 mg) in patients with cutaneous T-cell lymphoma, the pharmacokinetics and HAMA response in 10 treated patients were studied. In this trial, wide individual variations in estimated maximum serum concentration at two hours were observed. The mAb’s half-life was 13.9–19.6 hours. Most patients developed the HAMA response. The importance of the antibody network in this particular system could not be determined, because a complete assessment had not been done and not all the patients could be studied with the desirable frequency. However, appearance of this second antibody did not seem to inhibit the antitumor response obtained with the mAb ior-t1 in absolute terms, obtaining results similar to those of other antibodies used in oncology.[17]

Rituximab has been used for several years in Cuba, especially in patients with non-Hodgkin lymphoma refractory to conventional treatment. This therapy has yielded very encouraging results and is a promising alternative for patients with no other treatment option. In general, immunotherapy with rituximab is well tolerated and has proven effective. Response rates of 60%–100% have been reported for its use in combination with conventional chemotherapy. Rituximab is also used as first-line therapy, an indication that has raised response and survival percentages in the patients treated.[29–32]

Since 2002, numerous international reports on the treatment of tumors using mAbs labeled with radioactive isotopes have appeared in the literature;[8–11] shortly afterward, radioimmunotherapy development began in Cuba, with encouraging results.[33,34]

CIC experiences CIC has participated with other Cuban scientific institutions in mAbs research, its investigators working on antibody labeling and conducting preclinical and clinical trials with mAbs for over 20 years. Table 3 shows the main mAbs used in CIC studies.[14,19,20,24,25,27,33–41] Initial research largely concerned labeling procedures and methods, obtaining good results with ^{99m}Tc and ¹⁸⁸Re with murine antibodies; satisfactory results were later obtained with humanized antibodies.[24,25,27,35] Building on this were clinical trials to determine pharmacokinetics, biodistribution and internal dosimetry of labeled mAbs. These studies

identified the effect of labeled antibodies on the various organs, enabling establishment of effective optimal doses that would not damage target organs, especially in patients who would later be receiving radioimmunotherapy.[37] One example is Perera’s work on labeling of the humanized mAb hR3 and its use in radioimmunotherapy of epithelial tumors that overexpress EGFR.[25]

Table 3: Main monoclonal antibodies studied at CIC

mAb	Antigen	Radionuclide	Clinical target
ior t3	CD3	^{99m} Tc	Acute rejection of kidney and heart transplant[43]
ior t1	CD6	^{99m} Tc	Rheumatoid arthritis[44]
ior cea 1	CEA	^{99m} Tc	Colorectal carcinomas[34]
ior c5		^{99m} Tc, ¹⁸⁸ Re	Colorectal and ovarian carcinomas[34,40]
ior egf/r3	EGFR	^{99m} Tc	Tumors of epithelial origin[19,28,38]
h-R3	EGFR	^{99m} Tc, ¹⁸⁸ Re	Tumors of epithelial origin[14,16,28, 35–38]
14F7	Ganglioside NGcGM3	^{99m} Tc	Breast and colon cancer[41]
Rituximab	CD20	⁹⁰ Y, ¹¹¹ In	Non-Hodgkin lymphoma[42]

CIC: Clinical Research Center mAb: monoclonal antibody
NGcGM3: N-glycolyl GM3

Epithelial tumors account for more than 80% of neoplasias and generally overexpress EGFR in their cell membranes. Since such overexpression has been directly associated with malignancy and poor prognosis, EGFR has been used as a target to detect more aggressive cancers.[21,27,37,38] Biodistribution studies showed that most of the anti-EGFR antibody (both murine and humanized variants) was captured in the liver, because of the high concentration of EGFR in hepatic cells. The basic excretion route was urinary in both cases.[35–37] Elimination times in blood increased linearly with antibody dose, while clearance in the body diminished in inverse proportion to dose.[36] Sensitivity and specificity varied, depending on tumor location. Overall sensitivity and specificity were: for the murine ior-egf/r3 variant, 84.2% and 100%, respectively; and for the humanized hR3 variant, 76.5% and 100%, respectively.[21,35]

The ability of the anti-EGFR monoclonal antibody hR3 to inhibit interaction of EGF with its receptor and induce cell apoptosis, the marked association between overexpression of EGFR and malignancy of neoplastic cells, and results of previous scintigraphic studies with ^{99m}Tc-labeled antibody pointed to this mAb’s potential for locally-administered radioimmunotherapy for malignant tumors.[14,34]

Given the advantages offered by ¹⁸⁸Re (adequate half-life; emission of gamma radiation of 155 keV, in the range of the greatest gamma camera detection efficiency; suitable beta particle energy; availability through ¹⁸⁸W/¹⁸⁸Re generators; and chemistry similar to that of ^{99m}Tc, with which there was prior experience), hR3 was labeled with this radionuclide, and a phase I clinical trial was conducted of radioimmunotherapy in patients with highly malignant gliomas. The ¹⁸⁸Re-hR3 was administered locally through an Ommaya reservoir (Medtronic, Canada) in the cavity left after tumor recession. The maximum tolerated dose was 370 MBq (10 mCi), with approximately 85% of it remaining in the tumor bed. Of the 11 patients in the trial, 2 exhibited complete remission for a period of >18 months (one is still living after 8 years). This is

encouraging, considering that the mean life expectancy of these patients is only 6 months.[14]

Other murine antibodies have been used in scintigraphic diagnosis of cancerous tumors: the ior cea 1 and ior c5 mAbs, with very encouraging results in visualization of ovarian and colorectal tumors and their metastases (Figures 1, 2).[27,33,39] Also promising are studies conducted with the ^{99m}Tc -labeled mAb 14F7 for diagnosis of breast cancer.[40]

Although labeled antibodies have been used predominantly in nuclear oncology, they have also been employed for other purposes. One example is the murine anti-CD3 mAb for early detection of acute renal transplant rejection.[42] Another is the anti-CD6 mAb ior t, used in visualization of active rheumatoid arthritis.[43] In both cases, the antibodies were directly labeled with ^{99m}Tc . [42,43] Satisfactory results have also been obtained with polyclonal human IgG for detection of inflammatory foci (septic or nonseptic), given the molecules' ability to reach and accumulate in septic lesions through nonspecific mechanisms (vascular hyperpermeability, affinity of the Fc portion of IgG for protein A in the bacterial membrane, and Fc affinity for receptors in macrophages that migrate to areas of inflammation).[19,44]

In tandem with international research developments and with CIM's guidance, CIC, Cuba's Isotope Center and several other institutions in Cuba's public health system are conducting several phase III clinical trials on use of next-generation mAbs in immunoscintigraphy and other diagnostic and therapeutic applications. The results of these studies, involving patients with lung and prostate cancer and cerebral metastases, will expand experience with

radioimmune conjugates, paving the way for subsequent therapeutic use.[46,47]

Moreover, based on clinical practice and experience with the use of "cold" therapy,[48,49] work is under way to develop protocols and clinical trials on radioimmunotherapy for patients with non-Hodgkin lymphoma CD20+ in relapse or refractory to conventional treatment. The initial stages of this research are aimed at obtaining a radioimmune conjugate in Cuba. In this vein is research labeling rituximab with radioactive isotopes such as ^{188}Re , ^{90}Y and ^{111}In . [41] All this will help lower costs and enable greater patient accessibility to this type of treatment.

Development of molecular engineering and nuclear medicine has opened up new approaches to cancer treatment. Research shows that we can reach specific locations in cells, subcellular compartments and metabolic routes with open sources of radiation. Some international authors contend that it will even be possible to reach as-yet unimagined levels within genes themselves.[8] It behooves us to develop these new techniques in Cuba to become more effective in the fight against cancer.

CONCLUSIONS


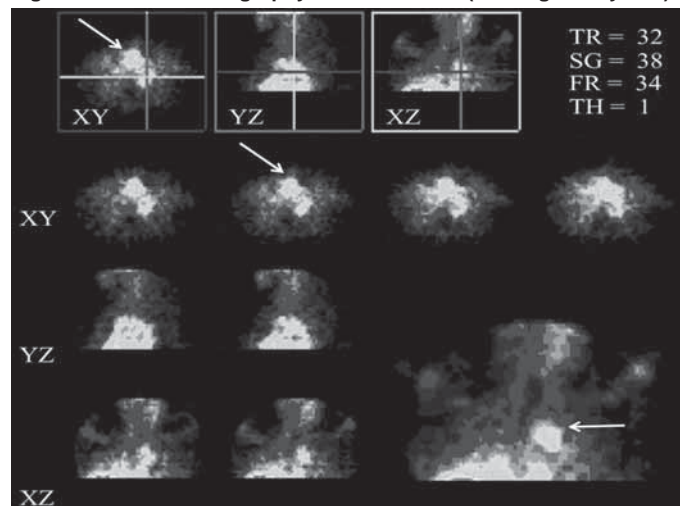
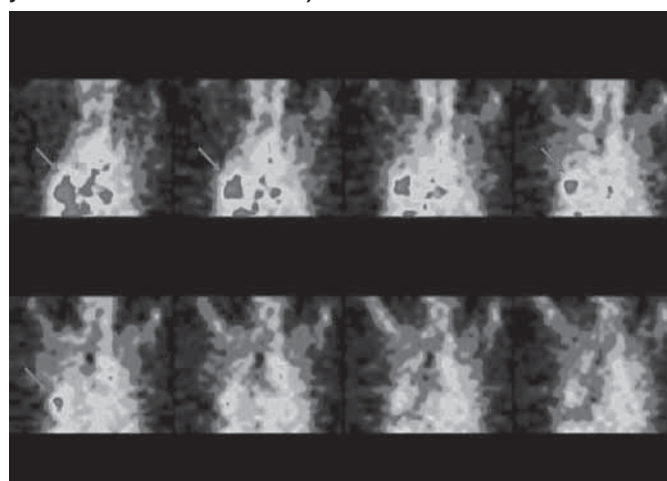
Cuba has experience with production, radiolabeling and use of mAbs. Studies conducted in the CIC from 1993 through 2013 have determined the pharmacokinetics, internal dosimetry, adverse effects and tumor response of several radioimmune conjugates. The evidence supports the vast potential of mAbs and nuclear medicine. Immunoscintigraphy and radioimmunotherapy techniques are promising techniques to improve cancer diagnosis and treatment. 

Figure 1: Immunoscintigraphy with ^{99m}Tc -h-R3 (male aged 62 years)



Topographic thoracic cuts (coronal, transverse and longitudinal) at 24 hours after radioimmunotherapy show intense focal capture. Biopsy confirmed epidermoid carcinoma of tracheal carina. (available in color online at www.medicc.org/mediccreview/pefia.html)

Figure 2: Immunoscintigraphy with ^{99m}Tc -ior cea 1 (male aged 53 years with carcinoma of colon)



Topographic images of thorax 24 hours after radioimmunotherapy show intense focal capture, evidence of pulmonary metastasis undetected by other means. (available in color online at www.medicc.org/mediccreview/pefia.html)

REFERENCES

1. National Statistics Division, Ministry of Public Health (CU). Anuario Estadístico 2012 [Internet]. Havana: Ministry of Public Health (CU); 2013 Apr [cited 2014 Apr 18]. Available from: http://files.sld.cu/dne/files/2013/04/anuario_2012.pdf. Spanish.
2. Siegel R, Naishadham D, Jemal A. Cancer statistics for Hispanics/Latinos, 2012. *CA Cancer J Clin*. 2012 Sep–Oct;62(5):283–98.
3. Scott AM, Wolchok JD, Old LJ. Antibody therapy of cancer. *Nat Rev Cancer*. 2012 Mar 22;12(4):278–87.
4. Cole SP, Campling BG, Attaw T, Kozbor D, Roder JC. Human monoclonal antibodies. *Mol Cell Biochem*. 1984 Jun;62(2):109–20.
5. Vilella R. Anticuerpos monoclonales. Realidades y perspectivas. *Inmunología*. 2004 Dec;23(4):374. Spanish.

6. Pagana KD. Oncogammagrafía (Inmunogammagrafía). In: Pagana KD, Pagana TJ. Guía de pruebas diagnósticas y de laboratorio. 8th ed. Madrid: Elsevier; 2009 Apr 27. p. 726–28. Spanish.
7. Oliva JP, Martínez A, Castro-Beiras JM. Carcinoma medular tiroideo. In: Castro-Beiras JM, editor. Avances en Medicina Nuclear y calidad científico-técnica. Madrid: Medi Técnica, S.L.; 2002. p. 595–606. Spanish.
8. Amaral H, Majlis A, Pruzzo R, Morales B, Gil C, Coudeu I, et al. La medicina nuclear más allá de las imágenes. Rev Med Nucl Alasbimn J. 2005 Jul;7(29). Spanish.
9. Hiddemann W, Kneba M, Dreyling M, Schmitz N, Lengfelder E, Schmits R, et al. Front-line therapy with rituximab added to the combination of cyclophosphamide, doxorubicin, vincristine and prednisone (CHOP) significantly improves the outcome of patients with advanced stage follicular lymphomas as compared to CHOP alone: Results of a prospective randomized study of the German low grade lymphoma study group (GLSG). Blood. 2005 Dec 1;106(12):3725–32.
10. Connors JM. Radioimmunotherapy-hot new treatment for lymphoma. N Engl J Med. 2005 Feb 3;352(5):496–8.
11. Weigert O, Illidge T, Hiddemann W, Dreyling M. Recommendations for the use of Yttrium-90 Ibritumomab Tiuxetan in Malignant Lymphoma. Cancer. 2006 Aug 15;107(4):686–95.
12. Witzig T. Radioimmunotherapy for B-cell non-Hodgkin lymphoma. Best Pract Res Clin Haematol. 2006;19(4):655–68.
13. Inwards DJ, Cilley JC, Winter JN. Radioimmunotherapeutic strategies in autologous hematopoietic stem-cell transplantation for malignant lymphoma. Best Pract Res Clin Haematol. 2006;19(4):669–84.
14. Casacó A, López G, García I, Rodríguez JA, Fernández R, Figueredo J, et al. Phase I single-dose study of intracavitary-administered Nimotuzumab labeled with 188-Re in adult recurrent high-grade glioma. Cancer Biol Ther. 2008 Mar;7(3):333–9.
15. Dillman RO. Radioimmunotherapy of B-cell lymphoma with radiolabelled anti-CD20 monoclonal antibodies. Clin Exp Med. 2006 Mar;6(1):1–12.
16. Sorenson JA, Phelps ME. Physics in nuclear medicine. Philadelphia: Saunders; 2003. p. 499–502.
17. Faxas ME, Guerra ME, Álvarez A, Calderón C. Ensayo clínico fase I del anticuerpo monoclonal IOR-T1 en linfoma T: farmacocinética y respuesta inmune. Rev Cubana Med. 2003 Apr-Jun;42(2):33–8. Spanish.
18. González GP, García IG, González JG, Sánchez LP, Mirabal MV, Marín CC, et al. Phase I Clinical Trial of the 131I-Labeled Anticarcinoembryonic Antigen CIGB-M3 Multivalent Antibody Fragment. Cancer Biother Radiopharm. 2011 Jun;26(3):353–63.
19. Perera A, Pérez C. Radiomarcaje de anticuerpos con tecnecio-99m. Rev Esp Med Nucl. 1998;17(4):302–9. Spanish.
20. Perera A, Pérez C, Torres MB, Hernández A, Heres FC, Moreira T, et al. A kit of human polyclonal IgG for the diagnosis of infectious processes. J Radioanal Nucl Chem. 1999 May;240(2):481–7.
21. Ramos M, Rodríguez N, Oliva JP, Iznaga N, Perera A, Morales A, et al. ior egfr3: A murine monoclonal antibody for diagnosis of epithelial tumors. J Radioanal Nucl Chem. 1999 Dec;240(12):499–503.
22. Zayas F, Perera A, De la Peña L, Hernández T. Sodio metabisulfito. Un nuevo agente reductor para el radiomarcaje de inmunoglobulinas con 99mTc. Rev Esp Med Nucl. 1996;15(5):351–2. Spanish.
23. Sharma RK, Mishra AK, Iznaga N, Perera A, Mathew TL. 99mTc-labeling of humanized monoclonal antibody h-R3 using NH₂-Lys-DTPA. Indian J Nucl Med. 2001;16(3):149–52.
24. Perera A, Paredes M, Mishra AK, Iznaga N, Prats A, Hernández A. Marcaje indirecto de anticuerpos monoclonales empleando la N₂-dieltien-triamino-pentaacetil lisina amida como agente quelatante del 99mTc. Rev CENIC Ciencias Biológicas. 2006;37(4):248–54. Spanish.
25. Perera A, Leyva R, Gamboa R, Alberdi L, Xiques A. Marcaje del anticuerpo monoclonal humanizado h-R3 con 188Re. Nucleus. 2003;33(1):64–8. Spanish.
26. Cruz T, Oliva JP, Borrón M, Pimentel G. Importancia del diagnóstico inmunogammagráfico con el anticuerpo del factor de crecimiento epidérmico en carcinomas de cabeza y cuello. Rev Cubana Oncol. 1999;15(3):160–4. Spanish.
27. Ramos M, Rodríguez N, Oliva JP, Iznaga N, Perera A, Torres L, et al. Estudio del reconocimiento in vivo de los tumores de origen epitelial con los anticuerpos monoclonales ior c5, ior egfr3 y hR3 humanizado, mediante la técnica de inmunogammagrafía. Nucleus. 2003;33(1):54–63. Spanish.
28. Faxas ME, Barroso MC, Ortiz AR, García CA. Observaciones clínicas de la Fase I con el anticuerpo monoclonal IOR-T1 en pacientes con linfoma T cutáneo. Rev Cubana Oncol. 1999;15(1):36–42. Spanish.
29. Ramón LG, Musteliler G, Ávila O, González L, Gutiérrez A, Hernández C. Tratamiento de la macroglobulinemia de Waldenström con R-CHOP. A propósito de un caso. Rev Hematol Mex. 2012;13(4):201–6. Spanish.
30. Espinosa EE, Ramón LG, Izquierdo L, Ávila OM, Hernández C, Espinosa E. Rituximab: historia, farmacología y perspectivas. Rev Cubana Hematol Inmunol Hemoter. 2010;26(1):186–97. Spanish.
31. Izquierdo L, Espinosa EE, Hernández C, Ramón LG, Ávila OM, Espinosa E. Rituximab en leucemia linfocítica crónica en recaída y anemia hemolítica autoinmune. Presentación de un caso. Rev Cubana Hematol Inmunol Hemoter. 2010;26(2):77–81. Spanish.
32. Chávez R, Carnot J, de Castro R, Muñoz J, Pérez G, Núñez A. Características clínicas y resultados terapéuticos de linfomas no Hodgkin de células grandes B mediastinal primarios. Rev Cubana Med. 2011;50(2):157–66. Spanish.
33. Ramos M, Pintado AP, Mesa NR, Oliva JP, Iznaga N, Aroche LT, et al. Diagnostic efficacy and safety of 99mTc-labeled monoclonal antibody ior c5 in patients with colorectal and anal carcinomas: final report clinical trial phase I/II. Cancer Biol Ther. 2007 Jan;6(1):22–9.
34. Torres LA, Coca MA, Batista JF, Casacó A, López G, García I, et al. Biodistribution and internal dosimetry of the 188Re-labelled humanized monoclonal antibody anti-epidermal growth factor receptor, nimotuzumab, in the locoregional treatment of malignant gliomas. Nucl Med Commun. 2008 Jan;29(1):66–75.
35. Torres LA, Perera A, Batista JF, Hernández A, Crombet T, Ramos M, et al. Phase I/II clinical trial of the humanized anti-EGF-r monoclonal antibody h-R3 labelled with 99mTc in patients with tumour of epithelial origin. Nucl Med Commun. 2005 Dec;26(12):1049–57.
36. Crombet T, Torres L, Neninger E, Catalá M, Perera A, Torres O, et al. Pharmacological evaluation of the humanized anti-epidermal growth factor receptor monoclonal antibody h-R3, in patients with advanced epithelial-derived cancer. J Immunother. 2003 Mar-Apr;26(2):139–48.
37. Iznaga N, Torres LA, Morales A, Ramos M, Alvarez I, Pérez N, et al. Technetium-99m-labeled anti-EGF-receptor antibody in patients with tumors of epithelial origin: I. biodistribution and dosimetry for radioimmunotherapy. J Nucl Med. 1998 Jan;39(1):15–23.
38. Ramos M, Rodríguez N, Oliva JP, Iznaga N, Perera A, Morales A, et al. 99mTc-labeled antihuman epidermal growth factor receptor antibody in patients with tumors of epithelial origin: Part III. Clinical trials safety and diagnostic efficacy. J Nucl Med. 1999 May;40(5):768–75.
39. Solano ME, Batista JF, Hernández A, Sánchez E, Pérez MG, Perera A, et al. Immunoscintigraphic diagnosis of ovarian cancer with Tc-99m labeled MAb ior-c5: first clinical results. World J Nucl Med. 2003;2(1):30–6.
40. Oliva JP, Valdés Z, Casacó A, Pimentel G, González J, Alvarez I, et al. Clinical evidences of GM3 (NeuGc) ganglioside expression in human breast cancer using the 14F7 monoclonal antibody labelled with (99m) Tc. Breast Cancer Res Treat. 2006 Mar;96(2):115–21.
41. Leyva R, Perera A, Morín JA. Radiofármacos en inmunocintelografía y radioinmunoterapia. Nucleus. 2012;52(5):68–71. Spanish.
42. Zayas F, Fraxedas R, Reyes L, Perera A, Mañalich R, Hernández L. Evaluación del 99mTc-ior t3 como radiotrazador del rechazo agudo del trasplante renal. Rev Esp Med Nucl. 1997;16(5):329–30. Spanish.
43. Prada DM, Rosabal N, Molinero C, Gómez JA, Hernández IM, López AM, et al. Reumatoid: beneficios clínicos observados en pacientes tratados con anticuerpo monoclonal Itoizumab. (T1h mAb), 2 años después de recibir tratamiento. Rev Cubana Reumatol. 2011;XIII(17):10–8. Spanish.
44. Marrero LO, Álvarez R, Perera A, Yera J, Nicolás R, Hernández A, et al. Inmunografía con 99mTc-IgG policlonal humana no específica en el diagnóstico de la sepsis osteoarticular. Rev Cubana Ortop Traumatol. 2003;17(1–2):7–13. Spanish.
45. Nayak TK, Garmesteni K, Milenic DE, Brechbiel MW. PET and MRI of metastatic peritoneal and pulmonary colorectal cancer in mice with human epidermal growth factor receptor 1-targeted 89Zr-labeled panitumumab. J Nucl Med. 2012 Jan;53(1):113–20.
46. Solomon M, Miranda N, Jorrín E, Chon I, Marinello JJ, Alert J, et al. Nimotuzumab in combination with radiotherapy in high grade glioma patients: A single institution experience. Cancer Biol Ther. 2014 May;15(5): 504–9.
47. Registro Público Cubano de Ensayos Clínicos [Internet]. Havana: National Clinical Trials Coordinating Center (CU); c2014. Código del Registro Público: RPCEC00000016. Use of hR3 MAb and radiotherapy to treat patients with non small cells lung cancer (NSCLC) and brain metastasis; 2013 Nov 8 [cited 2014 Apr 18]; [about 2 p.]. Available from: <http://registroclinico.sld.cu>. Spanish.
48. Croxtall J. El Rituximab es eficaz como terapia de mantenimiento de primera línea del linfoma folicular. Biodrugs. 2011;25(5):329–31. Spanish.
49. Papi S, Martano L, Garaboldi L, Rossi A, Cremonesi M, Grana CM, et al. Radiolabeling optimization and reduced staff radiation exposure for high-dose 90Y-ibritumomab tiuxetan (HD-Zevalin). Nucl Med Biol. 2010 Jan;37(1):85–93.

THE AUTHORS

Yamilé Peña Quián (Corresponding author: yamilpeq@infomed.sld.cu), internist specializing in nuclear medicine with a doctorate in medical sciences, Clinical Research Center (CIC), Havana, Cuba.

Alejandro Perera Pintado, radiochemist with a doctorate in pharmacology, CIC, Havana, Cuba.

Juan F. Batista Cuellar, physician specializing in nuclear medicine, CIC, Havana, Cuba.

Submitted: January 8, 2014

Approved for publication: July 17, 2014

Disclosures: None