

Vertebral bone destruction and *cauda equina* injury of the lumbar spinal canal due to gunshot wound: imaging findings with plain films, CT-myelography and MRI

María Luisa López-Acevedo,* Ernesto Roldán-Valadez,† Roberto Corona-Cedillo,†
Joaquín Hernández-Omaña,‡ Óscar Suárez-Rivera,§ Manuel Martínez-López||

Resumen

Introducción. Las heridas penetrantes de la columna vertebral representan la tercera causa más común de lesión de la médula espinal y *cauda equina*. Las heridas por arma de fuego específicamente representan de 13 a 17% de todas las lesiones de la médula espinal cada año. Presentamos los hallazgos en imagen de un paciente que sufrió una herida de bala en la columna lumbar evidenciada en imágenes de radiografía simple, tomografía (TC), mielo-TC y resonancia magnética (RM) con una breve revisión de la literatura relevante. **Resumen del caso.** Mexicano masculino, de 47 años de edad remitido a nuestro hospital después de una herida de bala en la región lumbar. Las radiografías simples y la TC mostraron fragmentos de hueso y una bala alojada en el canal espinal en el nivel L4-L5. El paciente llegó al Servicio de Urgencias y fue programado para cirugía. La evidencia de astillas residuales y compresión del canal lumbar observadas en mielo-TC permitieron programar una segunda intervención quirúrgica. El seguimiento con RM mostró un parche dural y colección epidural residual causando compresión de la *cauda equina*. No se necesitaron otras medidas quirúrgicas, el paciente mejoró su función motora hasta el punto de la deambulación asistida, el daño del esfínter no se modificó. **Discusión.** La evaluación por imagen comprende la TC como diagnóstico principal, lo que permite una localización precisa de los fragmentos de bala en el canal espinal o cuerpos vertebrales. La utilización de RM en la evaluación de heridas de bala en la columna vertebral se encuentra en debate. Con el auge de la violencia armada en todo el mundo es esencial para los radiólogos tener una comprensión clara de las lesiones por arma de fuego y su evaluación por imagen, especialmente las heridas de bala en la médula espinal que son las más problemáticas.

Palabras clave. Bala. Herida por arma de fuego. Resonancia magnética. Canal vertebral lumbar. Cuerpo vertebral.

Abstract

Introduction. Penetrating wounds of the spine are the third most common cause of spinal cord and *cauda equina* injury. Gunshot wounds specifically, account for 13 to 17% of all spinal cord injuries every year. We present the imaging findings of a patient who sustained a gunshot injury to the lumbar spine evidenced by plain films, CT, CT-myelography and magnetic resonance imaging (MRI) with a brief review of the relevant literature. **Case report.** 47-year-old Mexican man was referred to our hospital after a gunshot wound to the lumbar spine. Plain films and CT depicted bone fragments and a bullet lodged in the spinal canal at L4-L5. The patient arrived to the emergency department and scheduled for surgery. Residual splinters and lumbar canal compression evidenced by CT-myelography allowed to schedule a second surgical procedure. Follow-up MR evaluation showed a dural patch placed over the dura with some epidural fluid collection causing residual compression of the *cauda equina*. No further surgical measures were required, the patient's motor function improved to the point of assisted walking, sphincter damage remained unaltered. **Discussion.** Imaging evaluation comprises CT as the principal diagnostic allowing a precise localization of the bullet fragments within the spinal canal or vertebral segments. Use of MRI in assessing gunshot wounds to the spine is debated upon. With the rise of armed violence worldwide, it is essential for radiologists to have a clear understanding of gunshot injuries and their imaging evaluation, especially gunshot wounds to the spine that are the most problematic.

Key words. Bullet. Gunshot wound. Magnetic resonance. Lumbar spinal canal. Vertebral bone.

**Fellow of the High Specialty Graduate Course in Magnetic Resonance Imaging, Medica Sur Clinic & Foundation and Universidad Nacional Autónoma de México. Mexico City. † Affiliated Radiologist. Medica Sur Clinic & Foundation. Professor of the Magnetic Resonance Graduate Course at Universidad Nacional Autónoma de México. Mexico City. ‡Affiliated Orthopedic Surgeon. Medica Sur Clinic & Foundation. Mexico City. §Affiliated Neurosurgeon. Medica Sur Clinic & Foundation. Mexico City.

||General Director of the MRI Unit, Medica Sur Clinic & Foundation, Mexico City.

Correspondence:

María Luisa López-Acevedo, M.D.

Medica Sur Clinic & Foundation. Puente de Piedra, Núm. 150. Col. Toriello Guerra, C.P. 14050, México, D.F.

INTRODUCTION

Penetrating wounds of the spine are the third most common cause of spinal cord injury. Gunshot wounds specifically, produce potentially devastating injuries that account for 13 to 17% of all spinal cord injuries every year.² Penetrating injuries affecting the *cauda equina* are of extremely rare occurrence compared with penetrating spinal cord injuries, however some cases have been previously reported in the medical literature.³⁻⁵

Spinal cord injuries inflicted by firearms usually result in complete paraplegia,⁶ symptomatology with lesions of the *cauda equina* can be variable depending the site, magnitude and extension of the damage. This neurological outcome results from direct trauma brought about by the bullet, bone fragments, and sometimes disc particles lodged in the spinal canal.⁷

To the best of our knowledge, there are no reports⁸ describing a foreign body lodged into the lumbar vertebral canal after a gunshot injury evidenced by plains films,

computed tomography (CT), CT-myelography and magnetic resonance imaging (MRI).

In this report we present the clinical and imaging findings in the evaluation and follow-up of a patient who sustained a gunshot injury to the lumbar spine, with a brief review of the relevant literature.

CASE REPORT

47-year-old Mexican man was referred to the Radiology Department of our hospital for evaluation after a gunshot wound to the lumbar spine. The patient had undergone clinical evaluation at the Emergency Department and the initial neurological examination revealed flaccid areflexic paraplegia, loss of urinary and anal sphincters, a T-12 sensitive level on the left side and irregular patches of hyperalgesia/hypoesthesia on the lower right limb. Initial imaging evaluation included lumbar plain-films and computed tomography (CT) with 3D reconstructions, depicting a firearm bullet lodged in the lumbar spinal canal at the L4-L5 intervertebral level as well as bone destruction (Figure 1).

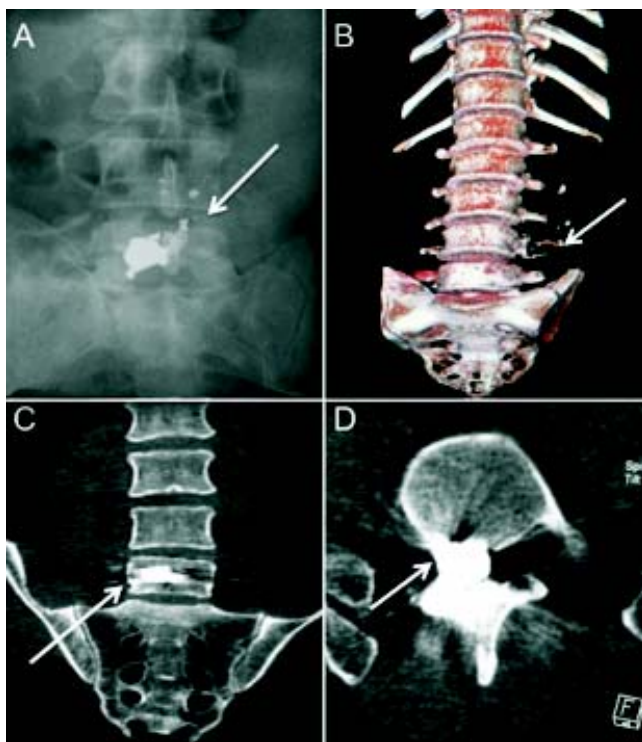


Figure 1. A. Lumbosacral AP plain film depicting a firearm bullet at the L5 level. B. 3D CT reconstruction showing in AP view destruction of the left transverse process of L4 (suggesting direction of the gunshot, white arrow). C and D. Coronal and axial plane images of CT showing the increased signal density corresponding with the fire arm bullet (white arrows).

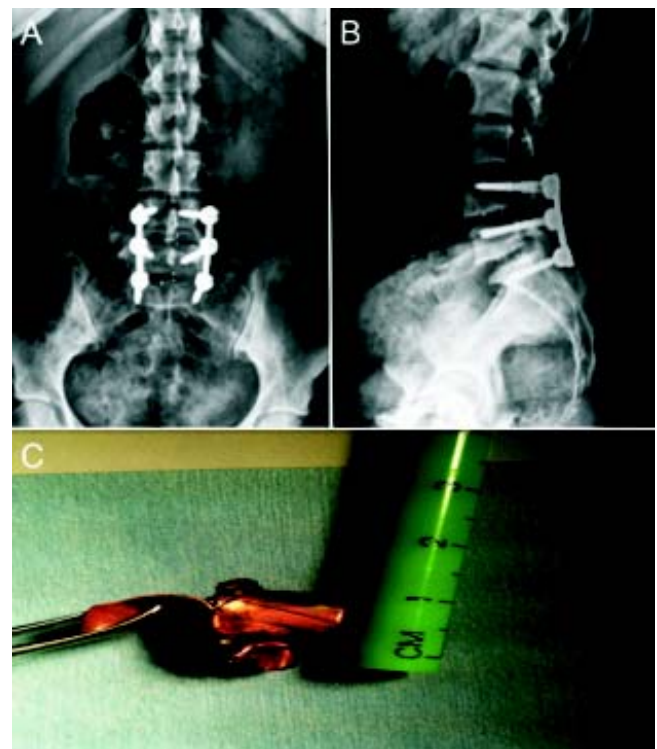


Figure 2. A and B. AP and lateral plain films of the lumbar spine shows fixation of the spine with metallic rods. C. Extraction of the firearm bullet (approximate diameter of 15 mm).

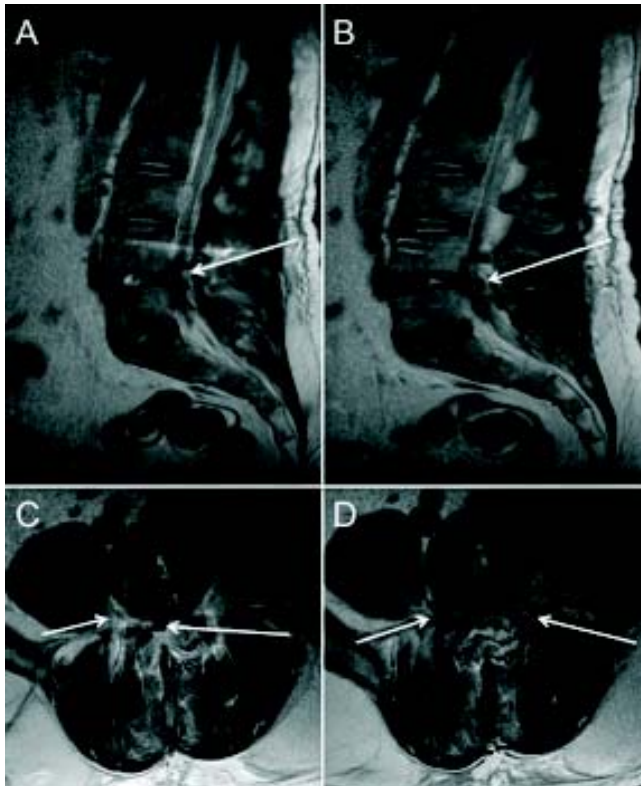


Figure 3. Spine MRI. **A** and **B**. Sagittal plane images showing interruption of the *cauda equina* at the L4-L5 level. **C** and **D**. Axial plane images depict the stenosis of the spinal canal with severe peridural inflammatory process, it is possible to see the transpedicled metallic rods.

The patient underwent a first surgical procedure. Bone and articular fragments were extracted corresponding with pedicle, left facet joint and a fragment of lamina impacted in the lumbar canal. It was also possible to extract the bullet lodged in the right L4-L5 foramina and to release the compression of the lumbar canal at that level. Figures 2 and 3 depicts the imaging findings after surgery.

Approximately 3 weeks after surgery, the patient underwent a CT-myelography; his condition had been reported stable. 2D and 3D CT reconstruction of the lumbar spine depicted bone fragments outside the lumbar spinal canal with one splinter from the handgun inside the spinal canal; two additional residual splinters were evidenced in the lumbar spinal canal at the entrance of the right intervertebral foramen L4-L5 (Figures 4 and 5).

Neurological examination during that period revealed increased sensibility in the left foot, increased muscle tone to the point of some voluntary movement in the left dorsiflexors. Electromyography, neural conduction velocity stu-

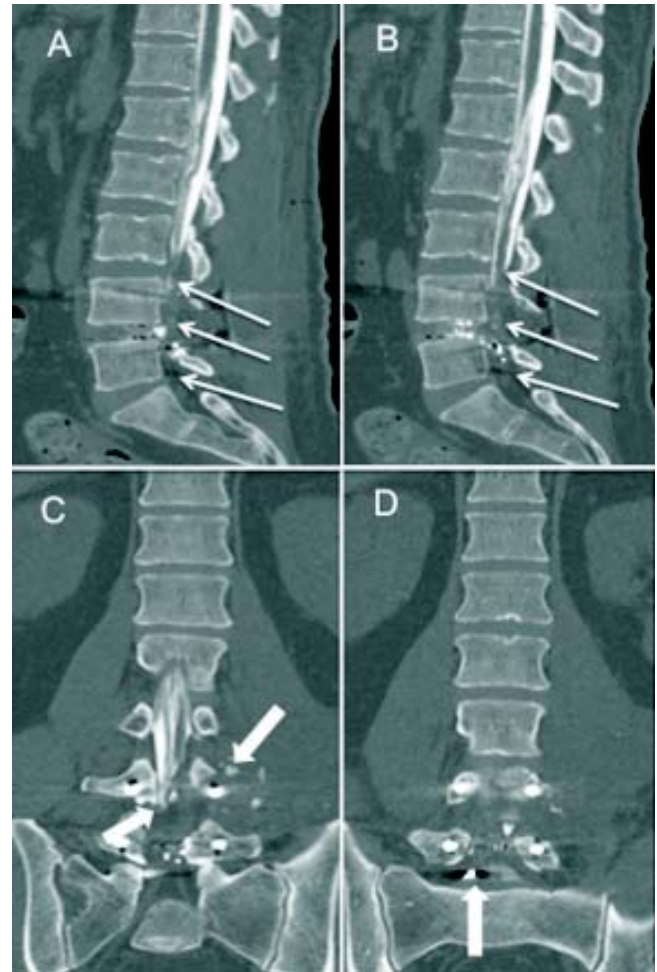


Figure 4. Postoperative CT-myelography with multiplanar reconstructions. **A** and **B**. Sagittal plane images show the interruption of the CSF at the L4 level in the sagittal plane (white narrow arrows). **C** and **D**. Coronal plane depicting the interruption of the *cauda equina* and the presence of bone fragments outside the spinal canal with one residual splinter from the handgun inside the spinal canal at the L4-L5 levels (thick white arrows).

dies, and somato-sensorial evoked potentials showed incomplete lumbar nerve block. In view of these findings and a neurosurgical evaluation the patient underwent a second surgical procedure. A complete L4-L5 laminectomy was performed, with dural opening and exploration of the *cauda equina*. The dura and arachnoid membranes were seen to be ruptured, with avulsion of some of the distal lumbar nerve roots. Bone and metal fragments were extracted; an artificial dural patch (duragen) was placed over the dural aperture. The MRI evaluation after the second surgery showed evidence of the dural patch over the dural

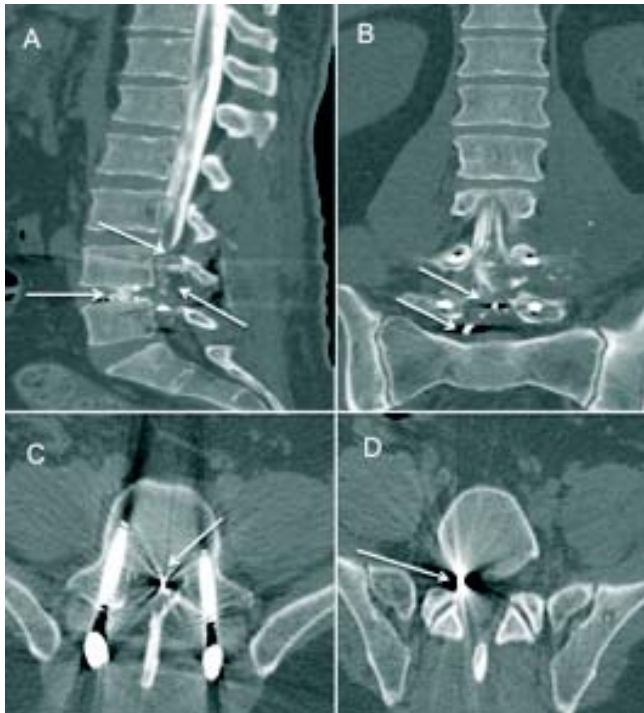

Figure 5. Postoperative CT-myelography with multiplanar reconstructions. **A.** Sagittal plane image shows the interruption of the CSF containing contrast and the presence of splinters the intervertebral level L4-L5 (white arrows). **B.** Coronal plane showed two residual splinters from the handgun at the L5 lumbar canal (white arrows). **C** and **D.** Axial plane at the level of L5-S1 showing metallic rods (thick arrows) together with presence of the two previously seen splinters, this plane evidence location of splinters in the lumbar spinal canal and at the entrance of right intervertebral foramen.

aperture with some epidural fluid collection causing compression of the *cauda equina* at the levels L4 and L5 (Figure 6).

No further surgical measures were required, the patient's motor function improved to the point of assisted walking, sphincter damage remained unaltered. He continues attending our hospital as an outpatient in the neuro-rehab clinic.

DISCUSSION

After a gunshot wound, spinal cord and/or *cauda equina* injuries occur as a result of direct damage by the bullet or metallic particles, or as a result of compression by the broken bone particles. Although less commonly observed, disc material can cause neural defects by compressing the canal when the bullet damages the annulus.⁹ When a bullet fragment settles in

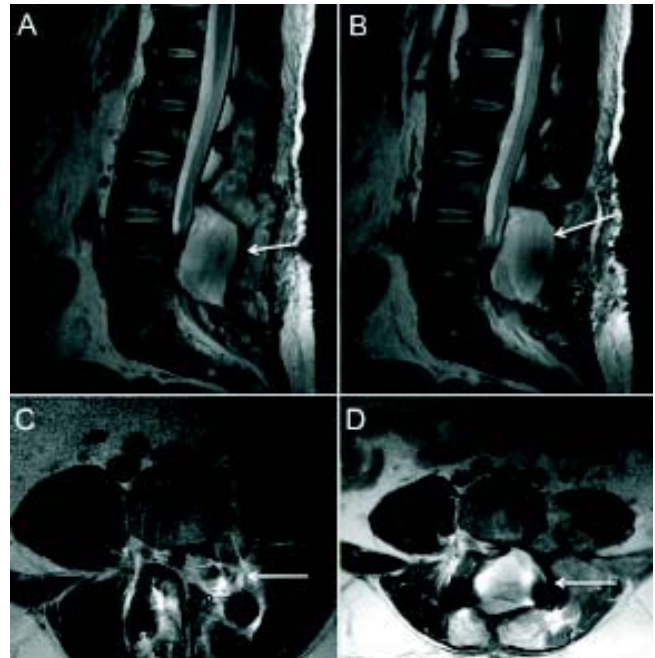


Figure 6. Postoperative lumbar spine MRI. **A** and **B.** Sagittal plane images showing evidence of the dural patch placed over the dural aperture there is epidural fluid collection causing compression of the *cauda equina* at the levels L4 and L5. **C** and **D.** Axial plane images depict the reflection artifacts associated to metallic rods in oblique position, rods contacted the boundaries of the epidural fluid collection, there was evidence of lumbar spinal canal stenosis.

the intervertebral space or foramen, the nucleus pulposus is subjected to increased pressure, and can sometimes be ejected into the spinal canal. In the case of this patient, the bullet, splinters and bone fragments were lodged in the spinal canal.

Energy from a gunshot projectile is directly related to both the mass and the square of the velocity of the bullet ($E = 1/2 mv^2$). Gunshot energy is further classified into low and high energy, depending on muzzle velocity (the speed a projectile has at the moment it leaves the end of the barrel from which the projectile will exit). Velocities < 1,000 to 2,000 feet/second (304.8 to 609.6 m/sec) are defined as low energy, whereas speeds > 2,000 to 3,000 feet/second (609.6 to 914.4 m/sec) are defined as high energy.¹⁰ Low-energy firearms include pistols and handguns; high-energy and high-velocity weapons include military assault rifles.¹⁰

Due to the pessimism associated with poor functional outcome,⁵ the traditional approach for the management of firearm injury of the spine has been initially non aggressive, spinal cord decompression is advised only if there is neurological deterioration during observation.¹¹ Reported

injuries in the spinal zone are generally stable.¹² If the bullet in the lumbar zone breaks the pedicle or facet while traversing it, can cause an acute or chronic instability.¹⁰ If the pedicle or facet is intact, no spinal instability is observed. Imaging evaluation at this stage may included CT and MRI.¹³

Upon arrival, a thorough general evaluation is carried out, since the patient is likely to have suffered multi-organ damage due to multiple splinters. After hemodynamic stabilization and attention to visceral and thoracic injuries, neurological evaluation is carried out and a neurological grade is assigned.¹⁴ Proper immobilization, care of the skin, bladder catheterization, and administration of steroids forms the interim management pending surgery.¹¹

Cauda equina lesions (as in this case) are an important indication for surgical exploration since these injuries carry a better functional prognosis due to the involvement of the nerve roots and not the spinal cord. Surgical exploration, decompression and removal of a bullet or bone fragments decompresses the nerve roots, allowing for better recovery of neurological function.¹¹ The indications for surgery should not be as much for neurological recovery as for avoiding the complications of CSF leak from the wound. Moreover, retained intraspinal fragments in the region of *cauda equina* can lead to chronic pain and should be removed.¹⁵ In the case presented, both findings were present in the follow-up MR evaluation.

The scope of surgery includes debridement of the bullet track and removal of bone and bullet fragments from the spinal canal, visualization of the cord to determine prognosis, surgical decompression of the cord and dural closure with or without duroplasty.¹¹

The main goal in surgery is improvement in the neurological grade: it is often achievable in incomplete injuries but neurological improvement in cases with grade 0/5 power is still a miracle; avoidance of complications pertaining to external CSF fistulae; avoidance of pyogenic complications such as meningitis, spinal abscess, etc.; and facilitation of early rehabilitation. Treating surgeons must understand the exact role and scope of surgical intervention, so that neurological function can be preserved and further deterioration recognized and treated.

Imaging studies comprise CT as the principal diagnostic tool allowing a precise localization of the bullet fragments within the spinal canal or vertebral segments.⁹ Use of MRI in assessing gunshot wounds to the spine is debated upon. There is legitimate concern that bullet fragments may migrate under the magnetic pull and cause additional damage and injury.^{16,17} The advantages

of MRI over CT include markedly less artifacts; better soft-tissue imaging, and coronal, sagittal, and axial visualization of neural elements.^{16,18} Imaging evaluation with MRI is carried out in selected cases where the missile has exited, especially in cases with root avulsion and intramedullary hemorrhage and without associated vertebral injury.¹¹

CONCLUSIONS

With the rise of armed violence worldwide, it is essential for radiologists to have a clear understanding of gunshot injuries and their imaging evaluation, especially gunshot wounds to the spine that are the most problematic.

REFERENCES

1. Miller CA WR, Rengachary SS (eds.). Penetrating wounds of the spine. Neurosurgery. Vol. II. 1985, p. 1746-8.
2. Farmer JC, Vaccaro AR, Balderston RA, Albert TJ, Cotler J. The changing nature of admissions to a spinal cord injury center: violence on the rise. *J Spinal Disord* 1998; 11(5): 400-3 [Epub 1998/11/12].
3. Mikami Y, Tasaki A, Morita W, Kuroda E, Hoshikawa Y. Penetrating injury to the cauda equina: a case report and review of the literature. *J Spinal Disord Tech* 2011 [Epub 2011/03/26].
4. Zhou Z, Song Y, Cai Q, Li T, Liu H. Penetrating injury of rectum and vertebral body by steel bar causing cauda equina syndrome. *Spine (Phila Pa 1976)* 2011; 36(12): E803-E807 [Epub 2011/02/04].
5. Galano E, Gelis A, Oujamaa L, Dutray A, Pelissier J, Dupeyron A. An atypical ballistic traumatic cauda equina syndrome with a positive outcome. Focus on prognostic factors. *Ann Phys Rehab Med* 2009; 52(10): 687-93 [Epub 2009/11/10].
6. DeVivo MJ, Hawkins LN, Richards JS, Go BK. Outcomes of post-spinal cord injury marriages. *Arch Phys Med Rehabil* 1995; 76(2): 130-8 [Epub 1995/02/01].
7. Mirovsky Y, Shalmon E, Blankstein A, Halperin N. Complete paraplegia following gunshot injury without direct trauma to the cord. *Spine (Phila Pa 1976)* 2005; 30(21): 2436-8 [Epub 2005/11/02].
8. Kalkan E, Keskin F, Cengiz SL, Baysefer A. A case report of firearm bullet settling into the thoracic spinal canal without causing neurological deficit or vertebral bone destruction. *Arch Orthop Trauma Surg* 2007; 127(8): 637-41 [Epub 2007/03/08].
9. Bono CM, Heary RF. Gunshot wounds to the spine. *Spine J* 2004; 4(2): 230-40 [Epub 2004/03/16].
10. Yoshida GM, Garland D, Waters RL. Gunshot wounds to the spine. *Orthop Clin North Am* 1995; 26(1): 109-16 [Epub 1995/01/01].
11. Bhatoe HS, Singh P. Missile injuries of the spine. *Neurol India* 2003; 51(4): 507-11 [Epub 2004/01/27].
12. Meyer PR AD, Bohlman HH, Ferguson RL, Stauffer ES. Symposium: management of fractures of the thoracolumbar spine. *Contemp Orthop* 1988; 16: 57-86.
13. Waters LR SH. Spinal cord injuries from gunshot wounds to the spine. *Clin Orthop Rel Res* 2003; 408: 120-5.

14. Benzel EC, Larson SJ. Functional recovery after decompressive spine operation for cervical spine fractures. *Neurosurgery* 1987; 20(5): 742-6 [Epub 1987/05/01].
15. David CA LH, Green BA. Penetrating wounds of the spine. *Neurosurgery*. Vol II. San Francisco: McGraw-Hill Book; 1996, p. 3055-61.
16. Kumar A, Wood GW 2nd, Whittle AP. Low-velocity gunshot injuries of the spine with abdominal viscus trauma. *J Orthop Trauma* 1998; 12(7): 514-7 [Epub 1998/10/22].
17. Finitis SN, Falcone S, Green BA. MR of the spine in the presence of metallic bullet fragments: is the benefit worth the risk? *AJNR Am J Neuroradiol* 1999; 20(2): 354-6 [Epub 1999/03/27].
18. Bashir EF, Cybulski GR, Chaudhri K, Choudhury AR. Magnetic resonance imaging and computed tomography in the evaluation of penetrating gunshot injury of the spine. Case report. *Spine (Phila Pa 1976)* 1993; 18(6): 772-3 [Epub 1993/05/01].