

Hydronephrosis and pyelonephritis in a pregnant woman: a proposal of MR urography clinical applications

Rocío Ramírez-Carmona,* Manuel Martínez-López,* Ernesto Roldán-Valadez*

RESUMEN

Introducción. La uorresonancia magnética se ha utilizado satisfactoriamente para evaluar los riñones, el sistema pielocaliceal, uréteres y vejiga urinaria. Esta técnica tiene la ventaja de no utilizar radiación ionizante, además del potencial de proveer información funcional como lo hace la tomografía, incluso más. **Caso clínico.** Embarazada de 25 años con dolor lumbar del lado derecho y sospecha de urolitiasis. Las imágenes de uorresonancia estática demostraron la compresión ureteral extrínseca condicionada por el útero gestante en su tercio inferior bilateral, aunque de predominio derecho. También se documentó hidronefrosis derecha y pielonefritis. La adquisición de las imágenes, guiadas durante el estudio por un radiólogo experto, se complementó con imágenes del nivel pélvico para demostrar la unión urétero-vesical sin evidencia de urolitiasis. **Discusión.** La uorresonancia se basa en dos estrategias de imagen que pueden complementarse para cubrir la mayor parte de los diagnósticos de patologías del tracto urinario superior. La primera técnica utiliza secuencias de pulso no contrastadas en T2 para obtener imágenes con líquido estático del tracto urinario aun si la función renal es anormal. La segunda técnica es análoga a la urografía intravenosa convencional y se llama uorresonancia excretora, en la que es necesario administrar de forma endovenosa un contraste no nefrotóxico a base de un quelato de gadolinio y después de su excreción renal la urina realzada con el gadolinio se visualiza con secuencias rápidas ponderadas a T1 con saturación grasa. El protocolo de urografía con resonancia magnética en combinación con imágenes de resonancia magnética convencional reduce la necesidad de una pielografía invasiva.

Palabras clave. Uorresonancia con líquido estático. Uorresonancia excretora. Urolitiasis. Obstrucción del tracto urinario. Embarazo. Paciente pediátrico.

ABSTRACT

Introduction. MR urography has been used satisfactorily to evaluate kidneys, pelvicaliceal system, ureters and bladder, this technique has the advantage of not using ionizing radiation and also the potential to provide functional information as CT or even more. **Case report.** We present a case of a 25-years-old pregnant woman with right lumbar pain and probable urolithiasis, the static fluid MR urography demonstrate extrinsic ureteral compression by the pregnant uterus at the lower third bilaterally but predominantly right as well as, right kidney hydronephrosis and pyelonephritis, with the direction of an MR specialized radiologist, pelvic complementary images were taken in order to evaluate the ureter-bladder junction without evidence of urolithiasis. **Discussion.** MR urography is based in two different imaging strategies basically, which can be used in a complementary manner to cover the mayor aspects in the diagnosis of the upper urinary tract diseases. The first technique utilizes unenhanced heavily T2-weighted pulse sequences to obtain static-fluid images of the urinary tract, even if the renal excretory function is abnormal. The second MR urography technique is analogous to conventional intravenous urography and is called excretory MR urography, in which is necessary to administer intravenously a non-nephrotoxic gadolinium chelate and after its renal excretion, the gadolinium-enhanced urine is visualized using fast T1-weighted fat saturated sequences. Magnetic resonance urography protocol performed in combination with standard MR imaging offers a potential to reduce the need for invasive pyelography.

Key words. Static-fluid MR urography. Excretory MR urography. Urolithiasis. Urinary tract obstruction. Pregnant women. Pediatric patients.

* MRI Unit, Medica Sur Clinic & Foundation, Mexico City.

Correspondence:

Ernesto Roldán-Valadez, M.D.

Magnetic Resonance Unit, Medica Sur Clinic & Foundation. Puente de Piedra, No. 150. Col. Toriello Guerra. Deleg. Tlalpan. C.P. 14050, Mexico City, Mexico. Tel.: (52 55) 5666-1625. E mail: ernest.roldan@usa.net

INTRODUCTION

Magnetic resonance urography (MRU) was described since 1987 at the University Hospital of Freiburg Germany, as a complementary method to evaluate urinary tract abnormalities. Due to the long T2 relaxation time of fluid in the collecting system, heavily T2-weighted sequences have been used.¹ MRU provides a non-invasive visualization not only of the collecting system but also of the renal parenchyma using fast spin-echo pulse sequences as well. Currently the most common MR urographic techniques for examine the urinary tract can be divided into two categories: static-fluid MR urography and excretory MR urography. Static-fluid MR urography includes heavily T2-weighted sequences to image the urinary tract as a static collection of fluid, which can be repeated with cine MR urography principally to confirm stenosis. Excretory MR urography is performed during the excretory phase of gadolinium enhancement after de intravenous administration in patients with an adequate renal function. Diuretic administration can be useful in excretory MR urography in demonstration of nondilated collecting systems.²

There are several publications showing the utility and transcendence of MRI urography, although currently this is not a routine test, even with the acknowledgement of its special applications in pediatric and pregnant women population (Table 1).

Clinical urography requires both morphological and functional information about the kidneys and collecting system. MRU performed with contrast material can meet all demands of clinical urography and in some cases, could replace conventional X-ray urography.

We present a case of a 25-years-old pregnant woman in the 19th week of gestational state with urinary symptoms, right lumbar pain and no fever who underwent abdominal ultrasound and MRU. The main imaging findings are presented as well as a brief review of the relevant literature.

CASE REPORT

A 25-years-old woman, at 19 weeks of normal pregnancy was admitted to our hospital due to a clinical history of 7 days with dysuria, tenesmus, urinary urgency and colic pain in the right lumbar zone irradiated to the ipsilateral iliac fossa. Physical examination performed at emergency room revealed right lumbar tenderness on palpation and no fever was reported. Under this clinical setting an abdominal ultrasound dedicated to urinary system was performed, which shows bilateral pyelocaliceal dilatation

predominantly in the right kidney without hyperechoic image suggesting lithiasis (Figure 1) and dilatation of right ureter was suspected in the exploration of the pelvis along the right iliac vein (Figure 2).

Subsequently an MR urography was requested by the physician and carried out without contrast, this reported hydronephrosis and pyelonephritis of the right kidney, with bilateral but predominantly right ureteral dilatation secondary to external compression by pregnant uterus and no evidence of ureterolithiasis was found (Figure 3 and 5). The patient received conservative treatment for urinary infection, she was discharged of the emergency area and continued her follow-up as an outpatient with satisfactory evolution.

DISCUSSION

Static and excretory MRU are complementary methods for morphological and functional evaluation of the urinary system, in this case, considering the pregnancy age of the patient, only and static MRU was performed, however the obtained information was enough to make a diagnosis and decisions on treatment. This case results quite interesting due to the low frequency still of urinary system assessment using this non-invasive method, even when it is well known that MR is clinically useful in evaluating many urinary tract disorders, not only those related with urolithiasis but also, congenital anomalies, diagnosis and staging of cancers of the kidneys, bladder, and prostate gland, and even the assessment of renal function.²

The MRU has some considerations, which are important to know for clinicians:

- **Patient preparation.** Asking the patients to void prior to entering the imager improves their comfort and prevents interruption of the study at an inopportune time. If there are no contraindications, patients should be given 250 mL of normal saline solution intravenously at the start of imaging. Usually oral negative contrast agents are not required to reduce the signal intensity of bowel contents.²
- **Advantages and limitations.** Inherently, MR imaging is superior to other techniques such as computed tomography (CT) in that it provides better tissue contrast resolution, greater sensitivity for contrast enhancement, and can potentially provide more information about tissue properties than does radiography or CT. Above all, unlike intravenous urography and CT urography, MR imaging does not use ionizing radiation and this favor certain patient populations such as

Table 1. Publications showing the transcendence of MR urography in different scenarios.

Year	Author(s)	Title	Journal	Conclusion
2010	O Connor	MR urography	<i>AJR</i>	MRU is a useful one-stop imaging technique for pregnant and pediatric patients, for patients with impaired renal function, and for patients with congenital abnormalities.
2009	Silverman	What is the current role of CT urography and MR urography in the evaluation of the urinary tract?	<i>Radiology</i>	Despite the diagnostic superiority of CT and MR urography relative to intravenous urography, each test has its limitations and disadvantages.
2008	Leyendecker	MR urography: techniques and clinical applications	<i>Radio Graphics</i>	Static-fluid and excretory MR urography can be combined with conventional MR imaging to provide a comprehensive evaluation of the kidneys, ureters, bladder, vasculature, and soft tissues in patients with symptoms referable to the urinary tract.
2007	Pais	Urolithiasis in pregnancy	<i>Urologic Clinics of North America</i>	MRI provides detailed, cross-sectional images without exposure to ionizing radiation, to investigate ureteral obstruction in pregnant women. Typically, hydronephrosis of pregnancy is seen as hydroureter to the level of the pelvic brim, probably by compressing the ureter between the pelvic brim and the uterus, which is readily demonstrated with this method.
2007	Nikken	MRI of the kidney—state of the art	<i>Eur Radiol</i>	MRI and CT show comparable accuracy in detection and characterization of most renal lesions. MRI can have additional diagnostic value in the evaluation of lesions with minimal amounts of fat or with intracellular fat. Data suggest that MRI has a higher sensitivity in evaluating complicated cysts, however, the clinical implications still have to be studied.
2004	Riccabona	Potential impact of pediatric MR urography on the imaging algorithm in patients with a functional single kidney	<i>AJR</i>	MR urography allows a reliable assessment of renal and ureteral anatomy and of dysplastic or ectopic renal buds, even in non- or poorly functioning systems.
2003	Kawashima	CT urography and MR urography	<i>Radiologic Clinics of North America</i>	MR urography currently serves as an alternative imaging technique to intravenous urography and CT urography for children and pregnant women and for patients with contraindications to iodinated contrast media.
1996	Aerts	Breath-hold MR urography using the HASTE technique	<i>AJR</i>	Image quality was excellent in all cases: no motion-related artifacts were seen, and superimposition of fluid-filled bowel loops was not a significant problem.

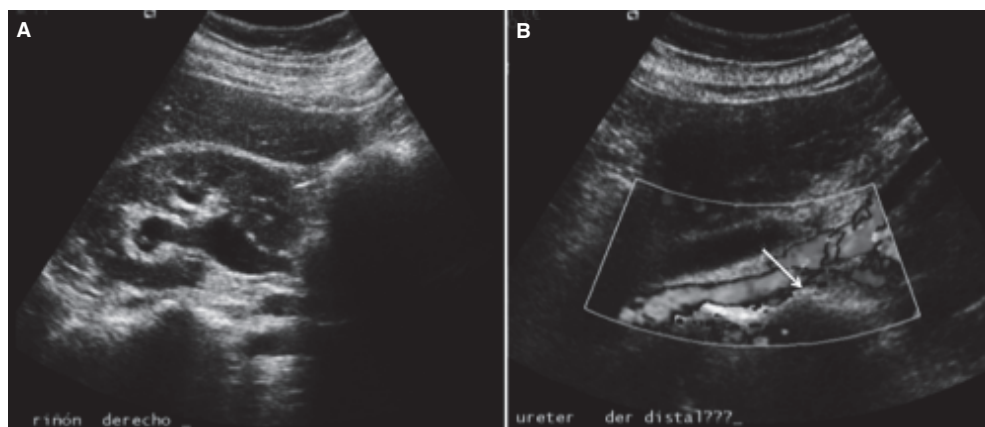


Figure 1. Abdominal ultrasound dedicated to kidneys shows: **A.** Pyelocaliceal dilatation in an oblique plane through right kidney. **B.** Tubular structure along the way of the right ureter without flux demonstration with Doppler modality, which probably represents dilation of right ureter.

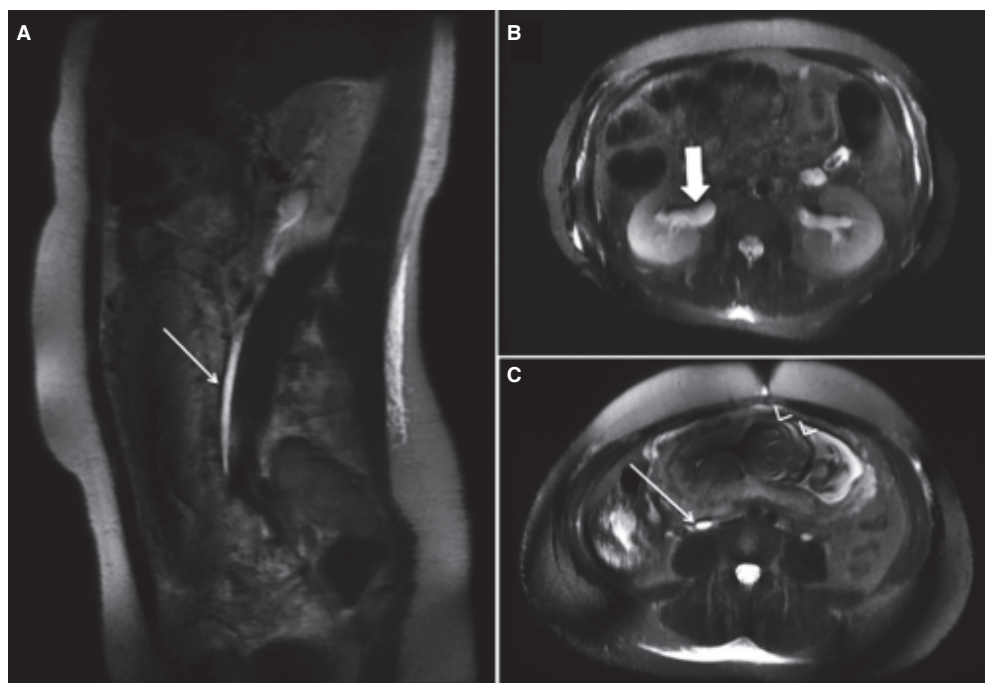


Figure 2. **A.** Sagittal MR image on FSE T2 weighted sequence demonstrate tapering of the distal right ureter due to pregnant uterus extrinsic compression without intraluminal hypointense images that suggest lithiasis. **B.** FSE T2 weighted axial image shows bilateral ureter dilatation in the right about 13 mm and in the left 8 mm in diameter, note is made of the voluminous uterus and the fetal head within at the pelvic cavity. **C.** Bilateral pyelocaliceal dilatation is also shown.

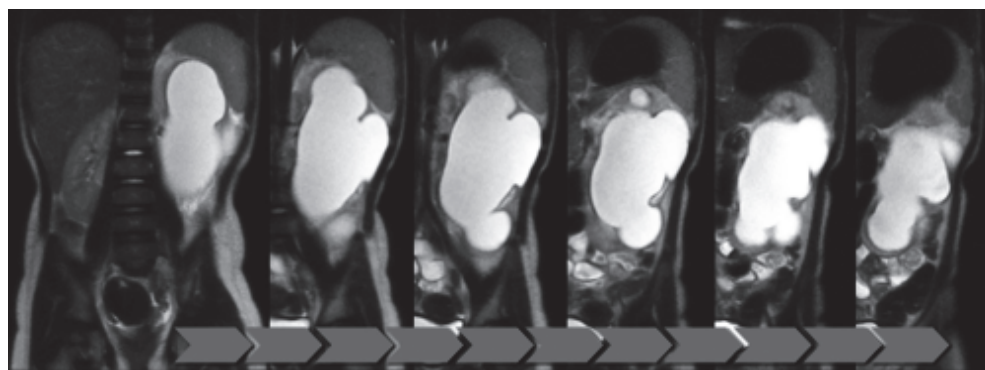


Figure 3. Sequential coronal-plane FSE T2-images showing a case with severe pyelocaliceal dilatation.

Table 2. Advantages and some limitations of MR urography.

Advantages	Disadvantages
No iodinating radiation is used (useful for pediatric patients, pregnant women, and patients who require frequent imaging of urinary tract).	Cost (when used with gadolinium and arteries evaluation).
Does not depend on renal function.	
Multiplanar capability.	Limited retrospective reconstruction capability.
Best method to evaluate chronic urolithiasis changes and exact situation of stone for evaluating their removal.	Limited for detection of small size urolithiasis.
High contrast resolution.	
Provides functional information.	

pregnant women, children, and patients who need repeated examinations of the urinary tract.^{2,3} In addition, because the number of acquisitions is not limited by factors other than the examination time, repeated acquisitions can be used to generate time intensity curves in order to assess renal function.

MR is relatively insensitive for the detection of calcification, though the diagnosis of ureteral calculi often is made detecting secondary sign of obstruction such as ureteral dilatation and perinephric fluid; sometimes a persistent filling defect can be identified.³ Nonetheless, sensitivities reach 90% for the diagnosis of ureteral calculi with excretory MR urography, they depend on the technique, due to higher sensitivities have been reported for excretory MR urography than for static-fluid T2-weighted techniques.^{4,5}

MR urography is an attractive alternative to CT urography because ionizing radiation is not used, however the sensitivity for detecting small urothelial carcinoma (due to the inferior spatial resolution relative to CT) is probably lower of MR urography³ (Table 2).

Clinical applications

- **Urolithiasis.** Calculi are encountered not only with unenhanced multidetector CT but also with MR urography. Most urinary tract calculi appear as signal voids with T1- and T2-weighted sequences. At static-fluid and excretory MR urography, calculi appear as filling defects when surrounded by urine or contrast material. They are better visualized in axial images, instead of MIP images, the source images must always be reviewed because small defects may be obscured by the surrounding urine on MIP projections.^{6,7}

However, low-signal-intensity filling defects within the urinary tract are not specific for calculi. Blood clots are seen as single or multiple filling defects that may cause temporary ureteral obstruction, but can be distinguished since they typically exhibit high-signal-intensity elements on unenhanced T1-weighted images and become much smaller or disappear within several weeks.⁸ Neoplasm can also show filling defects but can be distinguished since typically enhance after intravenous contrast material administration.² Some authors such as Karabacakoglu *et al.* reported a better sensitivity founding collecting system calculi with diuretic-augmented excretory MR urography.⁴ In a study by Jung *et al.*, diuretic-augmented excretory MR urography helped make the correct diagnosis in 64 of 72 patients with ureteric calculi, compared with 49 of 72 patients for conventional intravenous urography.⁹

Some additional findings of acute stone colic include increased perinephric fluid on T2-weighted images and ureteral dilatation proximal to the stone.⁵

Apart from its limited value in acute urolithiasis, MR urography may play a potential role in patients with chronic urolithiasis, in whom neither ultrasonography nor CT can sufficiently explain, the complicated state of the chronically affected urinary tract. The MR urography not only helps to avoid radiation exposure due to repeated CT examinations. Especially in chronic nephrolithiasis resistant to treatment, MR urography can be used to obtain valuable information about the true location of calculi and the anatomy of the stone-bearing calix. Those data are clinically relevant to determine whether a stone has a potential chance to pass the infundibulum and renal pelvis after lithotripsy or during endo-urolologic stone removal.¹⁰

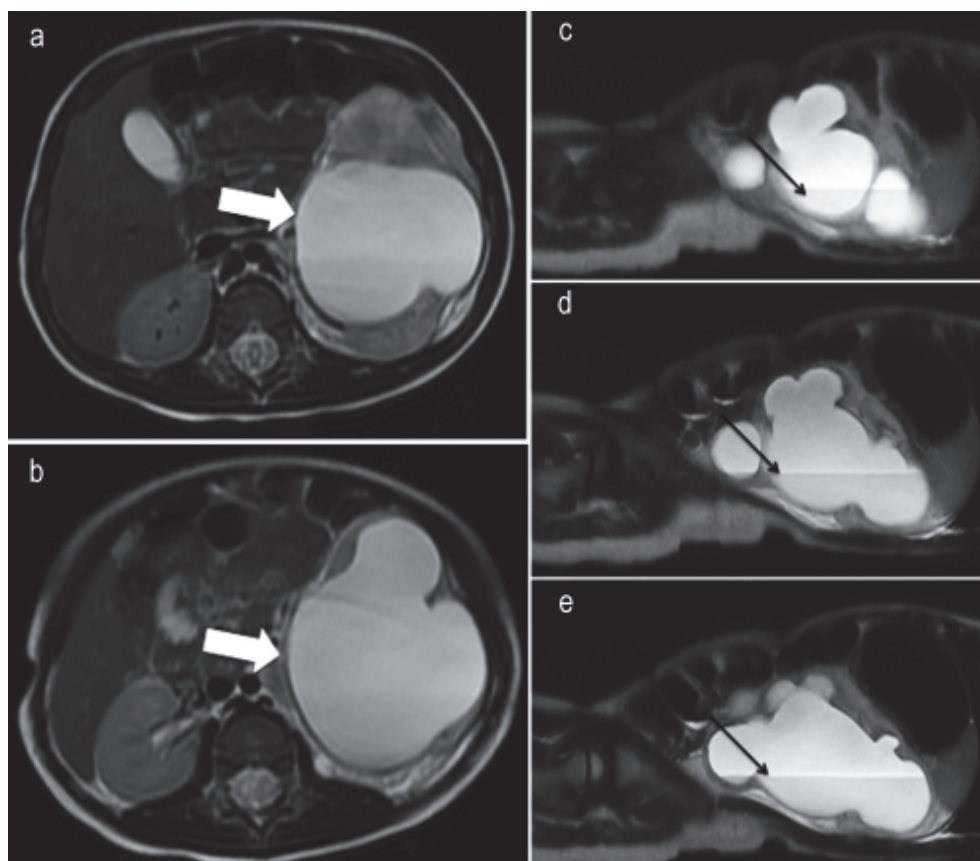


Figure 4. FSE T2 axial (A-B) and sagittal (C-E) consecutive images of a 3-year-old patient with history of urinary infections showing prominent pyelocaliceal dilatation on the left side, that increases kidney volume and thinning of the renal parenchyma, the ureters are not visible at the pielo-ureteral to the ureteral-bladder junction.

- **Urinary tract obstruction unrelated to urolithiasis.** The differential diagnosis of ureteral obstruction include intraluminal (besides calculi, blood clots, papillary necrosis), intramural (tumor, infection diseases, post-surgery/instrumentation trauma, lesions after radiotherapy, ureterocele, megaureter) and extrinsic abnormalities (retroperitoneal fibrosis, invasion or compression by extrinsic malignancy, lymphadenopathy, inflammatory diseases).⁶ Especially in the patients with extrinsic obstruction the combination of MR urography and conventional axial MR pulse sequences offers a "one-stop" method.¹⁰
- **Hematuria.** The evaluation of hematuria requires the use of additional sequences of MR urography, they allow the detection of renal parenchymal and vascular lesions as well as urothelial abnormalities. MR imaging is excellent for the detection, characterization, and staging of renal neoplasm.¹¹ In most solid renal lesions, neither CT nor MRI are able to reliably distinguish benign from malignant. Some solid lesions, however,

may be identified as benign with high confidence, like angiomyolipomas. Though in general, if a lesion cannot be characterized as benign or malignant it should be considered malignant.^{12,13}

In patients suspected of having a transitional cell carcinoma, there is a good opportunity to combine MR urography with standard MR imaging in the axial plane. On unenhanced T1-weighted MR images of standard spin-echo sequences, transitional cell carcinomas are mainly isointense to the normal renal parenchyma, whereas they display a more heterogeneous signal morphology including hyperintense and cystic-like areas on T2-weighted. We also expect a moderate gadolinium enhancement of such tumors on axial T1-weighted spin-echo images. Conventional pulse sequences may also prove useful for the assessment of a parenchymal tumor infiltration or, vice versa, for the differentiation of an intrinsic tumor from a renal cell carcinoma with secondary invasion of the collecting system.¹⁰

- **Pre and post operative assessment.** The role of MRU in patients undergoing urinary diversion or after renal transplantation is emerging. MRU allows visualization of anastomoses, as well as of associated complications such as strictures, ureteral compression by lymphocele or haematoma, urine leaks, fistulae, stones as signs of infection.⁶

Table 3. Clinical applications of MR urography.

Special considerations	Without Gadolinium	With Gadolinium
Pediatric patients	Detection of virtually all types of urinary tract anomalies such as: ureteroceles, bladder diverticula, markedly obstructed duplex systems, megaureters, stenosis of the ureteropelvic junction, cystic kidney diseases.	Small anatomic variations such as pelvicaliceal diverticula
Obstetric	Lithiasis and hydronephrosis.	
Transplanted kidneys	Urinary leaks and fistulas.	
Urology	Assessment of urinary tract after orthotopic neobladder reconstruction. Urolithiasis with dilated and non-dilated urinary tract specially chronic.	
Oncology	Intrinsic tumors located in the pelvicaliceal system or ureter.	

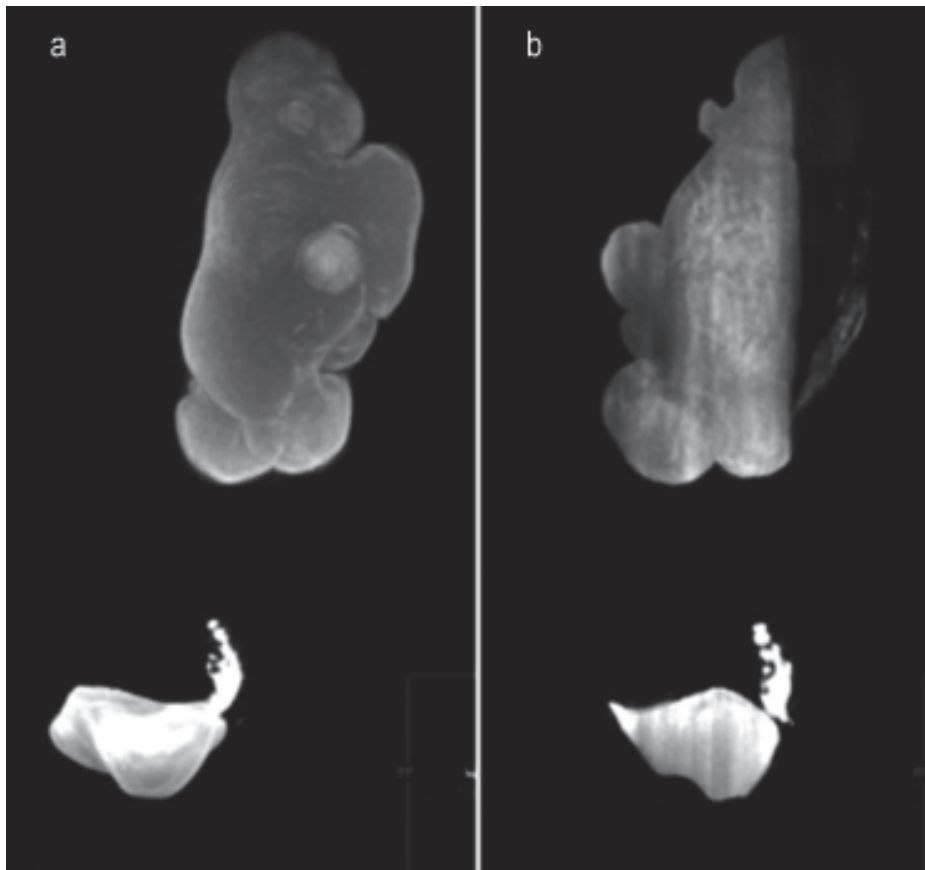


Figure 5. Same patient as figure 3, maximum intensity projection images (A-B) from an MR urogram obtained with a coronal 2D FIESTA (fat suppressed) sequence, note the important dilatation of left collecting system, and absence of almost the total left ureter, with just a remnant of the distal ureter which showing focal constrictions and dilatations.

Some special considerations in the clinical application of MR urography are presented in table 3.

CONCLUSION

Static and excretory MRU are complementary methods for morphological and functional evaluation of the urinary system, which can be alternatively employed according to the degree of urinary tract dilatation and renal function. These methods have some advantages over ultrasound, conventional urography and CT urography in the diagnosis of urological diseases. The three-dimensional nature of the data permits to reform images into any plane and better allows the diagnosis of different pathological conditions. There is also the advantage of eliminating ionizing radiation. MRU is accepted nowadays as the most important tool in the diagnostic of genitourinary pathologies in infants, small children and in pregnant women.

The principal disadvantage is its low sensitivity in detecting calcifications and subtle urothelial lesions, due to the reduced spatial resolution; however dedicated protocols with longer acquisition times can overcome these situations. MRU can be offered as an alternative to conventional urography and CT urography to avoid repetitive radiation exposure in patients with chronic urolithiasis.

The use of combined techniques, including conventional MRI (static images), functional MR sequences (contrast-enhanced excretory MRU) and MR angiography provide a high-quality comprehensive evaluation of the entire urinary tract, given evidence for an accurate and non-invasive diagnostic. Cost adjustments are still pending to make this tool and attractive option for clinicians allowing them to choose it as a surrogate of other imaging options.

REFERENCES

1. Friedburg HG HJ, Frankenschmidt A. RARE-MR urographie: ein schnelles nicht-tomographisches aufnahmeverfahren zur darstellung der ableitenden darnwege mittels magnetischer kernresonanz. *Radiologe* 1987; 27: 45-7.
2. Leyendecker JR, Barnes CE, Zagoria RJ. MR urography: techniques and clinical applications. *Radiographics: a review publication of the Radiological Society of North America, Inc.* 2008; 28: 23-46, discussion-7.
3. Silverman SG, Leyendecker JR, Amis ES Jr. What is the current role of CT urography and MR urography in the evaluation of the urinary tract? *Radiology* 2009; 250: 309-23.
4. Karabacakoglu A, Karakose S, Ince O, Cobankara OE, Karalezli G. Diagnostic value of diuretic-enhanced excretory MR urography in patients with obstructive uropathy. *European J Radiology* 2004; 52: 320-7.
5. Regan F, Bohlman ME, Khazan R, Rodriguez R, Schultze-Haakh H. MR urography using HASTE imaging in the assessment of ureteric obstruction. *AJR American J Roentgenology* 1996; 167: 1115-20.
6. Garcia-Valtuille R, Garcia-Valtuille AI, Abascal F, Cerezal L, Arguello MC. Magnetic resonance urography: a pictorial overview. *The British J Radiology* 2006; 79: 614-26.
7. Nolte-Ernsting CC, Bucker A, Adam GB, et al. Gadolinium-enhanced excretory MR urography after low-dose diuretic injection: comparison with conventional excretory urography. *Radiology* 1998; 209: 147-57.
8. Blandino A, Gaeta M, Minutoli F, et al. MR urography of the ureter. *AJR American J Roentgenology* 2002; 179: 1307-14.
9. Shokeir AA, El-Diasty T, Eassa W, et al. Diagnosis of ureteral obstruction in patients with compromised renal function: the role of noninvasive imaging modalities. *J Urology* 2004; 171: 2303-6.
10. Nolte-Ernsting CC, Adam GB, Gunther RW. MR urography: examination techniques and clinical applications. *European Radiology* 2001; 11: 355-72.
11. Yoshimitsu K, Irie H, Tajima T, et al. MR imaging of renal cell carcinoma: its role in determining cell type. *Radiation medicine* 2004; 22: 371-6.
12. Nikken JJ, Krestin GP. MRI of the kidney-state of the art. *European Radiology* 2007; 17: 2780-93.
13. El-Galley R. Surgical management of renal tumors. *Radiologic clinics of North America* 2003; 41: 1053-65, vii.